



RESEARCH ARTICLE

A STUDY ON HOSPITAL STAY AFTER LOOP ILEOSTOMY CLOSURE

***Dr. Deepak Kumar and Dr. D. K. Sinha**

Rajendra Institute of Medical Sciences, Ranchi, Jharkhand, India

ARTICLE INFO

Article History:

Received 15th October, 2016
Received in revised form
22nd November, 2016
Accepted 27th December, 2016
Published online 31st January, 2017

Key words:

Ileus,
Enterocutaneous fistula.

ABSTRACT

Recent studies have shown that closure of loop ileostomy can be performed in the day-care setting, reducing the length and cost of hospitalisation. By analysing our patients who have undergone closure, we aimed to determine the minimum duration of hospital stay and potential factors behind longer stays. A database of patients undergoing closure of loop ileostomy in our unit was examined. The time taken to discharge, morbidity, complications and re-admission rates were recorded. Fifty four patients underwent reversal of ileostomy between July 2015 and November 2016. Median age was 53 years (range, 22–81 years). The median length of stay was 5 days (range, 5–18 days). Many appeared able to be discharged earlier. Thirty six patients (66.6%) had bowel function within 2 days. Eleven patients (20%) developed complications, which included wound infection (10%), small bowel obstruction/ileus (4%), anastomotic leak (4%) & enterocutaneous fistula (2%). Of the patients, 50% stayed longer than 5 days despite having no postoperative complications. The majority of patients undergoing loop ileostomy reversal at our institution can be discharged earlier than they are at present. Support in the community and the implementation of modified UK day-case surgery protocols are suggested to help shorten patient's length of stay in hospital.

Copyright©2017, Deepak Kumar and Sinha. This is an open access article distributed under the Creative Commons Attribution License, which permits unrestricted use, distribution, and reproduction in any medium, provided the original work is properly cited.

Citation: Dr. Deepak Kumar and Dr. D. K. Sinha, 2017. "A study on hospital stay after loop Ileostomy closure", *International Journal of Current Research*, 9, (01), 44796-44799.

INTRODUCTION

Defunctioning loop ileostomy is an established method to divert bowel contents away from a distal anastomosis thereby attenuating the sequelae of anastomotic leakage and preventing fistula formation or use of inflamed bowel. Subsequent reversal of the ileostomy restores bowel continuity and improves the patient's overall quality of life. The advantage of a loop or divided loop ileostomy is that subsequent closure can often be accomplished without a formal laparotomy. An elliptical incision is created around the stoma and the bowel gently dissected free of the subcutaneous tissues and fascia. A hand-sewn or stapled anastomosis can then be created and the intestine returned to the peritoneal cavity. This avoids a long laparotomy incision and generally is well tolerated. The timing of ileostomy closure should take into account anastomotic healing as well as the patient's overall condition. A flexible endoscopy exam and a contrast enema (Gastrografin) are recommended prior to closure to ensure that the anastomosis has not leaked and is patent. A patient's nutritional status should be optimized. In cancer patients receiving adjuvant chemotherapy, ileostomy closure should be delayed until the chemotherapy is completed. [Schwartz 10th ed] It has been suggested that reversal of loop ileostomy can be performed as an ambulatory procedure with early discharge

protocols in order to facilitate the early discharge of patients. (Kalady *et al.*, 2003; Moran, 1997) This not only benefits the patient, but is also a cost-effective use of healthcare resources. We perceived that the duration of stay of patients undergoing this procedure in our facility was significantly longer than reported in the various studies. This delay possibly relates to the potential for complications or the tradition of patients remaining in hospital under observation until bowel function returns. In order to investigate this hypothesis of prolonged hospital stay and the potential reasons behind this delay, we analysed the time taken to discharge for all patients undergoing reversal of a loop ileostomy. Postoperative complications and the time taken for the patient to open their bowels were the secondary end-points.

PATIENTS AND METHODS

A database of all patients undergoing loop ileostomy reversal was examined and their case notes reviewed. The following data were analysed: ileostomy indication, type of anaesthetic used, grade of surgeon, time to oral fluids and feeding, time to bowel opening, length of hospital stay, and complications. Criteria for exclusion from the study were those patients who underwent reversal as part of a multiple procedure or with concurrent laparotomy, those with spinal injuries and those with renal failure undergoing haemodialysis. The potential for prolonged stay and complications in these groups was

perceived to be higher and the patients likely to not be reflective of the study group. All patients had a standard bowel closure technique after having continuity of bowel distal to the ileostomy confirmed radiologically or clinically. Prophylactic, broad-spectrum antibiotics were administered at the induction of anaesthesia. The enteric mucosal-cutaneous junction was taken down and the adhesions between the small bowel and the anterior abdominal wall were freed with sharp dissection. Continuity was then restored by interrupted absorbable monofilament suture. After return of the bowel into the abdominal cavity, the abdominal wall defect, the subcutaneous tissue and skin were closed. Nasogastric tubes were routinely passed.

RESULTS

A total of 54 patients underwent reversal of loop ileostomy between July 2015 and November 2016 in our unit. The indications for loop ileostomy formation are summarized in Figure 1. The procedure was performed under general anaesthetic in 51 patients (95%) and under spinal anaesthetic in three patients (5%).

Table 1. Recommendations for patient suitability for early discharge after closure of loop ileostomy

Pre-operative assessment	
- Social suitability: responsible adult present for 24 h, access to telephone, access to general practitioner	
- American Society of Anaesthesiologists physical status grade 1–2	
- Body mass index < 35 kg/m ²	
- No severe systemic organ system dysfunction	
- No type 1 diabetes or type 2 on insulin	
- Not on anticoagulation therapy	
- No anaesthesia contraindications	
Intra-operative factors	
- No excessive blood loss	
- No conversion to laparotomy or multiple procedures	
Fitness for discharge	
- Stable vital observations for at least an hour	
- Absence of active wound bleeding	
- No nasogastric tube	
- Pain controlled on oral analgesia	
- Passing urine	
- Able to drink fluids	
- Written and verbal instructions on wound care, analgesia and signs of sepsis and bowel obstruction	
- Emergency contact number for accident and emergency department and stoma clinical nurse specialists	
- Regular district nurse visits for wound management.	

Table 2. [Ann r coll surg engl 2010 jan 92(1)] Complications resulting from reversal of loop ileostomy

Complication	Number of patients (%)	Range (mean) of length of stay (days)
Wound infection	6(8)	6–27 (10.8)
Rectal bleeding	3(4)	N/A
Urinary retention	3(4)	3–11 (5.6)
Small bowel obstruction ^a	2(3)	7–10 (8.5)
Paralytic ileus	2(3)	7–11 (9)
Urinary tract infection	2(3)	5–6 (5.5)
Anastomotic leak ^b	1 (1)	15
Enterocutaneous fistula ^c	1 (1)	32
Lower respiratory tract infection	1 (1)	4
Abdominal wall abscess ^d	1 (1)	N/A

^aOne patient re-admitted 7 days' postoperatively. Both patients managed conservatively.

^bPossible leak 5 days' postoperatively. Managed conservatively.

^cOccurred fifth day postoperatively. Managed successfully with total parenteral nutrition and octreotide.

^dOccurred 4 months' postoperatively.

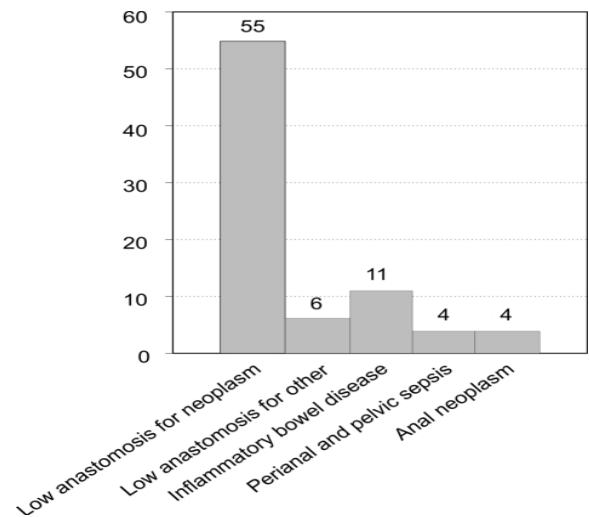


Fig. 1. Indications for defunctioning loop ileostomy. [Ann r coll surg engl 2010 jan 92(1)]

Time to discharge, oral intake and bowel opening

The median hospital stay was 5 days (range, 5–18 days). The median time to bowel opening was 2 days (range, 0–12 days). Forty eight patients (90%) tolerated oral fluids 48 h after their operation. The median length of stay for patients without complications was 4 days. Of the patients, 50% stayed longer than 5 days despite having no postoperative complications.

Complications

The overall complication rate was 20%. These complications are shown in Table 1. The most common complication was wound infection (7 patients). Two patients were re-admitted; both patients presented with the symptoms of small bowel obstruction and abdominal pain 7 days after discharge and 14 days after their procedure; both managed conservatively. One patient presented 3 months later with enterocutaneous fistula. All complications which occurred within the admission period were associated with a longer hospital stay.

DISCUSSION

Reversal of loop ileostomy has been shown to be possible as an ambulatory procedure and can also be performed under local anaesthetic. Our data confirm that there are wide variations in patient's lengths of stay that were perhaps not always justifiable. We propose that current practice can, therefore, be modified to enable early patient discharge in suitable patients without compromising their safety. Kalady *et al.* (2003) showed that discharge within 24 h is possible after general and/or regional anaesthesia in a cohort of 28 carefully selected patients. Day-case selection criteria were similar to those used in the UK (British Association of Day Surgery, 2008) and patients were discharged with a strict postoperative care regimen. There were three re-admission episodes in this group (10.7%). Haagmans and colleagues (Haagmans *et al.*, 2014) performed 15 closures under local anaesthetic with a median length of stay of 2 days. One patient suffered subsequent wound infection and another small bowel obstruction, which settled conservatively. Ihedioha *et al.* (2004) used a 'minimal general anaesthesia' technique to perform 70 ileostomy closures with a median length of stay of 2 days. There was a high re-admission rate (10%), however,

similar to the cohort of Kalady *et al.* These studies show that the early discharge of patients after ileostomy reversal is feasible. In our series, patients without complications stayed in hospital for a median of 4 days. This compares favourably with other studies performed in the UK, (Williams *et al.*, 2008; Amin *et al.*, 2001; Hasegawa *et al.*, 2000) although studies in the US show variable lengths of stay. (Kalady *et al.*, 2003; Wexner *et al.*, 1993; Hull *et al.*, 1996) In our cohort, 50% of patients had a hospital stay of 5 days or more despite having no complications suggesting that facilitating earlier discharge may reduce the length of stay further. The concepts of enhanced recovery and early discharge include the avoidance of nasogastric tubes (Haagmans *et al.*, 2004) and early feeding. There is also no apparent reason why patients must remain in hospital until their bowels open. The six patients in our cohort who were discharged prior to bowel opening suffered no complications and had a mean stay of 3.5 days, which compared favourably with the rest of the group. There is a possible mindset in that surgeons want a reasonable period of time to elapse for any potentially serious complication (such as an anastomotic leak) to make itself manifest before letting the patient home. Bowel function may add re-assurance that complications are less likely. Patients subjected to an early discharge programme should be carefully selected in accordance with modified day-case surgery guidelines (Table 2). They should also be counselled and given written instructions on wound care, analgesia requirements and on when to seek attention for impending ileus, obstruction or sepsis. (Kalady *et al.*, 2003; Moran, 1997) This may require pre-operative input by the surgeon or specialist nurse and ensuring the availability of postoperative support and access to emergency services after discharge. Wound infection was the most common complication, occurring in 10% of patients. All patients had primary closure of their wounds, as is the practice in our unit. Wound closure technique after closure of ileostomy is variable amongst surgeons. It has been suggested that leaving ileostomy wounds to repair by secondary intention reduces the infection rate, (Haagmans *et al.*, 2004) but this has implications on the postoperative management of any patients who are considered for early discharge. The cohort of Haagmans *et al.* (2004) had a wound infection rate of 1 in 15 (6.7%) and this single patient had had primary closure of their stoma wound. Kalady *et al.* (2003) used a loose purse-string closure and packing to manage the wound with removal of the ribbon gauze pack and instructions on wound care prior to discharge and had an infection rate of 3.7%. Other published studies suggest no consensus, however, on whether secondary healing does decrease wound infection rates. (Lahat *et al.*, 2005; Vermulst *et al.*, 2006)

Most major complications (leak, fistula, bowel obstruction) occurred within 5 days of surgery. The question remains as to whether the patient would have come to more harm if these complications occurred outside the hospital. Provided adequate community support is available with an easy access to specialist advice, this seems unlikely. The duration of stay of patients undergoing this procedure in our facility is significantly longer than that reported in various studies. This delay possibly relates to the potential for complications or the tradition of patients remaining in hospital under observation until bowel function returns. Duration of Hospital stay depends on various factors like ileostomy indication, bowel preparation before closure, type of anaesthetic used, grade of surgeon, time to oral fluids and feeding, time to bowel opening, and post operative complications.

Other conditions that may be treated with an ileostomy include:

- Bowel obstructions
- Cancer of the colon and/or rectum
- Crohn's disease (chronic inflammation of the intestines)
- Congenital bowel defects
- Uncontrolled bleeding from the large intestine
- Injury to the intestinal tract

Conclusion

This study confirms that postoperative stay after closure of loop ileostomy is extremely variable with many patients staying longer in hospital than appears clinically justified. Most complications would not have been avoided if the patient had been discharged earlier. Our data would suggest there is no reason to avoid earlier discharge after ileostomy reversal provided surgeons are prepared to modify current practice, perhaps accept an increased re-admission rate and provided there is adequate community support.

REFERENCES

- Amin SN, Memon MA, Armitage NC, Scholefield JH. 2001. Defunctioning loop ileostomy and stapled side-to-side closure has low morbidity. *Ann R Coll Surg Engl.*, 83:246–9. [PMC free article] [PubMed]
- Balfour LS, Boyle K, Finan P, Burke D, Sagar P. 2002. The outcome of loop ileostomy closure: a prospective study. *Br J Surg.*, 89(Suppl 1):11.
- British Association of Day Surgery. Guidelines about the discharge process and the assessment of fitness for discharge. < <http://www.daysurgeryuk.org/bads/joomla/> > [Accessed 2008]
- Gan TJ. 2005. Selective serotonin 5-HT₃ receptor antagonists for postoperative nausea and vomiting: are they all the same? *CNS Drugs*, 19:225–38. [PubMed]
- Haagmans MJ, Brinkert W, Bleichrodt RP, van Goor H, Bremers AJ. 2004. Short-term outcome of loop ileostomy closure under local anesthesia: Results of a feasibility study. *Dis Colon Rectum.*, 47:1930–3. [PubMed]
- Hasegawa H, Radley S, Morton DG, Keighley MR. 2000. Stapled versus sutured closure of loop ileostomy: a randomized controlled trial. *Ann Surg.*, 231:202–4. [PMC free article] [PubMed]
- Hull TL, Kobe I, Fazio VW. 1996. Comparison of handsewn with stapled loop ileostomy closures. *Dis Colon Rectum.*, 39:1086–9. [PubMed]
- Ihedioha SM, Kalmar K, Donnelly L, Macdonald A. 2004. Early discharge after closure of loop ileostomy – is it safe and achievable? *Colorectal Dis.*, 6(Suppl 1):37–85.
- Kalady MF, Fields RC, Klein S, Nielsen KC, Mantyh CR, Ludwig KA. 2003. Loop ileostomy closure at an ambulatory surgery facility: a safe and cost-effective alternative to routine hospitalization. *Dis Colon Rectum.*, 46:486–90. [PubMed]
- Lahat G, Tulchinsky H, Goldman G, Klauzner JM, Rabau M. 2005. Wound infection after ileostomy closure: a prospective randomized study comparing primary vs. delayed primary closure techniques. *Tech Coloproctol.*, 9:206–8. [PubMed]
- Moran MR. 1997. Same-day surgery ileostomy closure? *Am J Manag Care*, 3:1003–6. [PubMed]

- Vermulst N, Vermeulen J, Hazebroek EJ, Coene PP, van der Harst E. 2006. Primary closure of the skin after stoma closure. Management of wound infections is easy without (long-term) complications. *Dig Surg.*, 23:255–8. [PubMed]
- Wexner SD, Taranow DA, Johansen OB, Itzkowitz F, Daniel N, Nogueras JJ, *et al.* 1993. Loop ileostomy is a safe option for fecal diversion. *Dis Colon Rectum.*, 36:349–54. [PubMed]
- Williams LA, Sagar PM, Finan PJ, Burke D. 2008. The outcome of loop ileostomy closure: a prospective study. *Colorectal Dis.*, 10:460–4. [PubMed]
- Wind J, Polle SW, Fung Kon Jin PH, Dejong CH, von Meyenfeldt MF, *et al.* 2006. Systematic review of enhanced recovery programmes in colonic surgery. *Br J Surg.*, 93:800–9. [PubMed]
- Wong KS, Remzi FH, Gorgun E, Arrigain S, Church JM, *et al.* 2005. Loop ileostomy closure after restorative proctocolectomy: Outcome in 1,504 patients. *Dis Colon Rectum.*, 48:243–50. [PubMed]
