



ISSN: 0975-833X

CASE STUDY

MANAGEMENT OF SACROCCYGEAL PILONIDAL SINUS DISEASE BY LIMBERG FLAP : OUR EXPERIENCE

*Dr. Nishikant Gujar, Dr. Chetan Dhruv Dhandore, Dr. Shiraz Ahamed Sharief, Dr. Vijay, N.,
Dr. Mohd. Farhan Khan and Dr. Vivekanand Chiniwar

Department of General Surgery, Al-Ameen Medical College, Vijayapur-586108 (Karnataka), India

ARTICLE INFO

Article History:

Received 15th October, 2016
Received in revised form
10th November, 2016
Accepted 18th December, 2016
Published online 31st January, 2017

Key words:

Sacroccygeal pilonidal sinus,
Limberg flap.

ABSTRACT

Pilonidal sinus disease is a common condition seen in young adults affecting gluteal cleft and notoriously recurrent. This study was carried out in patients with pilonidal sinus to evaluate the advantages and result of rhomboid excision and Limberg flap.

Materials and Methods: This prospective study was carried out in department of surgery, Al-Ameen Medical college, Bijapur from 2010 to 2015. It includes 25 patients who were treated for pilonidal sinus disease by Limberg flap. The various demographic clinical and surgical data are studied and compared to other studies.

Results: In this study 25 patients of Sacroccygeal pilonidal disease underwent rhomboid excision and Limberg flap reconstruction. The duration of symptoms was 1 to 12 months operative time was 60 – 100 minutes and the post operative stay was 10 – 14 days. The complication observed was superficial skin necrosis in 8% wound infection in 8%, Seroma in 4% with no recurrence.

Conclusion: Limberg flap is technical easy and effective mode of management of pilonidal sinus with low complication rate.

Copyright©2017, Nishikant Gujar et al. This is an open access article distributed under the Creative Commons Attribution License, which permits unrestricted use, distribution, and reproduction in any medium, provided the original work is properly cited.

Citation: Dr. Nishikant Gujar, Dr. Chetan Dhruv Dhandore, Dr. Shiraz Ahamed Sharief et al. 2017. "Management of Sacroccygeal pilonidal sinus disease by Limberg flap : Our experience", *International Journal of Current Research*, 9, (01), 45493-45496.

INTRODUCTION

Sacroccygeal disease is a common and well recognized entity (Chintapatla, 2003). And it was first discovered by hedges in 1880 (Hodes, 1880). It occurs in the cleavage between the buttocks and can cause discomfort, embarrassment and absence from work for thousands of young people annually (David Miller, 2003). Apilonidal sinus consist of characteristic midline opening of series of openings in the natal cleft about 5 cm from the anus. The skin enters the sinus, giving the opening a smooth edge. This primary tract leads in to an subcutaneous cavity which contains granulation tissue and usually a nest of hairs, which may be seen projecting through the skin opening. Many patients have secondary lateral openings 2 to 5 cms above the midline pits. The skin opening and superficial portion of the track are lined with squamous celled epithelium, but the deep cavity and its extension are not (Jones, 1992). During the second world war the conditions was common in jeep drivers, which leads to it being known as jeep disease. A smiliar condition arises in the cleft between the fingers of barbers or hair dressers caused by customers hair entering moist, damaged skin (David Miller, 2003). The condition is more common in Caucasians than Asians or Africans due to

differing hair characteristic and growth pattern (Berry, 1992). The Estimated incidence is 26 per 1,00,000 people (Srikanth K, Aithal, 2013). The etiology of the pilonidal sinus is the matter of controversy. The condition was probably first described by Mayo in 1833, who suggested that it was due to congenital origin secondary to remnant of an epithelial lined tract from post coccygeal epidermal cell rest or vestigial scent cell. Now the view widely shifted toward acquired theory (Brearley, 1955). based on the observation that congenital tracts do not contain hair and are lined by cuboidal epithelium. A widely accepted view is that they are caused by local trauma, poor hygiene, excessive hairness and presence of deep natal cleft (Bascom, 1980). karydakis proposed 3 main factors causing the disease, namely high quantity of hairs, extreme force and vulnerability to infection (Karydakis, 1992). Men affected more than women probable due to their hirsute nature, rare before puberty and after the age of 40 yrs. Rarely may it present in the fourth decade (Sondenaa et al., 1995).

Presentation

A Pilonidal sinus may be asymptomatic for sometimes prior to presentation. A majority of patients only present with the onset of symptoms, usually pain and discharge. Occasionally a painless lump or swelling may be discovered by the patients while washing, or the characteristic midline pits may be found

*Corresponding author: Dr. Nishikant Gujar,
Department of General Surgery, Al-Ameen Medical College, Vijayapur-
586108 (Karnataka), India

during a routine physics examination. Symptomatic diseases usually present as an acute pilonidal abscess, a chronic pilonidal abscess or complex / recurrent pilonidal disease (Solla and Rothenberger, 1990). Malignant transformation is rare but cases of squamous cell carcinoma and verrucous carcinoma have been reported (Lineaweaver *et al.*, 1984; Trent and Kirsner, 2003). There has been debate regarding the best treatment for pilonidal disease for many years. An ideal operation should be simple, should not need prolonged hospital stay, should have low recurrence rate and should be associated with minimal pain, wound care and decreased the patient time of work (Solla and Rothenberger, 1990). The management of the sacrococcygeal pilonidal sinus varies from clipping of hairs with good hygiene of the area, wide excision of the area and, newer flap produces, but none is widely accepted (Chiedozi *et al.*, 2002). Excision and packing, excision and primary closure, marsupialization and the flap techniques are the surgical procedures that have been suggested for the treatment (Mohamed *et al.*, 2005). The treatment of pilonidal sinus is often unsatisfactory because of its high recurrence rate. The literature review suggested that it ranged from 20-40 % regardless of the technique (Berger and Frileux, 1995). Many reasons were attributed to recurrence, such as leaving behind some tracts, sutures in the mid line causing more trauma with repeated infection accumulation of perspiration and friction with tendency of the hair getting incorporated with the wound (Casetecker *et al.*, 2006). In 1946 Limberg first described a technique for closing a 60 degree rhombus shaped defect with a transposition flap. It meets the entire requirement for been the ideal procedure for sacrococcygeal pilonidal sinus. If performed according to appropriate surgical principles (Jethwani, 2013). This flap was easy to perform, with sutures away from the midline giving rise to a tensionless flap of unscarred skin in the midline, which helps in good hygiene maintenance, reducing sweating maceration, erosions and scar formation (Srikanth and Aithal, 2013). Literature study showed that limberg flap reconstruction following rhomboid excision of the sinus area was superior to primary closure (Akca and Colak, 2005) and the other flap procedure (Azab *et al.*, 1984) and safe and reliable method in sacrococcygeal pilonidal disease with low complication and recurrence rate (Srikanth and Aithal, 2013). This study was carried out to evaluate the advantage, results of rhomboid excision and limberg flap reconstruction in the management of pilonidal sinus disease.

MATERIALS AND METHODS

This prospective study was carried out in the department of surgery, al almeen medical college Bijapur from 2010 to 2015. It includes 25 patients who were treated for pilonidal sinus disease by limberg flap. An informed written consent obtained prior to the surgery.

Inclusion criteria

- Sacrococcygeal pilonidal disease
- Primary or recurrent disease
- Consent given

Exclusion criteria

- Unfit for surgery
- Unwilling
- Infection/abscess

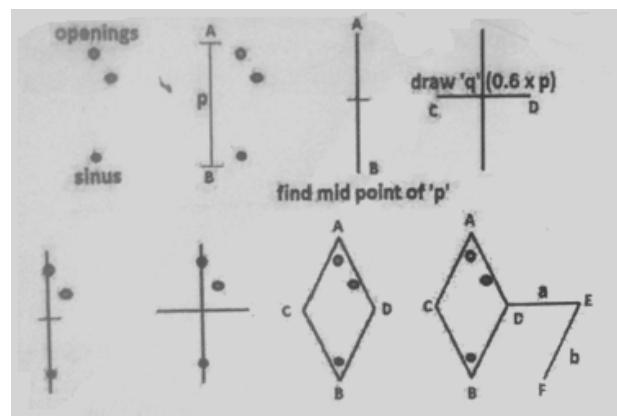


Fig. 1. General Schematic of creating a limberg flap

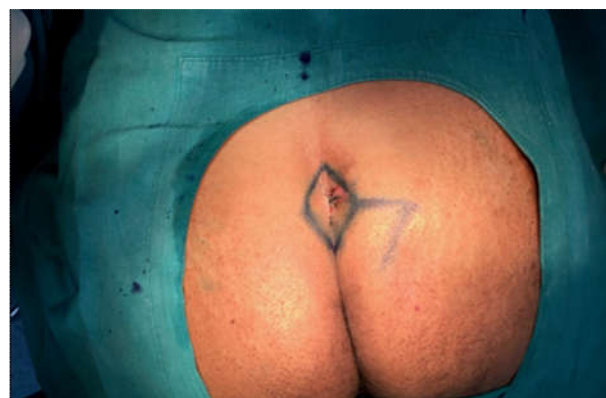

Fig. 2. Working of rhomboid incision and Limberg flap

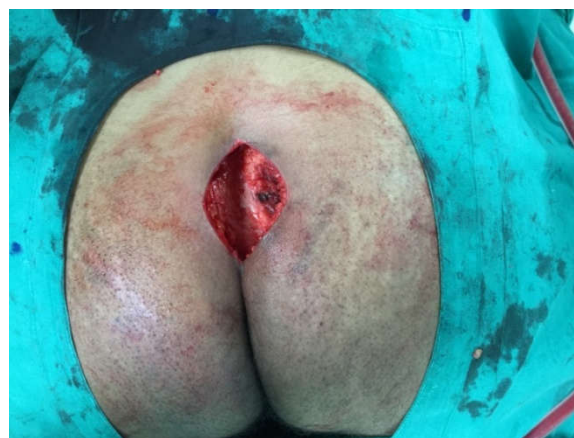

Fig. 3. Defect after rhomboid excision

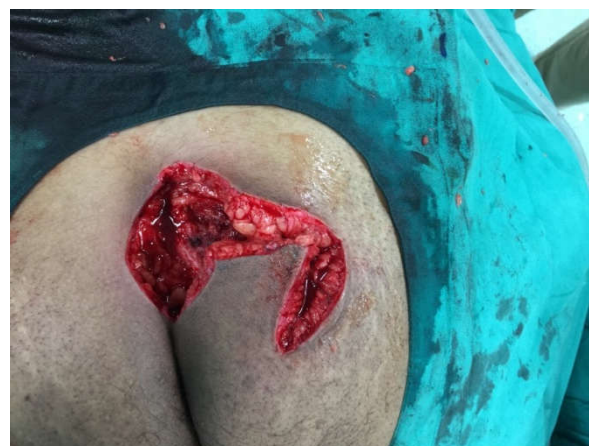

Fig. 4. Making Limberg flap

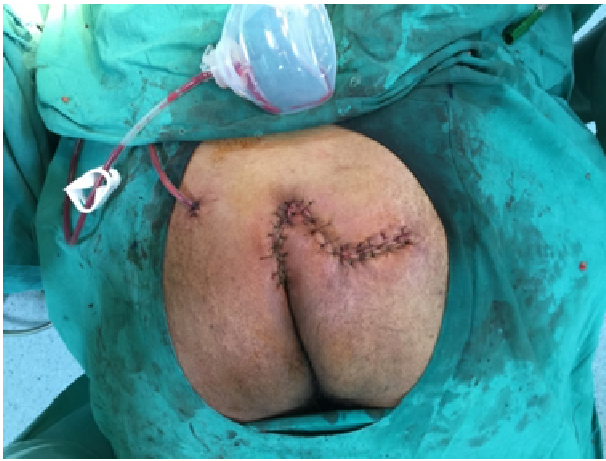

Fig. 5. Immediate Post operative photograph

Patients who had pilonidal abscess were first managed by incision and drainage they later went definitive surgery. Surgery was performed under spinal anesthesia. Patients were placed in prone jack-knife position with buttocks strapped for wide exposure. After painting and draping the area to be excised is marked and flap lines are marked in the following way. A vertical line AB was drawn just to the left of midline so as to incorporate the midline sinus and the distal most opening, the length p was noted, midpoint of this line was marked and a perpendicular line CD of length q was drawn at the midpoint so as to transect the previous line. Once all four corners were identified, a rhomboid AD BC was drawn. The horizontal diagonal CD was extended till E, where DE equals AC. The line EF was drawn parallel to DB with length equaling AD. Fig 1. Once the flap was drawn Fig. 2. the rhomboid incisions were taken and deepened till the presacral fascia, so as to remove the sinus and all the lateral openings Fig. 3. The flap is constructed by extending the incision laterally down to the fascia of the gluteus maximus muscle so as to be able to rotate without tension Fig. 4. Haemostasis is achieved by the use of electrocautery. The flap is transposed to the rhomboid defect created by the excision of sinus. A suction drain was placed before closure. Subcutaneous tissue is approximated with the interrupted polyglactin 2-0 suture. The skin is closed with Ethilon 3-0 suture Fig 5. Drain is removed after 48-72 hrs. alternate sutures are removed postoperative day 12th-14th. Postoperatively patients are advised to avoid prolonged sitting or exercise for two weeks. Hair removal either by shaving or hair removal cream is advised for atleast 1 month. Patients are followed up in opd monthly for 6 months.

RESULTS

25 patients were operated by rhomboid excision and Limberg flap reconstruction. Among them 21 were males (84%) and 4 were females (16%).

Table 1. Age Distribution

Age	%
0-10	0%
10-20	10 (40%)
20-30	12(48%)
30-40	3(12%)

In our study of 25 cases of pilonidal sinus disease we have 10 (40%) patient in 2nd decade, 12(48%) patients in 3rd decade,

3(12%) patients were in 4th decade. So in our study, 2nd and 3rd decade are more commonly affecting (Table 1). In our study 18 (72%) had single midline sinus and 7 (28%) had multiple sinus. In our study co morbidities associated with pilonidal disease were hirsute nature 40% of cases, obesity 12% of the cases and smoking 20% of the cases. In our study duration of symptoms varies between 1-12 months, in that 5 (20%) patients having itching, 6 (24%) patients having pain and 12 (48%) patients having discharge (Table 2).

Table 2. General, demographic and clinical data

Variables	Value
Age	25
Gender	
Male	21(84%)
Female	4(16%)
Number of sinuses	
Single midline	18(72%)
Multiple midline	7(28%)
Co morbidities	
Hirsute nature	10(40%)
Obesity	3(12%)
Smoking	5(20%)
Symptoms	
Itching	5(20%)
Pain	6(24%)
Discharge	12(48%)
Duration of symptoms	1-12 months

Table 3. Early postoperative data

Operative time	60-100 minutes
Hospital stay	10-14 days
Drain removal	48-72 hrs

In our study, operative time is 60-100 minutes, hospital stay 10-14 days and drain removal 48-72 hrs (Table 3).

Table 4. Complications

Hematoma	0
Superficial skin necrosis	2 (8%)
Wound gaping	0
Wound infection	2(8%)
Seroma	1(4%)
Flap necrosis	0
Recurrence	0

In our study 8% patients have superficial skin necrosis, 8% have wound infection, 4% have seroma and none of the patient had recurrence (Table 4).

Table 5. Comparison of results with other studies

Author/s	Patients (no)	Hospital stay (days)	Complication (%)	Recurrence
Katsoulis <i>et al.</i> (2006)	25	4.0	16	
Akin <i>et al.</i> (2008)	411	3.2	15.75	2.91
Urhan <i>et al.</i> (2002)	102	3.7	7	4.9
Mentes <i>et al.</i> (2004)	238	2-3	2	1.26
Aslam <i>et al.</i> (2009)	110	3.0	5	1
El-khadrawy (2006)	40	5-11	40	10
Mulla <i>et al.</i> (2017)	17	3-10	35.29	0
Jethwani <i>et al.</i> (2013)	67	2-3	11.94	1.49
Current study	25	10-14	20	0

DISCUSSION

In our study of 25 cases of pilonidal sinus disease we have 10 (40%) patient in 2nd decade, 12(48%) patients in 3rd decade,

3(12%) patients were in 4th decade. So in our study, 2nd and 3rd decade are more commonly affecting. Pilonidal disease is a chronic bothersome disease that frequently affect males in their 2nd or 3rd decade Mulla *et al.* (2017). It not only a cosmetic problem but can also lead to loss in work hours because of its recurrence rate Mulla *et al.* (2017). A long list of surgeries have been described which itself reflects the need for a safe and efficient surgical method for this entity. Recurrence is the main problem associated with all surgeries described which ranged from Mulla *et al.* (2017). 4% to 100% for incision and drainage, 5.5%-33% for excision and open packing, 8% for marsupialisation, 3.3%-11% for z plasty. Flap techniques have been associated with lower complication and recurrence rate. With the Limberg flap technique, internal flap cleft can be flattened and tissue can be approximated without tension. In our study most of the patients affected were male that is 21 case (84%) and 4 case (16%) were female. Similar results were observed in other studies Mulla *et al.* (2017). In our study 72% had single midline sinus and 28% had multiple sinus. Our results are comparable with Mulla *et al.* (2017). In our study co morbidities associated with pilonidal disease were hirsute nature 40% of cases, obesity 12% of the cases and smoking 20% of the cases. While Mulla *et al.* study shown Hirsute nature 47.05% of cases, obesity 5.8% of cases and smoking 29.4% of cases Mulla *et al.* (2017). In our study duration of symptoms varies between 1-12 months, in that 20% of patients having itching, 24% of patients having pain and 48% of patients having discharge. While Jethwani *et al.* shows 64% having discharge, pain in 23.88% of patients, infection in 5.97% of patients and pilonidal abscess in 5.97% of patients 18. In our study, operative time is 60-100 minutes, hospital stay 10-14 days and drain removal 48-72 hrs. In our study 8% patients have superficial skin necrosis, 8% have wound infection, 4% have seroma and none of the patient had recurrence. While the Jethwani *et al.* shows 4.47% of patients having seroma, 2.98% of patients having infection, 1.49% of patients having necrosis at tip of the flap, 1.49% of patients having gaping and 1.49% of patient having recurrence (Jethwani, 2013). Several studies have been reported till date and our results are also comparable with them in terms of hospital stay, complication and recurrence rate (Table 5).

Conclusion

The Limberg flap is technically easy to perform and very effective in management of sacrococcygeal pilonidal sinus with low complication rate. But our sample size is less it require further study with large sample size.

REFERENCES

- Akca T. and Colak T. 2005. Primary closure with Limberg flap in treatment of pilonidal sinus randomized clinical trial. *BJS*, 5074 : 1081-1084
- Akin M, Gokbayir H, Kilic K, Topgul K, Ozdemir E, Ferahkose Z. 2008. Rhomboid excision and Limberg flap for managing pilonidal sinus: long term results in 411 patients. *Colorectal Dis.*, Nov ; 10 (9) : 945-8.
- Aslam MN, Shoaib S, Choudhry AM. 2009. Use of Limberg flap for pilonidal sinus a viable option. *J Ayub Med Coll Abbottabad.*, Oct – Dec ; 21 (4) : 31-3
- Azab AS, Kamal MS. Saad RA, About AL, Atta KA, Ali NA. 1984. Radical cure of pilonidal sinus by a transposition rhomboid flap. *BJS*, 71 (2) : 154-155.
- Bascom, J. 1980. Pilonidal disease : Origin from follicles of hairs and results of follicle removal as treatment Surgery 87 : 567-572.
- Berger A. and Frileux P 1995. Pilonidal sinus. *Ann Chir.*, 49 : 889-901.
- Berry DP. 1992. Pilonidal sinus disease. *J Wound Care*, 1 (3) : 29-32.
- Brearily R. 1955. Pilonidal sinus : A new theory of origin. *Br J Sug.*, 43 : 62-68.
- Casetecker J, Mann BD, Castellanes AF, Strauss J. 2006. Pilonidal disease. Accessed 11 Dec 2011.
- Chiedozi LC, AlRayyes FA, Salem MM, Al Haddi FH, Al-Bidwei AA 2002. Management of pilonidal sinus. *Saudi Med J.*, 23 : 786-788.
- Chintapatla. S. 2003. Sacrococcygeal pilonidal sinus: historical review, pathological insight and surgical option, *Tech Coloproctol.*, 7 : 3 – 8.
- David Miller. Keith Harding, Worldwide wounds. Dec 2003.
- El-Khadrawy OH. 2006. The rhomboid flap for recurrent pilonidal disease. *Tanta Med Sci J.*, Oct; 1 (4) : 175-81.
- Hodes RM. 1880. Pilonidal sinus. *Boston Med Surg J.*, 103 : 485-586.
- Jethwani, U. 2013. Limberg flap for pilonidal sinus disease : our experience. *OA Case Reports*, Aug 08 ; 2 (7) : 69.
- Jones, D. J. 1992. Pilonidal sinus, ABC of Colorectal disease, *BMJ Vol*, 305.
- Karydakos GE. 1992. Easy and successful treatment of pilonidal sinus after explanation of its causative process. *Aust NZJ Surg.*, 62 : 385-389
- Katsoulis IE, Hibberts F, Carpeti EA. 2006. Outcome of treatment of primary and recurrent pilonidal sinuses with the Limberg flap. *Surgeon*, Feb; 4 (1) : 7-10. 62.
- Lineaweaver WC, Brunson MB, Smith JF, Franzini DA, Rumley TO. 1984. Squamous carcinoma arising in a pilonidal sinus. *J Surg Oncol.*, 27 (4) : 39-42.
- Mentes BB, Leventoglu S, Cihan A, Tatlicioglu E, Akin M, Oguz M. 2004. Modified Limberg transposition flap for sacrococcygeal pilonidal sinus. *Surg Today*, May ; 34 (5) : 419-23.
- Mohamed HA, Kadry I. Adly S. 2005. Comparison between three modalities for non-complicated pilonidal sinus disease. *Sureon* 3 (2) : 73-77.
- Mulla SA *et al.* 2017. Limberg flap for pilonidal sinus: an institutional study. *International Surgery Journal*, Feb 4 (2).
- Solla JA. and Rothenberger DA. 1990. Chronic Pilonidal disease. An assessment of 150 cases. *Dis Col Rec.*, 33 (9) : 758-61.
- Sondenaa K, Nesvik I, Anderson E, Natas O, Soreide JA. 1995. Patient characteristics and symptoms in chronic pilonidal sinus disease. *Int J Colorectal Dis.*, 10 (1):39-42.
- Srikanth K, Aithal, 2013. Limberg flap for sacrococcygeal pilonidal sinus a safe and sound procedure, *Indian J Surg.*, 75 (4) : 298-301.
- Trent JT. and Kirsner RS. 2003. Wounds and malignancy. *Adv Skin wound care*, 16 (1) : 31-34.
- Urhan MK, Kucukel F. Topgul K, Ozer I, Sari S. 2002. Rhomboid excision and Limberg flap for managing pilonidal sinus : Results for 102 cases. *Dis Colon Rectum.*, May ; 45 (5) : 656-9