



CASE STUDY

EDENTULOUS RIDGE DEFECT AUGMENTATION WITH HYDROXYAPETITE CRYSTALS ADMIXED PLATELET RICH FIBRIN USED AS A BARRIER MEMBRANE- A CASE REPORT

¹Dr. M. K. Gupta, ²Dr. Jaykumar Gade, *,¹Dr. Monica Mahajan and ²Dr. Neha Khodaskar

¹Department of Oral & Maxillofacial Surgery, Swargiya Dadasaheb Kalmegh Smruti Dental College & Hospital, Nagpur

²Department of Prosthodontics, Swargiya Dadasaheb Kalmegh Smruti Dental College & Hospital, Nagpur

ARTICLE INFO

Article History:

Received 28th October, 2016

Received in revised form

08th November, 2016

Accepted 20th December, 2016

Published online 31st January, 2017

Key words:

Alveolar ridge defect, Hydroxyapatite crystals, PRF membrane.

ABSTRACT

Replacement of mandibular teeth in an edentulous mandible with resorbed ridges and localized alveolar ridge defect is a challenge for the Oral surgeon as well as the Prosthodontist. Various soft and hard tissue procedures have been proposed to correct alveolar ridge deformities. Many new techniques have evolved in treating these ridge defects to improve function and esthetics. The present case reports a novel technique of alveolar ridge onlay grafting using hydroxyapatite crystals admixed with Platelet Rich Fibrin used as a barrier membrane. This technique resulted in a good reconstruction of the ridge defects with encouraging results prompting the efficacy of Platelet Rich Fibrin (PRF) membrane as a barrier material in various hard and soft tissue surgeries.

Copyright©2017, Gupta et al. This is an open access article distributed under the Creative Commons Attribution License, which permits unrestricted use, distribution, and reproduction in any medium, provided the original work is properly cited.

Citation: Dr. M. K. Gupta, Dr. Jaykumar Gade, Dr. Monica Mahajan and Dr. Neha Khodaskar, 2017. "Edentulous ridge defect augmentation with Hydroxyapatite crystals admixed platelet rich fibrin used as a barrier membrane- A case report", *International Journal of Current Research*, 9, (01), 45858-45861.

INTRODUCTION

The main goal of a surgeon while performing a preprosthetic surgery is to provide the best ridge form for construction of a denture that will be stable and retentive. Thus, a more efficient oral rehabilitation will be provided to the patient because lateral and vertical displacement of the prosthesis will be prevented (Mercier, 1985). Residual ridge resorption (RRR) is a term that is used to describe the changes which affect the alveolar ridge following tooth extractions, and which continue even after healing of the extraction socket. Bone resorption activity continues throughout life at a slower rate, resulting in loss of varying amount of jaw structure (Caplains, 2009). This condition can be localized or generalized. A localized residual alveolar ridge defect is characterized by deficiency of volume of bone and mucosal tissue (Reddy et al., 2015). It was stated by Cawood in 1991 that in cases of alveolar ridge resorption and defects, there is a quantitative and qualitative reduction of the soft tissue support as well (Caplains et al., 2009). Various soft and hard tissue procedures were proposed to correct alveolar deformities. Soft tissue corrective procedures included various free and pedicled mucosal and submucosal grafts

(Reddy et al., 2015). Whereas, the hard tissue reconstruction involved Autografts, Allografts, Xenografts and Alloplasts (Reddy et al., 2015; Cawood, 1991; Tal et al., 2012; Mercier et al., 1979). Commonly used Alloplasts for augmentation includes the Hydroxyapatite. It is the natural mineral component of bone, and comprises 60-70% of the calcified skeleton. Synthetic forms are also extremely biocompatible (Frame et al., 1987). To enhance bone regeneration, growth factors such as bone morphogenic proteins (BMPs) and platelet derived growth factors (PDGF) in combination with different kinds of bone substitutes were examined. Platelet rich plasma (PRP) contains many growth factors including platelet derived growth factors (PDGF), vascular endothelial growth factors (VEGF), and transforming growth factors (TGF-b). There are several studies that used PDGF in combination with autogenous bone grafts or synthetic bone materials to enhance bone regeneration (Mercier and Lafontant, 1979). In this article we report a case of edentulous mandible having alveolar ridge defect augmented with Hydroxyapatite (HA) crystals admixed with Platelet Rich Fibrin (PRF) membrane used as a barrier membrane.

Case Report

A 52 year old male patient, referred to the Department of Oral and Maxillofacial Surgery, Swargiya Dadasaheb Kalmegh

*Corresponding author: Dr. Monica Mahajan,

Department of Oral & Maxillofacial Surgery, Swargiya Dadasaheb Kalmegh Smruti Dental College & Hospital, Nagpur

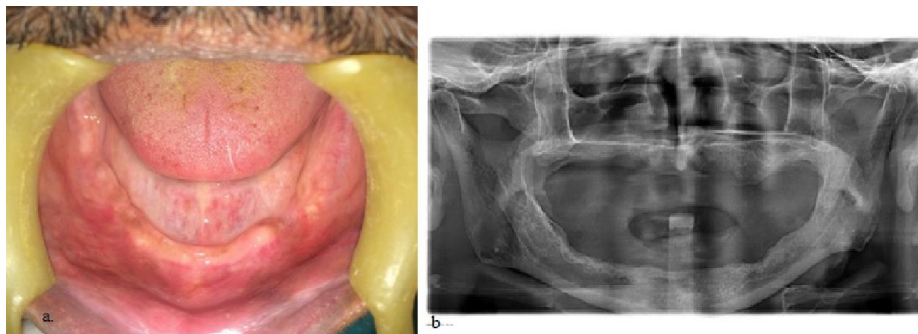


Fig. 1. Preoperative alveolar ridge defect seen in mandibular left premolar region. Fig1.a showing clinical photograph; Fig 1.b showing preoperative Orthopantomogram

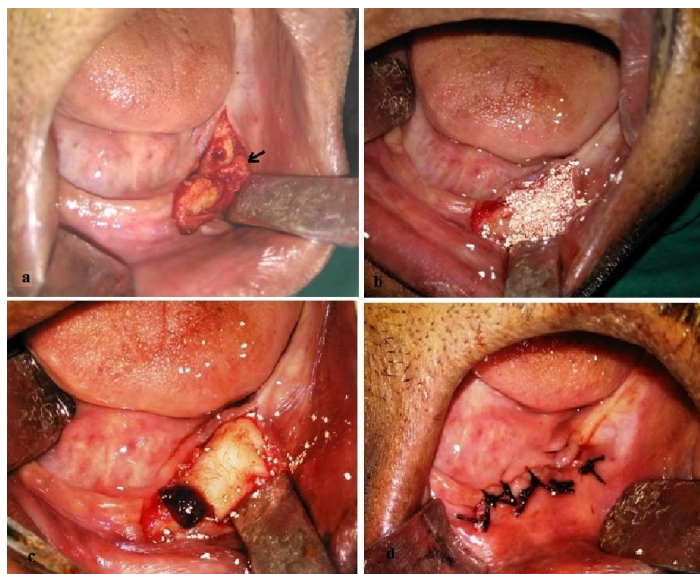


Fig. 2. Intraoperative photographs of the surgical procedure. Fig 2.a showing the alveolar defect and the exposed mental nerve (black arrow); Fig 2.b showing the defect filled with hydroxyapatite crystals; Fig 2.c showing PRF membrane placed over the hydroxyapatite graft acting as a barrier membrane; Fig 2.d showing suturing of the flap using 3-0 mersilk

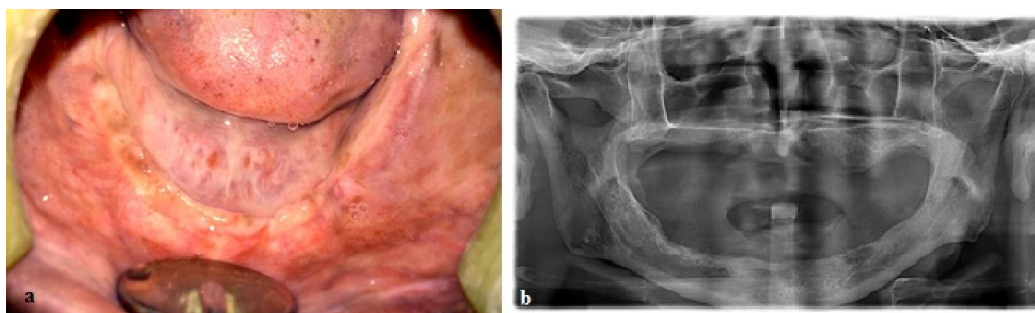


Fig. 3. 5 months postoperative photographs. Fig 3.a showing clinical photograph with corrected alveolar defect; Fig 3.b showing postoperative orthopantomogram showing newly formed bone in the grafted area

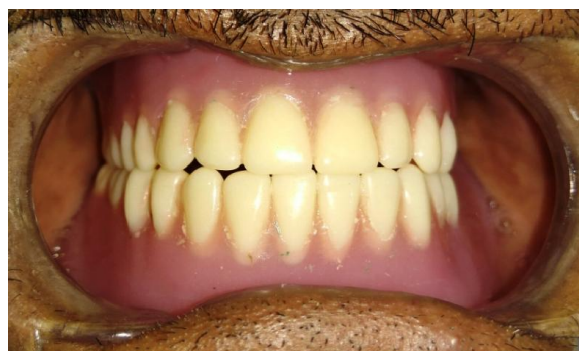

Fig. 4. Complete denture prosthesis rehabilitation with satisfactory stability, retention and esthetics

Smruti Dental College and Hospital, Nagpur for correction of an alveolar ridge defect in a mandibular edentulous ridge. The patient had undergone extraction of all his teeth in both the arches about 3 months back. He wanted to replace all his teeth using a complete denture prosthesis. On examination patient had completely edentulous upper and lower arches. A "V shaped" defect was present in the mandibular first and second premolar region. Routine blood examinations revealed no abnormal values. Radiological investigations (OPG) revealed a U shaped defect in the premolar region extending inferiorly till the region of the mental foramen. Plaster models were made for the analysis and the exact dimension of the defect was measured to be 10 x 7 x 5 mm³ mesio-distally, supero-inferiorly and bucco-lingually respectively. Patient was then explained about the surgical procedure and the requirement of graft and 20 ml blood for fabricating PRF. Informed consent was taken for the same. Antibiotic premedication were prescribed to the patient. On the day of surgery, patient was prepared under all aseptic precautions. Inferior alveolar and lingual nerve blocks using 2% lignocaine with 1:80,000 adrenaline was administered on the left side. After subjective and objective symptoms appeared, crestal incision was given from the canine region till the region of the first molar. Two releasing incisions were given, one at the mesial end of the canine region and the other at the distal end of the first molar region. Mucoperiosteal flap was raised and the defect was exposed. All the fibrous scar tissue was removed. The mental nerve was distinctly visible arising just at the crestal region of the defect. The nerve was guarded for the entire procedure, and the surrounding bone was prepared to receive the graft material. About 20 ml of patient's blood was withdrawn and centrifuged at 3000 rpm for 10 minutes. After PRF was formed, it was compressed between two glass slabs and two PRF membranes were made. Then the surgical site was isolated and 1 cc of hydroxyapatite crystals were mixed with saline and PRF membrane which was then placed in the defect. The other PRF membrane was placed over the graft and used as a barrier membrane. Flap was repositioned and sutured with 3-0 mersilk using mattress sutures. Postoperative instructions and antibiotic medications were prescribed. Patient was recalled on regular intervals for evaluation of the surgical site. Postoperative evaluation at the end of 5 months revealed well formed ridge contour and radiographic evaluation confirmed the formation of new bone at the grafted site. The complete denture prosthesis was made for the patient and denture delivery was done at the end of 6 months. The prosthesis was fabricated using a technique called "the Neutral Zone Technique". A well-polished denture was delivered to the patient. It was verified for stability, retention, occlusion, phonetics and esthetics suggesting good prognosis and acceptance by the patient.

DISCUSSION

Alveolar ridge defects pose a great problem during rehabilitation of edentulous patients. Seibert (1983) classified the localized alveolar ridge defects into Class I (horizontal), Class II (vertical) and Class III (horizontal & vertical) based on ridge deficiency. Allen *et al.* (1985) classified the ridge defects as mild (Depth <3 mm), moderate (Ranging from 3 mm to 6 mm) and severe (>6 mm), considering the relation of depth of the deformity to the adjacent alveolar bone level (Cawood and Howell, 1991). In this case the ridge defect was Class III (Seibert, 1983) and severe type (Allen *et al.*, 1985). During the past decade, ridge augmentation techniques have gained much attention in pre prosthetic surgery. Various augmentation

techniques are currently in use to create sufficient bone volume for reliable placement of prosthesis in resorbed alveolar ridges. Treatment of alveolar ridge defect consisted of four strategies; Bone replacement grafts, bone manipulation procedures, distraction osteogenesis and bone bioengineering. Selection of the surgical procedures for reconstruction of the alveolar ridge defect depends on many factors; site and size of the defect, intermaxillary relationships, donor site morbidity, thickness and height of the available bone, biological properties of the respective bone substitute material, and soft tissue deficiencies (Hegab *et al.*, 2015). So, keeping in view the options for augmentation of such localized defects, hydroxyapatite crystals and PRF was chosen. The reason why alloplastic material (hydroxyapatite) was used over autograft was the fact that the patient was completely edentulous with reduced mandibular as well as maxillary height. So, local autogenous grafts would have affected the stability of the prosthesis. There was also a risk of pathological fracture of mandible while harvesting the local autogenous graft. Distant autografts were not a indication in this case considering the size of the defect and patient's age. Also, the reason for selection of alloplasts over allografts such as Demineralized freeze dried bone grafts (DFDBG) or Freeze dried bone graft (FDBG) was that, the hydroxyapatite is more biocompatible and economical than the allografts (Frame *et al.*, 1987) (Herford and Nguyen, 2015). Considering the age and patient preference this was considered to be the best option. HA is extremely biocompatible in bone and soft tissue, and does not stimulate a foreign body reaction in the host. The healing response after implantation varies with the site, that is, whether it is placed within bone or used as an onlay between cortical bone and periosteum. Also, it varies with solid and porous forms of HA. Particles of HA, about 1 mm diameter, are frequently used for ridge augmentation. They are intended as a mouldable implant on the surface of the ridge beneath the mucoperiosteum, and accurately conform to the underlying bony morphology. This approach minimizes the problems of brittleness of HA (Frame *et al.*, 1987).

(PRF) is a second generation platelet concentrate used in conjunction with bone grafts, which offers several advantages including promoting wound healing, bone growth and density, graft stabilization, wound sealing, hemostasis and improving the handling properties of graft materials (Reddy *et al.*, 2015). In this study, PRF was not only used as an adjuvant growth factor for promoting bone regeneration, but also used as an effective barrier membrane between the graft and the overlying epithelium. This could be an extended use of PRF which economical and more beneficial than using any Guided Tissue Regeneration (GTR) membrane. Technically the use DFDBG or FDBG would have been a better option instead of hydroxyapatite, as these grafts have both osteoconduction and osteoinduction properties (Hegab, 2015). While HA is mainly a osteoconductive graft material (Frame *et al.*, 1987; Alan *et al.*, 2015). This drawback was overcome by the use of PRF as it is a growth concentrate and chiefly provides osteoinduction (Behnia *et al.*, 2012; Hegab *et al.*, 2015). This case gives us an insight that hydroxyapatite and PRF when used together can provide adequate bone regeneration at least in small to medium alveolar ridge defects.

Conclusion

The present technique of using Hydroxyapatite and PRF membrane for alveolar ridge augmentation produced a good alveolar bone regeneration maintaining a good ridge form and

contour. PRF membrane provided a satisfactory between the graft and the overlying mucosa. Thus it can be a substitute to the barrier membranes like GTR in various bone regeneration techniques for smaller defects. Further studies are needed to prove the efficacy of this technique.

REFERENCES

- Allen, E. P., Gainza, C. S., Farthing G. G., Newbold, D. A. 1985. Improved technique for localized ridge augmentation. A report of 21 cases. *J Periodontol.*, 56(4): 195-199
- Behnia, H., Khojasteh, A., Soleimani, M., Tehranchi, A., Atashi, A. 2012. Repair of alveolar cleft defect with mesenchymal stem cells and platelet derived growth factors: A preliminary report. *Journal of Cranio-Maxillo-Facial Surgery*, 40:2-7
- Caplains, N., Lozada, J. L., Khan, J.Y.K. 2009. Extraction Defect: Assessment, Classification and Management. *Int J of Clin Imp Dent*, 1(1):1-11
- Cawood, J. I. and Howell R. A. 1991. Reconstructive preprosthetic surgery. I. Anatomical considerations. *Int. J. Oral Maxillofac. Surg.*, 20. 75-82
- Frame, J.W. 1987. Hydroxyapatite As A Biomaterial For Alveolar Ridge Augmentation. *Int. J. Oral Maxillofac. Surg.*, 16: 642-655
- Hegab, A.F. 2015. Reconstruction of Mandibular Alveolar Ridge Defects for Implant Placement: Critical Review. *Int J Dent Oral Health*, 1(6):1-7
- Herford, A. S. and Nguyen K. 2015. Complex Bone Augmentation in Alveolar Ridge Defects. *Oral Maxillofacial Surg Clin N Am.*, 27:227-244
- Mercier, P. 1985. Ridge Form In Preprosthetic Surgery. *Oral Surg. Oral Med. Oral Pathol.*, 60:235-243
- Mercier, P. and Lafontant, R. M. 1979. Residual alveolar ridge atrophy: Classification and influence of facial morphology. *J. Prosthet. Dent*, 49(1): 90-100
- Reddy, P. K., Bolla, V., Koppolu P, Srujan, P. 2015. Long palatal connective tissue rolled pedicle graft with demineralized freeze-dried bone allograft plus platelet-rich fibrin combination: A novel technique for ridge augmentation-Three case reports. *J Indian Soc Periodontol.*, 19:227-31
- Seibert, J.S. 1983. Reconstruction of deformed partially edentulous ridges using full thickness onlay grafts: Part I - technique and wound healing. *Compend Contin Educ Dent*, 4:437-453
- Tal, H., Artzi, Z., Kolerman, R., Beitlitum, I., Goshen, G. 2012. Augmentation and Preservation of the Alveolar Process and Alveolar Ridge of Bone, Bone Regeneration, Prof. Haim Tal (Ed.), ISBN: 978-953-51-0487-2, InTech, Available from: <http://www.intechopen.com/books/bone-regeneration/augmentation-and-preservation-of-the-alveolar-process-and-alveolar-ridge-of-bone>
