



RESEARCH ARTICLE

A RARE CO-INHERITANCE OF Hb-D/ β -THALASSEMIA IN TWO CASES OF A RAJASTHANI FAMILY: CLINICAL RELEVANCE

Nidhi D Shah, Parth S Shah, Hari Shankar P Ray, Nikunj B Khatri, Ketan K Vagharia,
**Sandip C Shah and *Mandava V Rao

Supratech Micropath Laboratory and Research Institute & *Ex. Director, School of Sciences,
Gujarat University, Ahmedabad, Gujarat-India

ARTICLE INFO

Article History:

Received 23rd January, 2017
Received in revised form
08th February, 2017
Accepted 24th March, 2017
Published online 20th April, 2017

Key words:

Co-inheritance, Compound Heterozygous
and homozygous states,
DNA sequencing, Prenatal screening,
Phenotypic indices, β thalassemia traits

Copyright©2017, Dr. Rajashekar et al, This is an open access article distributed under the Creative Commons Attribution License, which permits unrestricted use, distribution, and reproduction in any medium, provided the original work is properly cited.

Citation: Dr. Rajashekar, K., Dr. Hariyesha, K.B., Dr. Hemanth, M., Dr. Karthik. J. Kabbur and Dr. Sharmada B.K. 2017. "Evaluation and comparison of bracket slot dimensions of commercially available pre adjusted edgewise appliance – an in -vitro study", *International Journal of Current Research*, 9, (04), 48804-48807.

ABSTRACT

We report a rare case of compound heterozygous condition of Hb-D/ β -thalassemia (Hb-D/ β^+) in a Rajasthani family of Western India after analyzing four samples (3 blood + CVS) using DNA sequencing and Hb electrophoresis including phenotypic indices. This condition is identified in Rajasthan state only with Hb-D/ β disease in two cases i.e. father and Chorionic villus sampling (CVS), though Hb-D Punjab traits are known. Hence, it is recommended that this condition may require blood transfusion on suggestion of clinician and phenotypic characters. Further six month old daughter suffered with β^0/β^0 mutations of homozygosity with blood transfusion too. Therefore it is rare and novel, is suggested to have prenatal screening for better management of families and to discourage marriages possessing such carriers in the society.

INTRODUCTION

Thalassemias are inheritable genetic disorders due to alteration in haemoglobin (Hb) production. The β thalassemia occurs as a result of mutation in Hb-B gene on chromosome-11 and follows autosomal recessive pattern of inheritance. It spreads from asymptomatic to symptomatic depending on genetic conditions (Cooley and Lee, 1925; Weatherall and Clegg, 2001 and Rao et al., 2015). It is frequent in Mediterranean region and South East Asia. India has about 60,000 people affected annually with β thalassemia minor, being highest in Gujarat, Rajasthan and Maharashtra (Sheth et al., 2008; Colah et al., 2010,2011; Bhukhanvala et al., 2013 and Chaudhary et al., 2016). Haemoglobin-D (Hb-D) is a haemoglobin variant occurring mainly in North West India, Pakistan and Iran. In India Hb-D variant is also called as Hb-D Punjab (also called as D North Carolina, D Chicago, D Portugal, D Los Angeles, D Oak Berg) (Wang and Ali, 1980; Atalay et al., 2007; Rahimi et al., 2006).

It occurs in at least four forms; heterozygous Hb-D, Hb-D thalassemia (Hb-D/ β or Hb-D/ β^+), Hb-D/Hb-S and homozygous Hb-D (Perea et al., 1999). Reports are available that individuals who are with compound heterozygous (Hb-D/ β thalassemia minor) mutations vary from thalassemia minor to intermedia clinically with mild to moderate symptoms of anemia and no marked changes in other haematological indices were reported except with high levels of HbD in 3 Iranian families (Taghavi et al., 2011). Similarly in Greece one case of such type is detected, whose clinical manifestation followed minor or intermedia type (Weatherall and Clegg, 2001 and Theodoridou et al., 2009). However, no such co-inheritance of Hb-D/ β thalassemia cases are detected in India as it is very rare and found only in Western India. In this report, however we present two such cases in addition to homozygous state in a family from Rajasthan in Asian subcontinent and its management in such conditions exposed is suggested.

*Corresponding author: Sandip C Shah,

Supratech Micropath Laboratory and Research, Kedar Complex, Opp. Krupa Petrol Pump, Nr, Parimal Garden, Ahmedabad-380006, Gujarat-India.

Case selection and methods

We received a family from Rajasthan state of western India for genetic testing of β -thalassemia upon Doctor's advice. Based

on this advice the parents and proband (daughter) blood and CVS (four samples) were analyzed for thalassemia mutations after completion of haemo-phenotypic indices. Patients consent from was also filled up prior to analysis. This work was approved by Gujarat University. Human Ethical Committee (GU HEC/001/2015), Ahmedabad India. The DNA was extracted and used for DNA sequencing using PCR and Sanger's technologies for eight common mutations viz, c.92+5G>C, deletion 619bp, c.79G>A (p.E27K), c.47G>A (p.Trp16Ter), c.364G>C (p.E122Q), c.27_28insG, c.51delC and c.124_127delTTCT were done at Supratech Micropath Laboratory, Ahmedabad.

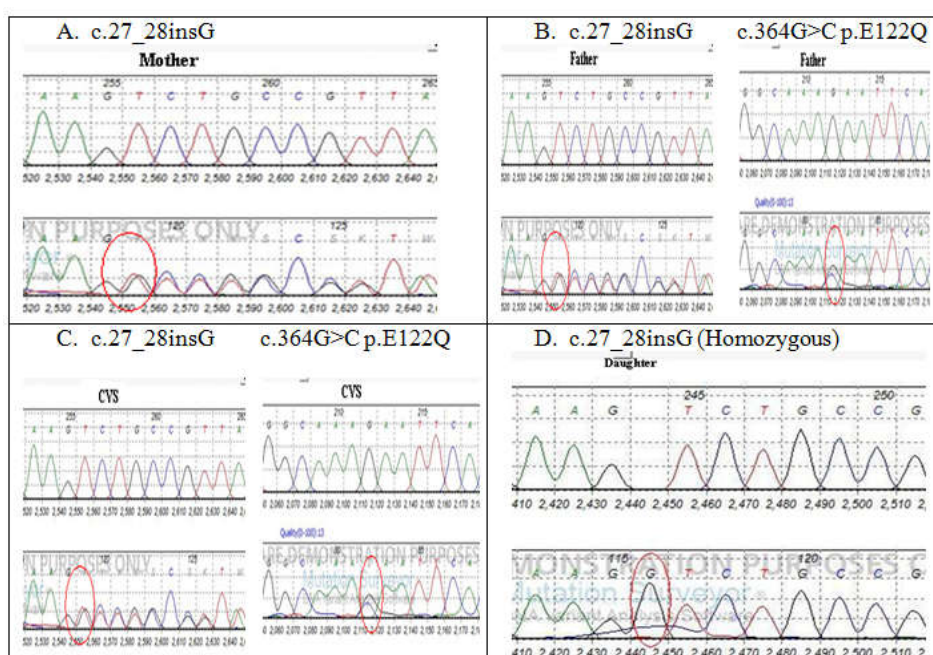
RESULTS AND DISCUSSION

Results revealed that father was detected compound heterozygous state (c. 364 G>C) Hb-D/ β thalassemia (c.27-28 InsG; β^0) and mother had β thalassemia trait/minor (c. 27-28 InsG). The mother had no significant values of HbA, HbA2 and red cell markers of MCV and MCH. But father had upper levels of HbD. The daughter had homozygous condition (β^0/β^0) with c.27-28 InsG having blood transfusion. Moreover, its HbA₂ and HbF levels were higher with a reduction in electrophoretic HbA and red cell markers.

Table 1. Haematological indices in Rajasthani family of Western India

Sample	Haemoglobin indices	Units	Normal Range	Mutations	Genotype	Inference /Clinical Report	Mutation identified by
Mother (25)	HbA	93.50	96.8-97.8%	c.27_28insG	β^0/β	Thalassemia Minor	Sanger sequencing
	MCV	66.40	83-100fL				
	MCH	21.70	27-32pg				
	RDW	18.20	11.5-14.5%				
	HbA2	5.90	2- 3.5%				
	HbE	-	Absent				
	HbF	0.60	<2% (Age Dependent)				
Father (27)	HbA	1.55	96.8-97.8%	c.27_28insG and c.364G>C p.E122Q	β^0/β^D	HbD/ β -Thalassemia*	Sanger sequencing
	MCV	75.30	83-100fL				
	MCH	22.80	27-32pg				
	RDW	16.30	11.5-14.5%				
	HbA2	3.80	2- 3.5%				
	HbE	-	Absent				
	HbF	0.25	<2% (Age Dependent)				
Proband/Daughter (1½)	HbA	1.40	96.8-97.8%	c.27_28insG	β^0/β^0	β -Thalassemia Major(Homozygous)	Sanger sequencing
	MCV	65.30	83-100fL				
	MCH	18.40	27-32pg				
	RDW	16.70	11.5-14.5%				
	HbA2	2.20	2- 3.5%				
	HbE	-	Absent				
	HbF	96.40	<2% (Age Dependent)				
CVS	-	-	-	c.27_28insG and c.364G>C p.E122Q	β^0/β^D	HbD/ β -Thalassemia*	Sanger sequencing

CVS= Chorionic villus sampling, MCV =Mean corpuscular volume, MCH= Mean Corpuscular Hemoglobin, RDW=Red blood cell distribution width. Figures in Parenthesis indicate age in years. * = Periodic transfusion as suggested by clinician also.



A. Mother showing with c.27_28insG B. Father with c.27_28insG and c.364 G>C P.E122Q (Compound heterozygous).C. CVS c.27_28insG and c.364 G>C P.E122Q. (Compound heterozygous) D. Proband (Daughter) had c.27_28insG (Homozygous). Nucleotide color; A=Green, T=Red, G= Black and C= Blue

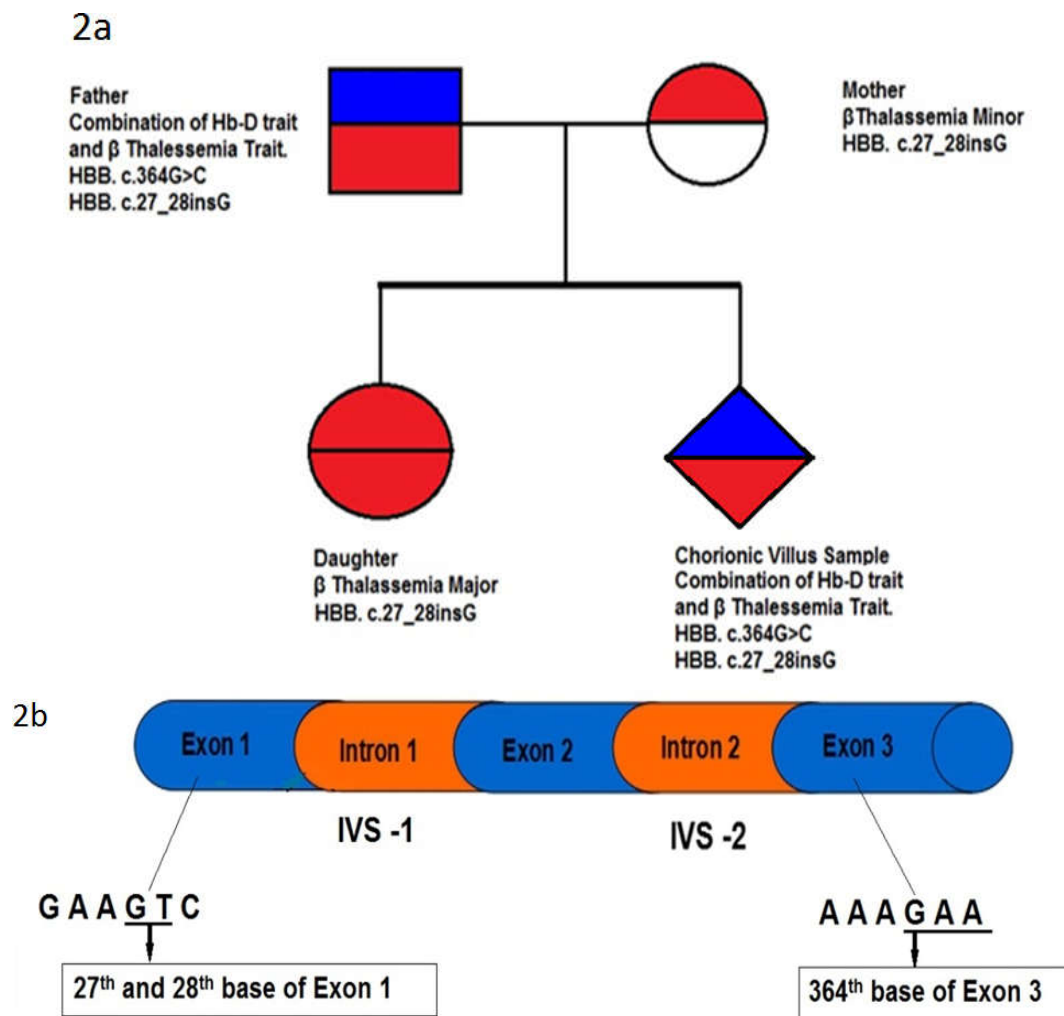


Figure 2a,2b. 2a. Pedigree chart depicting autosomal recessive inheritance pattern of gene mutation transmission in a family.
2b. HBB gene mutation location

The CVS contained (c.27-28 InsG ;(β^0) and c.364 G>C (Hb-D), which was compound heterozygous similar to father (two cases) in a family affected by β thalassemia intermedia type (Table-1, Fig-1). However, in the family of Rajasthan, in our study, father had compound heterozygous condition (β^0 /Hb-D) showing intermedia type supported by clinician who recommended periodic transfusion as he had higher HbD levels and anemic condition differing from mild to moderate (Weatherall and Clegg, 2001). Ahmed *et al.* (2001) pointed out that such these cases occasionally needed blood transfusion to corroborate our data. Mother had only β thalassemia trait (β^0) with mild type of thalassemia. But the daughter contained C 27-28 InsG, homozygous (β^0/β^0) genotype leading to thalassemia major with blood transfusion as suggested by a clinician and supported by haematological data where HbF levels were significantly more and HbA as well as RBC marker were reduced at the age of 6 months. But the CVS had Hb-D/ β thalassemia compound heterozygous state (β^0 /Hb-D) like that of father in this family leading to thalassemia intermedia condition. Wong and Ali (1980) identified Hb-D trait, Hb-D/ β^+ and Hb-D/ β^0 thalassemia in two Indian families of Canada strongly supporting our data, where compound heterozygous cases of HbD/ β thalassemia vary from mild to moderate anemic condition, affecting HbD levels and might fall into thalassemia intermedia type (Taghavi *et al.*, 2011). Further, co-inheritance of HbD/ β thalassemia individuals had no symptoms of profound anemia and haematological parameters and were similar to that of β -thalassemia minor or

intermedia in three Iranian families, however some cases require occasional transfusion, like that of our cases (Father, and may be CVS). One case of compound heterozygosity for Hb-D/ β thalassemia was also detected by Theodoridou *et al.*, (2009) in Greece. This study confirmed that this disease has clinical manifestations either thalassemia minor or thalassemia major (Weatherall and Clegg, 2001). So, the patient was exempted from whole blood donation for fear of long term consequences. Moreover, these reports support our investigation (Rahimi *et al.*, 2006 and Theodoridou *et al.*, 2009). In Western India our report is the first case identified in a father and CVS in a family from Rajasthan state. Although, co-inheritance of Hb-D/ β thalassemia cases are rare, Hb-D traits are detectable in Eastern India by Mondal and Mandal, (2016). Pedigree chart followed autosomal recessive inheritance pattern in the family about gene mutation transmission (Fig.-2a). The gene of Hb-B contains 3 exons separated by 2 introns. The location of Hb-B C.27-28 InsG is at Exon 1 and Hb-B C.364 G>C at exon 3 level. (Fig-2b)

Conclusion

The co-inheritance of Hb-D and β thalassemia (minor) exists rarely and two cases are identified by us in this family which is novel. It is mild to moderate type found in father and CVS cases and might require periodic blood transfusion as per clinician suggestion. The other proband (daughter) is homozygous (β^0/β^0) of thalassemia major on transfusion only.

Therefore to our knowledge so far available in the literature on this haemoglobinopathy, this report, with two cases of HbD/ β^0 thalassaemia disease and one patient of homozygous state (β^0/β^0) in a Rajasthani family of Western India is rare and novel. Hence, we recommend screening for thalassaemia is necessary before adopting reproductive technologies and also strongly discourage marriages between such thalassaemia carriers.

REFERENCES

- Ahmed, M., Stuhmann, M., Bashawri, L., Kuhnau, W. and El-Harith, E.H. 2001. The β -globin genotype E121Q/W15X (cd121GAA→CAA/cd15TGG→TGA) underlines Hb D/ β -(0) thalassaemia marked by domination of haemoglobin D. *Ann Hematol*, 80, 629-633.
- Atalay, E.O., Atalay, A., Ustel, E., Yildiz, S., Ozturk, O., Koseler, A. and Bahadir, A. 2007. Genetic origin of Hb D-Los Angeles [β 121(GH4)Glu→Gln, GAA→CAA] according to the beta-globin gene cluster haplotypes. *Hemoglobin*, 31(3),387-391.
- Bhukhanvala, D.S., Italia, K., Sawant, P., Colah, R., Ghosh, K. and Gupte, S.C. 2013. Molecular characterization of β -thalassaemia in four communities in South Gujarat-codon 30 (G→A) a predominant mutation in the Kachhiya Patel community. *Ann Hematol*, 92(11), 1473-1476.
- Chaudhary, S., Dhawan, D., Bahali, P.G., Chaudhary, P.S., Chaudhary, A., Singh, S. and Vudhathala, S. 2016. Compound heterozygous (β^+/β^0) mutation of HBB gene leading to β -thalassaemia major in a Gujarati family, A case study. *Mol Gen Meta Reports*, 7, 51-53.
- Colah, R., Gorakshakar, A. and Nadkarni, A. 2010. Global Bardew, distribution and preventing β -thalassaemia disorder. *Expert Rev Hematology*, 3, 103-117.
- Colah, R.B., Gorakshakar, A.C. and Nadkarni, A.H. 2011. Invasive & noninvasive approaches for prenatal diagnosis of haemoglobinopathies: Experiences from India. *Ind. J. Med. Res*, 134(4), 552-560.
- Cooley, T.B. and Lee, P. 1925. A series of cases of splenomegaly in children with anemia and peculiar bone changes Trans. *Am Pediatric Society.*, 30, 3729-3730.
- Mondal, S.K. and Mandal, S. 2016. Prevalence of thalassaemia and hemoglobinopathy in eastern India: A 10-year high-performance liquid chromatography study of 119,336 cases. *Asian J Transfu Sci*, 10, 105-110.
- Perea, F. J., Casas-Castaneda, M., Villalobos-Arambula, A.R., Barajas, H., Alvarez, F., Camacho, A., Hermosillo, R.M. and Ibarra, B. 1999. Hb D-Los Angeles associated with Hb S or beta-thalassaemia in four Mexican Mestizo families. *Hemoglobin*, 23, 231-237.
- Rahimi, Z., Akramipour, R., Korani, S. and Nagel, R.L. 2006. Hb D-Punjab [β 121(GH4) Glu-Gln]/ β^0 -thalassaemia [IVSII.1(G-A)] in two cases from an Iranian family: first report. *Am J Hematol*, 81, 302-303.
- Rao, M.V., Shah, S.R. and Patel, A.P. 2015. β -Thalassaemia In: Inborn errors of metabolism and genetic disorders. Gupta, P.D. and Shrivastav, L.M. Pug pub. *Chennai.*, pp. 169-179.
- Sheth, J.J., Sheth, F.J., Pandya, P., Priya, R., Davla, S., Thakur, C. and Flavin, V. 2008. Beta thalassaemia mutations in western India. *Ind J Pediatr*, 6, 567-570.
- Taghavi, B.M, Karimipour, M., Amirian, A., Jafarnejad, M., Katouzian, L., Valaei, A., Bayat, F., Kordafshari, A. and Zeinali, S. 2011. Co-inheritance of hemoglobin D and β -thalassaemia traits in three Iranian families: clinical relevance. *Arch Iran Medicine*, 14, 61-63.
- Theodoridou, S., Alemayechou, M., Perperidou, P., Sinopoulou, C., Karafoulidou, T. and Kiriakopoulou, G.2009. Compound heterozygosity for Hb D-Punjab / β -thalassaemia and blood donation: case report. *Turk J Haematol*, 26, 100-101.
- Wang, S.C. and Ali, A.M. 1980. Haemoglobin D Los angeles, D- β^+ thalassaemia and D- β thalassaemia a report of two families. *Acta haemat*, 63, 151-155.
- Weatherall, D.J. and Clegg, J.B. 2001. Thalassaemia Syndromes. 4th edition. *Blackwell Scientific Publications Oxford.*, pp1-846.
