



## CASE STUDY

### INTRAMUSCULAR MYXOMA OF THE GLUTEAL REGION PRESENTING AS A SCIATICA LIKE SYMPTOMS

\*Islam, S., Ramsingh, C., Bheem, V., Harnarayan, P. and Naraynsingh, V.

Department of General Surgery, San Fernando Teaching Hospital, San Fernando, Trinidad and Tobago

#### ARTICLE INFO

##### Article History:

Received 07<sup>th</sup> March, 2017  
Received in revised form  
13<sup>th</sup> April, 2017  
Accepted 21<sup>st</sup> May, 2017  
Published online 30<sup>th</sup> June, 2017

##### Key words:

Intramuscular myxoma,  
Gluteal, Hypothyroidism,  
Sciatica like symptoms.

#### ABSTRACT

Intramuscular myxomas are benign mesenchymal tumours. They are commonly found in the atrial muscle. A search of the literature reveals a small scattering of reported cases in the gluteal region. However gluteal myxoma presenting as sciatica like symptoms are very rarely reported. We present a case of a hypothyroid middle aged female who had complaints of sciatica with a noticeable left buttock mass and was treated successfully with surgical excision.

Copyright©2017, Islam et al. This is an open access article distributed under the Creative Commons Attribution License, which permits unrestricted use, distribution, and reproduction in any medium, provided the original work is properly cited.

Citation: Islam, S., Ramsingh, C., Bheem, V., Harnarayan, P. and Naraynsingh, V. 2017. "Intramuscular Myxoma of the Gluteal region presenting as a sciatica like symptoms", *International Journal of Current Research*, 9, (06), 52591-52594.

## INTRODUCTION

Intramuscular myxoma (IMM) is a rare benign soft tissue tumour of mesenchymal origin. It ordinarily presents as an isolated lesion. It is typically a slowly growing, deeply seated mass confined to the skeletal muscle. The symptoms, if any, are vague, unless compression of surrounding structures occurs. The only widely available diagnostic tests are imaging studies, such as ultrasonography, computed tomography (CT), and magnetic resonance imaging (MRI), which reveal a mass but cannot differentiate. The definitive diagnosis of IMM can only be made after its surgical excision, which is also agreed to be the treatment of choice. To the best of our knowledge, no known cases of malignantization exist. Recurrence occurs usually only in the instance of incomplete resection. If IMM exists in conjunction with fibrous dysplasia, it is known as Mazabraud syndrome.

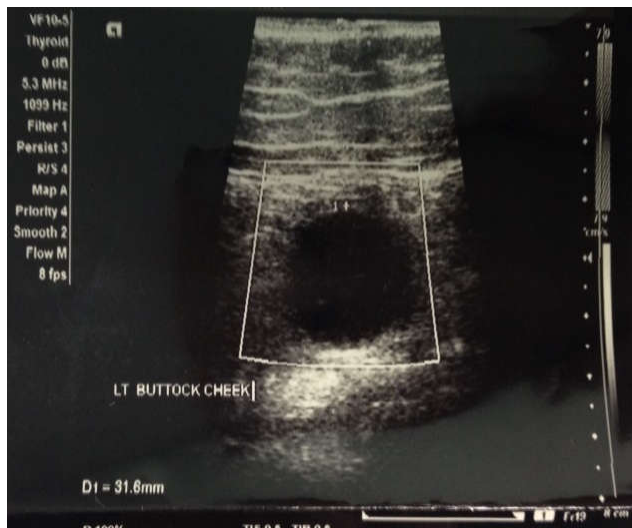
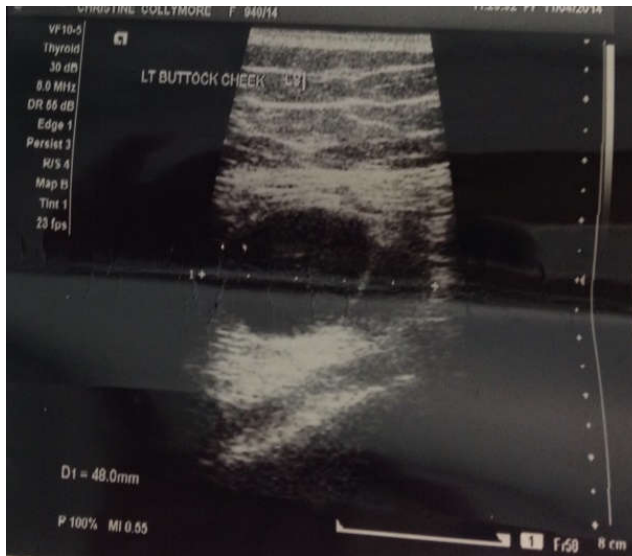### Case Report

A 53 year old female was referred to the surgical outpatient clinic for a left gluteal mass. The patient stated that she had this lump on her left buttock for several years which was painless and slowly growing. Over the last six months it was associated with tolerable shooting pain that radiated down the

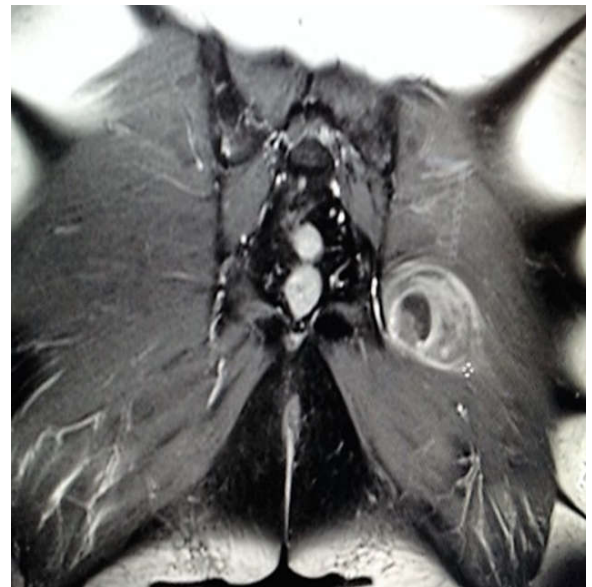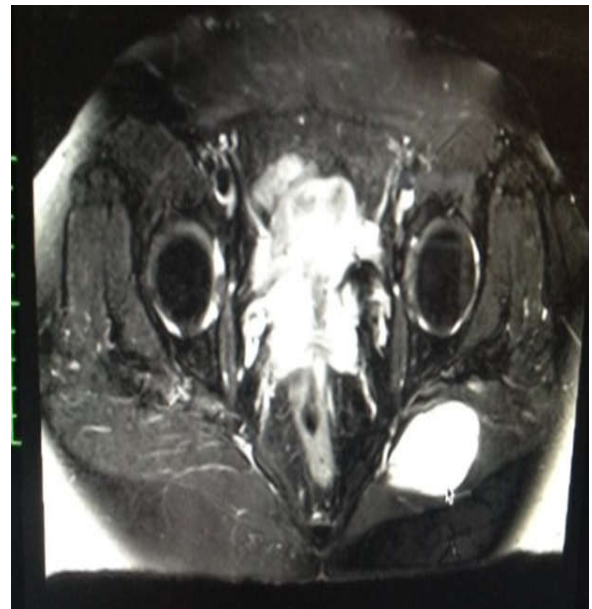left buttock and thigh on activity. This prompted her to come in for investigation and management. There were no overlying skin changes or constitutional symptoms. She denied trauma to the area. There were no other associated symptoms. No one else in the family had a history of similar masses, or of other syndromes or cancers. The patient is a known hypothyroid patient controlled with oral medication. She had ten packs per year history of smoking. The physical examination revealed a 2 cm x 2 cm palpable painless mass to the upper outer quadrant of the left buttock. It was hard, painless and deep to the skin. Musculoskeletal and neurological examinations were unremarkable. The laboratory investigations were within normal limits. An ultrasound of the left gluteal area revealed a 4.8 x 3.16 cm complex heterogeneous mass in the left gluteal muscle (Figures 1). A core needle biopsy was done at that time which showed no malignant cells, and was otherwise inconclusive. The patient subsequently had a magnetic resonance imaging (MRI) of the left lower limb which revealing a six (6) x four (4) cm heterogeneously enhancing solid lesion. The lesion was hypointense in T1 but hyperintense in T2 (Figures 2, 3). Radiological investigation of the appendicular and axial skeleton was negative for fibrous dysplasia. The decision was made for surgical excision of the mass. The patient was consented and the mass was excised completely. At the operation it was noted that the mass was very deep and closely associated with the left Sciatic nerve, which can well explained of her sciatica like symptoms. Great care was taken to successfully preserve this nerve. After

\*Corresponding author: Islam, S.  
Department of General Surgery, San Fernando Teaching Hospital, San Fernando, Trinidad and Tobago

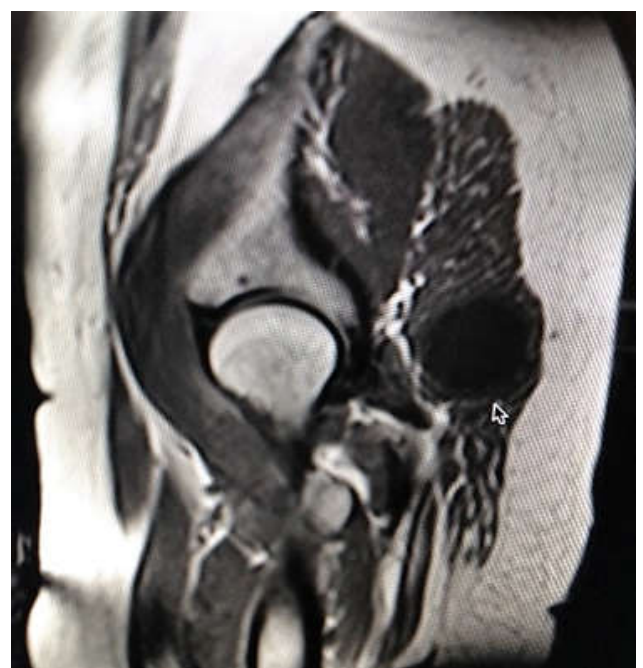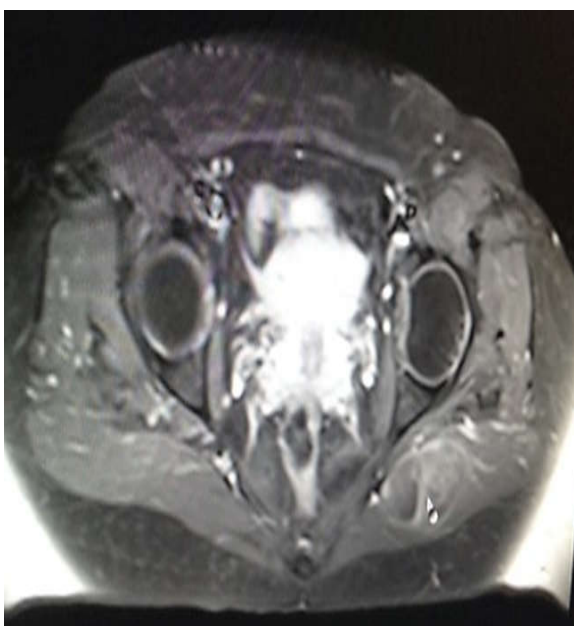
excision, the mass was transected, revealing mucoid gelatinous contents (Figure 4). The patient had an uneventful postop recovery and was completely symptoms free. She was discharged home on second postoperative day.



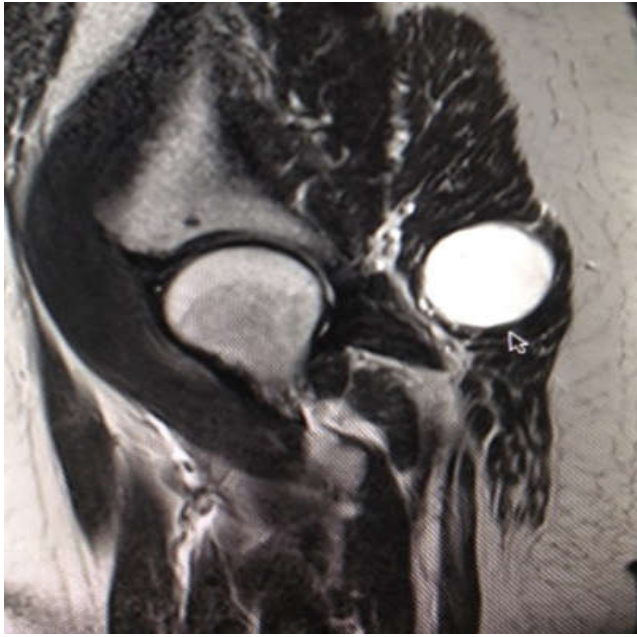
**Figure 1.** Doppler ultrasound of the left buttock showing a complex mass in left gluteal muscle measuring 4.8cm x3.16cm x



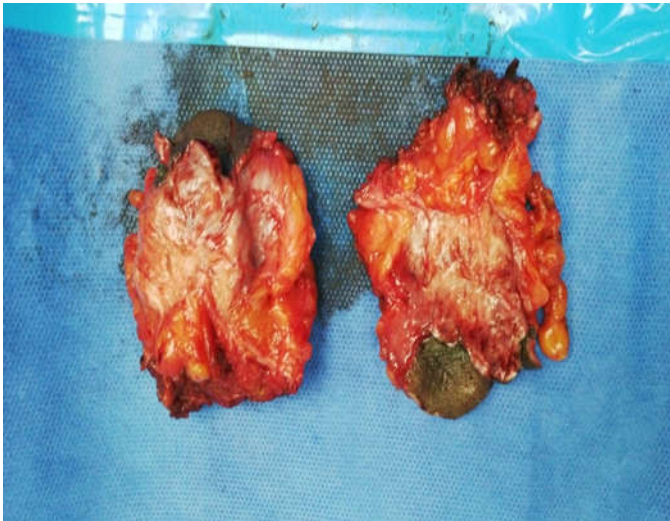**Figure 2.** Axial T1 & T2 weighted MRI images of left gluteal Intramuscular myxoma



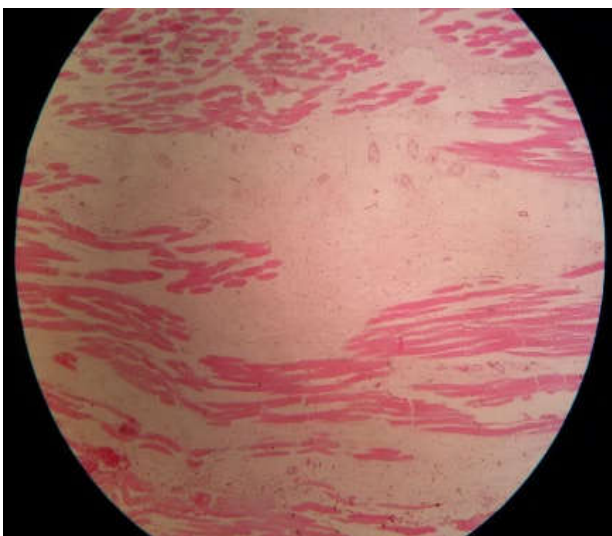




**Figure 3. Coronal T1 & T2-weighted MRI images of left gluteal Intramuscular myxoma**



**Figure 4. Intra operative view of the tumour**



**Figure 5. A photomicrograph showing the left gluteal intramuscular myxoma at high power resolution –spindle cells in myxoid tissue**

Histopathological examination of the specimen revealed multiple spindle cells in a myxoid background which was consistent with the diagnosis of benign myxoid tumor (Figure 5). The surgical margins were all clear. A diagnosis of intramuscular myxoma was thus confirmed. At 2 years follow up the patient is presenting doing well with no further complaints.

## DISCUSSION

Myxomas are a group of benign slowly growing tumours of skeletal muscle origin (Coloma *et al.*, 2014). Stout first described extra-cardiac myxomas in 1948 (Stout, 1948). Incidence is approximately one (1) per million population per year (Heymans *et al.*, 1998). Half of these are usually atrial in location. Of the remainder, the locations are 51% within the thigh, 9% in the arm muscles, 7% in the calf muscles and 7% in the buttock muscles (Murphey *et al.*, 2002). A review of the literature suggests the highest incidence between 40 and 60 years of age with preponderance towards the female gender (Spychala *et al.*, 2011; Nielsen *et al.*, 1998; Silver *et al.*, 2002). Myxomas are also found in Mazabraud's syndrome or Albright's syndrome in conjunction with fibrous dysplasia and other signs (Allen, 2000). The aetiology is unknown. Clinically these usually present as a single, painless, deep seated, intramuscular mass. There are no noticeable symptoms unless they are those arising from compression of surrounding structures. Investigations include the usual work up for preoperative screening. There has been one case report of a patient with elevated Ca 19-9 levels that returned to normal levels, six months after removal of the IMM. The aim of the study was to find a blood test that was specific and sensitive to IMM. However the authors noted a need for further investigation and correlation, with a greater sample size (Theodorou *et al.*, 2011). Radiological investigations like ultrasound can be used as an initial diagnosis method for both diagnoses as well as to obtain an ultrasound guided fine needle biopsy. In our patient ultrasound was used initially for diagnosis as well as for core needle biopsy. Magnetic resonance imaging is the diagnostic modality of choice. It helps in diagnosis of the tumor as well as guides in proper decision making for the surgery. It shows a typical picture of a hypo dense image on T1 and hyper dense image on T2 with a thin peripheral enhancement after gadolinium administration. (Heymans *et al.*, 1998; Murphey *et al.*, 2002; Silver, 2002; Yao *et al.*, 2007; Nishimoto *et al.*, 2004) Differentials for IMM include the low grade fibromyxoid sarcoma for which MUC4 expression is highly sensitive and specific and can be used to differentiate from IMM, which has no MUC4 expression (Yamashita *et al.*, 2013). Across the literature, complete surgical excision has been agreed to be the diagnostic and surgical treatment of choice for these tumours (King *et al.*, 2008). No known cases of malignantization, to the best of our knowledge exist. This tumour has been found to have no recurrence provided that adequate surgical margins are obtained (Charron and Smith, 2004).

## Conclusion

The clinical message of this report is to focus attention on the differential of IMM when faced with an isolated deep seated intramuscular mass. Further investigation needs to be done to source blood investigations that correlate with the mass. MRI is the first line option in imaging that is used to suggest a diagnosis of IMM. However, to this day, surgical resection and histopathological diagnosis are gold standard for a conclusive

diagnosis of IMM. Upcoming genetic research in conjunction with histopathologic data will give us more ways to classify the different types of IMM.

### Learning Points

- Myxoid tumors are rare benign tumors
- Gluteal myxomas presenting as sciatica like symptoms are rarely reported.
- In patient presenting with unilateral sciatica like symptoms, myxoid tumors should be considered as a differential.
- Adequate surgical excision is the key to prevent future recurrence.

### Acknowledgements

The authors acknowledge the doctors at the Department of Radiology and Nurses at the main operating theatre of San Fernando Teaching Hospital, Trinidad and Tobago for their active role in performing this surgery successfully.

**Conflicts of Interest:** The authors have declared no conflicts of interest

**Author's declaration:** The authors have nothing to disclose

**Patient's consent:** Patient consent was obtained for publication of this article

### REFERENCES

- Allen, PW. 2000. Myxoma is not a single entity: a review of the concept of myxoma. *Ann Diagn Pathol.*, Apr; 4(2).
- Charron P., Smith J. 2004. Intramuscular myxomas: a clinicopathologic study with emphasis on surgical management. *Am Surg.*, Dec; 70(12).
- Coloma J, García E., Rodríguez A. 2014. Intramuscular myxoma. Report of three cases. *Acta Ortop Mex.*, Jul-Aug; 28(4).
- Heymans O., Gebhart M., Alexiou J., de Saint Aubain N., Larsimont D. 1998. Intramuscular myxoma. *Acta Chir Belg.*, Jun; 98(3).
- King J, Friedman J, Iwenofu O, Ogilvie C. 2008. Buttock Mass in a 46 year old Woman. *Clin OrthopRelat Res.*, Aug; 466(8).
- Murphey M, McRae G, Fanburg-Smith J, Temple H, Levine A, Aboulaflia A. 2002. Imaging of soft-tissue myxoma with emphasis on CT and MR and comparison of radiologic and pathologic findings. *Radiology*, Oct; 225(1).
- Nielsen G, O'Connell J, Rosenberg A. 1998. Intramuscular myxoma: a clinicopathologic study of 51 cases with emphasis on hypercellular and hypervascular variants. *Am J Surg Pathol.*, Oct; 22(10).
- Nishimoto K., Kusuzaki K, Matsumine A, Seto M, Fukutome K, Maeda M, Hosoi S, Uchida A. 2004. Surrounding muscle edema detected by MRI is valuable for diagnosis of intramuscular myxoma. *Oncol Rep.*, Jan; 11(1).
- Silver WP, HJM, SSP. 2002. Intramuscular Myxoma: A Clinicopathologic Study of 17 Patients. *Current Orthopaedic Practice*, Oct; 403(1).
- Spychala A, Murawa D, Niziolek A. 2011. Intramuscular myxoma of the left leg—Case report of the lesion observed for several years. *Rep Pract Oncol Radiother.*, Mar; 16(2).
- Stout A.P. 1948. Myxoma, the tumor of primitive mesenchyme. *Ann Surg.*, 127:706.
- Theodorou D, Kleidi E, Doulamis G, Katsaragakis S. 2011. Intramuscular myxoma associated with an increased carbohydrate antigen 19.9 level in a woman: A case report. *Journal of Medical Case Reports*, May; 5(1).
- Yamashita H., Endo K, Takeda C, Teshima R, Osaki M, Yoshida H. 2013. Intramuscular myxoma of the buttock mimicking low-grade fibromyxoid sarcoma: diagnostic usefulness of MUC4 expression. *Skeletal Radiol.*, Oct; 42(10).
- Yao MS, Chen CY, Chin-Wei Chien J, Chen CL, Chan WP. 2007. Magnetic resonance imaging of gluteal intramuscular myxoma. *Clin Imaging*, May-Jun; 31(3).

\*\*\*\*\*