



ISSN: 0975-833X

Available online at <http://www.journalcra.com>

INTERNATIONAL JOURNAL
OF CURRENT RESEARCH

International Journal of Current Research
Vol. 9, Issue, 09, pp.57207-57212, September, 2017

RESEARCH ARTICLE

CLINICAL DIVERSITY OF EPIDERMOLYTIC HYPERKERATOSIS- A STUDY OF 5 CASES

Dr. Sunanda Mahajan and *Dr. Jayati Dave

Seth G.S. Medical College and KEM hospital, Mumbai

ARTICLE INFO

Article History:

Received 20th June, 2017
Received in revised form
16th July, 2017
Accepted 05th August, 2017
Published online 29th September, 2017

Key words:

Epidermolytic hyperkeratosis,
Bullous congenital ichthyosiform
Erythroderma of Brocq,
Ichthyosis hystrix,
Systematised verrucous
Epidermal nevus,
Ichthyosis bullosa of Siemens

ABSTRACT

Background: Epidermolytic hyperkeratosis (EHK) is a histopathological entity used for wide variety of clinical presentations. The primary pathological process is clumping of keratin filaments which is due to mutation in gene encoding for keratin 1 and 10 and thus they are clustered under a umbrella term 'Keratopathic ichthyosis'. The estimated prevalence of the disease is 1:200,000~300,000. We are presenting 5 clinical cases of EHK of sporadic nature.

Method: Clinically appearing cases of EHK further proven on biopsy were included in the study. Detailed clinical history with examination and photographs were undertaken after proper consent. The results were analysed thereafter and classified.

Results: We found one case with bullous congenital ichthyosiform erythroderma of Brocq (NPS 1). Two cases of Ichthyosis hystrix one each of Curth and Macklin and Lambert type, one case of systematised epidermal nevus, and one case of Ichthyosis bullosa of Siemens. All the cases were sporadic in nature.

Conclusion: EHK can have varying clinical presentations. Genetic counselling and pre natal testing can pick up early cases and help further.

Copyright©2017, Dr. Sunanda Mahajan and Dr. Jayati Dave. This is an open access article distributed under the Creative Commons Attribution License, which permits unrestricted use, distribution, and reproduction in any medium, provided the original work is properly cited.

Citation: Dr. Sunanda Mahajan and Dr. Jayati Dave, 2017. "Clinical diversity of epidermolytic hyperkeratosis- A study of 5 cases", *International Journal of Current Research*, 9, (09), 57207-57212.

INTRODUCTION

Background

Epidermolytic hyperkeratosis (EHK) is a histopathological entity found in a number of congenital and acquired skin disorders. There are several forms of clinical presentations. The primary pathological process is clumping of keratin filaments which is due to mutation in gene encoding for keratin 1 and 10 (Nicole, 2005), and thus they are clustered under a umbrella term 'Keratopathic ichthyosis'. The estimated prevalence of the disease is 1:200,000~300,000 (Koushik Pan, 2014).

MATERIALS AND METHODS

Clinically appearing cases of EHK further proven on biopsy were included in the study. Detailed clinical history with examination and photographs were undertaken after proper consent. The results were analysed thereafter and classified

RESULTS

There were total five cases consisting of 3 males and 2 females ranging within the age group 2-12 years.

*Corresponding author: Dr. Jayati Dave.
Seth G.S. Medical College and KEM hospital, Mumbai

There was history of third degree consanguinity in 2 cases with none having any family history of similar conditions. All the cases had an early age of onset before the age of 6 months (10 days – 6 months). Distribution of skin lesions was generalised in 3, with flexural accentuation in one and 2 cases had Blaschkoid pattern. In 4 cases verrucous plaques in varying distribution was the presentation, whereas in one case peeling of skin was observed. Blistering was present in 2 cases and palmoplantar involvement in the form of diffuse keratoderma was seen in 2 cases. Skin biopsy on H and E showed classical findings of EHK in all the cases (Figure-10). Mucosa, hair, nails and dentition were normal in all cases. Short stature was seen in one case. No other systemic association was observed.

Case one

A 8 year old male child born of a 3rd degree consanguineous marriage with thick malodorous skin all over body since 6 months of age. There was history of fluid filled lesions not predominantly over trauma prone site with molting of skin on taking treatment and improvement of skin in summers. On examination there was thick verrucous plaques with cobblestone appearance present all over body with extensors showing few areas of peeling of skin to leave dry skin. (Figure-1) The face and scalp showed ichthyosis with fine scaling. Based on, presence of blistering with generalised distribution with hystrix like scales and absence of palms and soles

hyperkeratosis, it was classified as EHK NPS-1. A clinical diagnosis of Bullous congenital ichthyosiform erythroderma of Brocq (BCIE) was made (Table 2) (John, 1994).

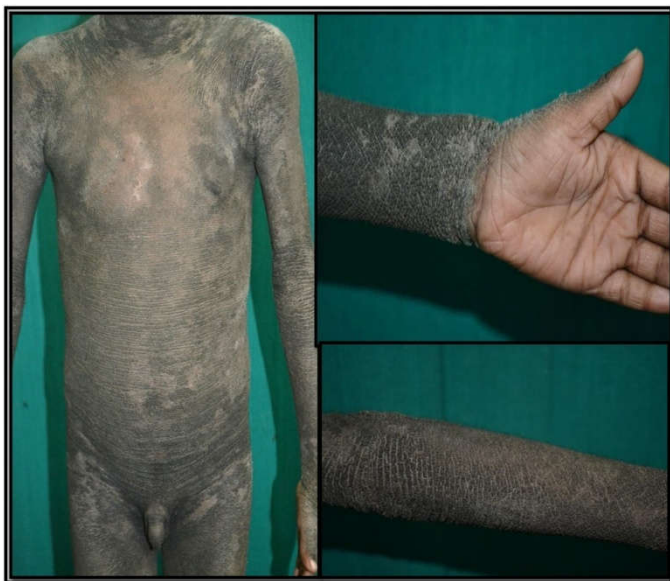

Figure 1. Thick verrucous plaques with cobblestone pattern present all over body with extensors showing few areas of peeling of skin to leave dry skin

Case two

A 5 year old male child born of third degree consanguineous marriage with complaints of peeling of skin and fluid filled lesions on trauma prone site since 10 days of birth. History of healing of lesions spontaneously with hyperpigmentation but no scarring. Patient had short stature. On Examination there was peeling of skin over bilateral hands and forearm and back with few collapsed blisters over back and abdomen. (Figure-2) Mauserung phenomenon (Figure 3) i.e. localization of dark grey hyperkeratosis to the flexural sites and areas of peeling of the skin among hyperkeratotic areas was present. There was presence of lichenification over flexures. Palms and soles showed yellowish hyperkeratotic skin. (Figure-4) Based on presence of palmo plantar hyperkeratosis, with localised blistering and scaling with absence of erythroderma was classified as EHK PS-1. (Table 2) (3). A clinical diagnosis of Ichthyosis bullosa of Siemens with palmoplantar keratoderma was made.

Case three

A 3 years female child born of non consanguineous marriage with complaints of thick hyperpigmented skin over body since 6 months of age with thickening of skin over palms soles with yellowish appearance since 3 months. There was no history of blistering at birth. On examination there was multiple linear hyperpigmented verrucous plaques with thick dry scaling arranged symmetrically in a blaszkoid pattern over body with palmoplantar keratoderma and sparing of face(Figure-5,6) . Based on classification of EHK, presence of hystrix scales in a generalised distribution and palms, soles involvement with absence of blistering could not be classified into any of the six types. (Table 2) (3). A diagnosis of Ichthyosis hystrix Curth and Macklin sporadic variant was made.

Case Four

A 2 years female child born of non consanguineous marriage with complaints of progressive thick blackish skin in a linear

pattern over body. There was no history of blistering at birth. On examination there was thick brownish warty excrescences in a blaszkoid pattern over body extending onto palms and soles with sparing of face (Figure 7). Based on classification of EHK, could not be classified into any of the six types (Table2) (3). We clinically diagnosed it as systematised epidermal nevus, sporadic variant.

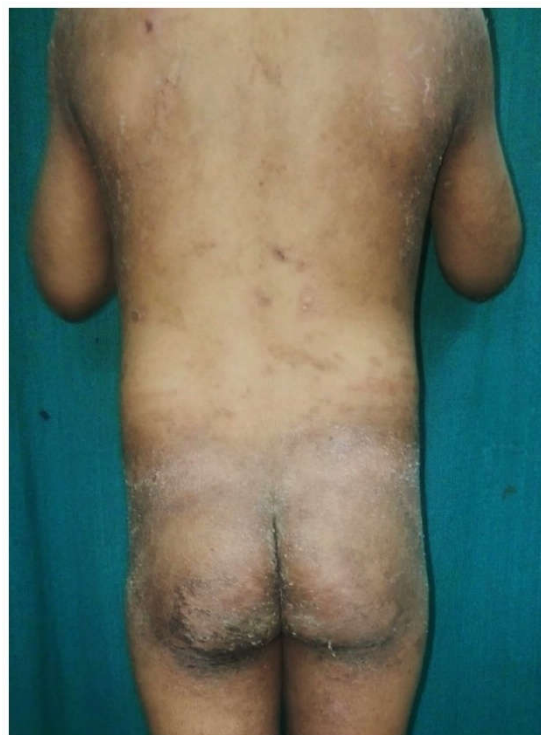

Figure 2. Peeling of skin and fluid filled lesions

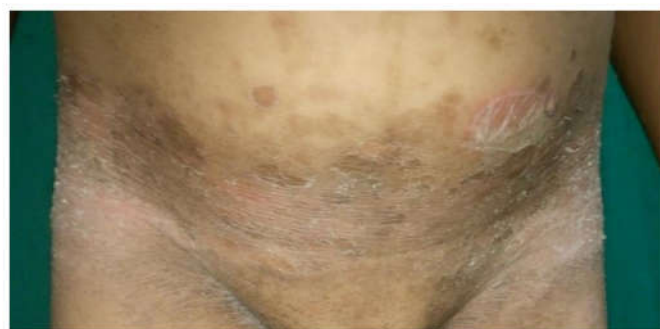

Figure 3. Mauserungs phenomenon

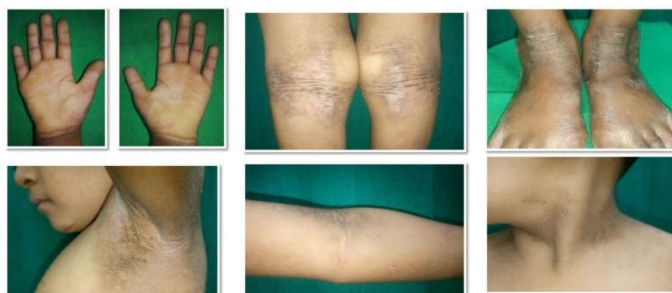

Figure 4. Diffuse palmoplantar keratoderma Lichenification over flexure ie bilateral cubital fossa, neck creases, popliteal fossa, ankle

Case Five

A twelve year old male born of non consanguineous marriage with complaints of multiple hyperpigmented lesions on

bilateral upper limb, lower limb and trunk since 2 months of age. No history of blistering prior to appearance of lesion. On examination there was verrucous ridged plaques on trunk with flexural lichenification (Figure 8). There was complete sparing of palms, soles, face and genitalia (Figure 9). Based on classification of EHK, hystrix like scaling with absence of blistering and palms soles involvement could not be classified into any of those 6 types (Table2) (John, 1994). We clinically diagnosed it as Ichthyosis hystrix Lambert type.

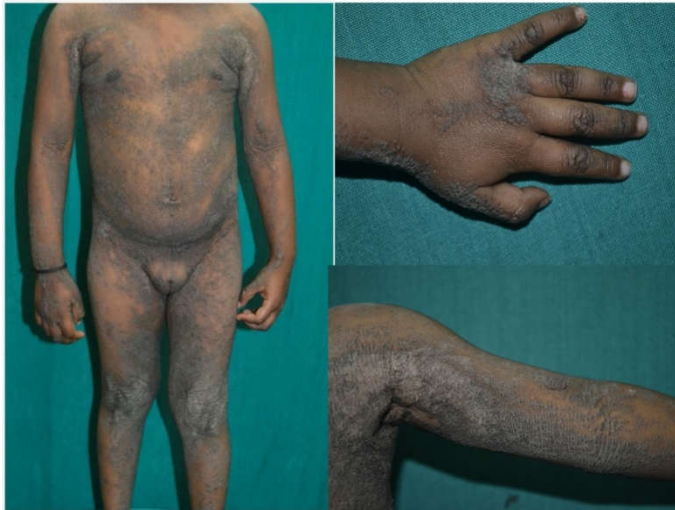

Figure 5. Multiple linear hyperkeratotic and hyperpigmented horny excrescences with thick dry scaling arranged symmetrically in a blaszkoid pattern over body

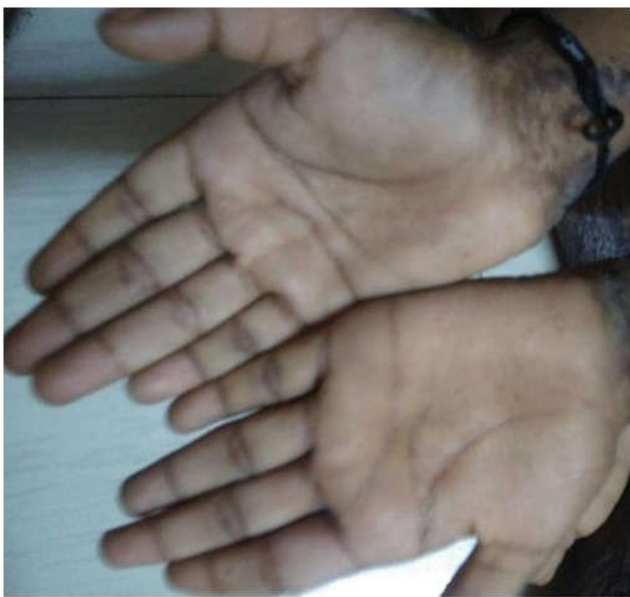

Figure 6. Yellowish keratotic thickened skin over bilateral palms suggestive of keratoderma

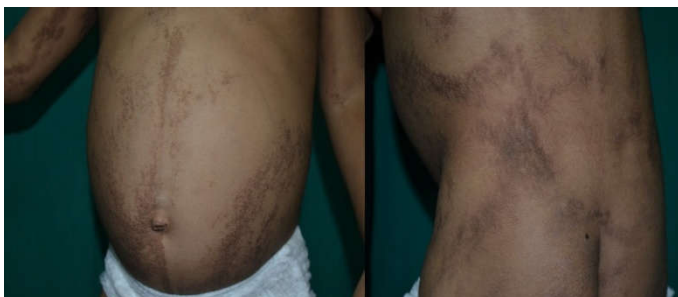

Figure 7. Thick brownish verrucous plaques in a blaszkoid pattern over body

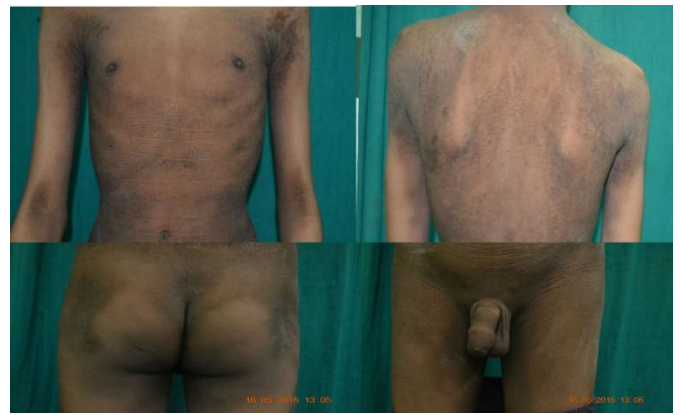

Figure 8. Verrucous ridged plaques on trunk with flexural lichenification

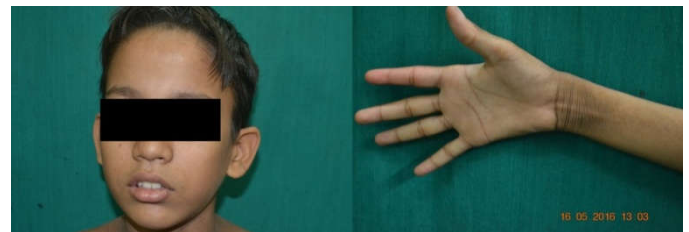

Figure 9. Complete sparing of face and palms

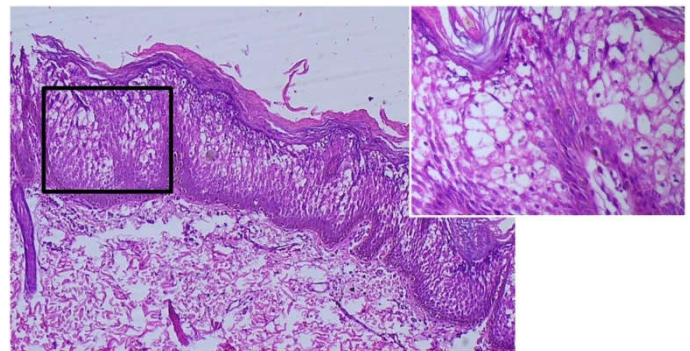


Figure 10. Orthohyperkeratosis, parakeratosis, acanthosis, hypergranulosis and vacuolated keratinocytes in spinous and suprabasal layer suggestive of Epidermolytic Hyperkeratosis

DISCUSSION

Epidermolytic hyperkeratosis (EHK) is a rare autosomal dominant disorder caused by mutations in KRT1 and KRT10 genes (Nicole, 2005). It can also arise by spontaneous mutation. Keratin 1 and 10 are coexpressed to form intermediate filaments in suprabasal layer of epidermis. A mutational defect of this gene causes structural defect leading to blistering, hyperproliferation and hyperkeratosis (Compton, 1992 and Shriya, 2003). The incidence is 1:100,000~300,000. EHK was first clinically described by Brocq in 1902 and was coined as Bullous congenital ichthyosiform erythroderma to differentiate from non bullous congenital ichthyosiform erythroderma (NBIE) (ShyhDyi Chuang, 1993). EHK is characterised by hyperkeratosis, parakeratosis, acanthosis, hypergranulosis with multiple perinuclear vacuoles and large keratohyaline granules in granular and spinous layers of epidermis on light microscopy (ShyhDyi Chuang, 1993 and Marcos, 2015). The term EHK was first coined by Frost and Van Scott in 1966 to describe histologic features of BCIE (Nicole, 2005 and ShyhDyi Chuang, 1993).

Table 1

Case	Age /sex	Consanguinity	Family history	Age of onset	Morphology	Distribution	Palms and soles involvement	Blistering	Associated abnormality	Digiovana and Bale EHK classification	Clinical diagnosis
1	8/M	+	-	6 months	Thick verrucous plaques with cobblestone pattern	Generalised with sparing of face	-	+	-	NPS -1	Bullous congenital ichthyosiform erythroderma of Brocq
2	5/M	+	-	10 days	Superficial peeling of skin with lichenification over flexures	Flexural with sparing of face	+(diffuse keratoderma)	+	short stature	PS-1	Ichthyosis bullosa of Siemens
3	3/F	-	-	3 months	Linear verrucous plaques	Blashkoid with sparing of face	+(diffuse keratoderma)	-	-	NA	Ichthyosis hystrixCurth-Macklin
4	2/F	-	-	2 months	Linear verrucous plaques	Blashkoid with sparing of face	+(extension of verrucous lesions	-	-	NA	Systematised verrucous epidermal nevus
5	12/M	-	-	2 months	Verrucous ridged plaques on trunk with flexural lichenification	Generalised with flexural accentuation	-	-	-	NA	Ichthyosis hystrix Lambert

Table 2. (3)

Characteristic	NPS-1	NPS-2	NPS-3	PS-1	PS-2	PS-3
Palm/sole hyperkeratosis	-	-	-	+	+	+
Palm/sole surface	Normal	Normal	Hyperlinear, minimal scale	Smooth	Smooth	Cerebriform
Digital contractures	-	-	-	-	+	-
Scale	Hystrix	Brown	Fine, white	Mild	White scale to peel	Tan
Distribution	Generalized	Generalized	Generalized	Localized	Generalized	Generalized
Erythroderma	-	-	+	-	+	-
Blistering	+	+	+	Localized	+	Neonatal

NPS - No palm / sole, PS - Palm / sole

Table 3. (16)

Clinical type	Clinical Feature
Curth and macklin	Cobblestone, ridged hyperkeratotic plaques over large joints with symmetrical plaques present widespread on body. Severe palmoplantar involvement with fissuring
Lambert	No blistering with sparing of palms, soles and face and spiny scales over body after 7 weeks of birth
Bafverstedt	Follicular hyperkeratosis with mild palmoplantar involvement
Rhedyt	Hyperkeratosis on face and limbs with hearing loss

Although the term has been coined for BCIE, it is not specific for it. It is seen in multiple conditions like keratinopathic ichthyotic disorders that include (Ichthyosis hystrix, Congenital reticular ichthyosiform erythroderma, Ichthyosis bullosa of Siemens), melanocytic nevi, normal oral mucosa, nevus comedonicus, white sponge nevus, seborrheic keratosis, squamous cell carcinoma, epidermolytic leucoplakia, actinic keratosis, dilated pore, pilar cysts (ShyhDyi Chuang, 1993 and Marcos Takeyoshi, 2015). Traupe *et al* described types of EHK ie BCIE of Brocq, IBS and Ichthyosis hystrix Curth and Macklin. In a study conducted by DiGiovanna and Bale (1994) proposed a classification of EHK as given below (John, 1994).

BCIE clinically presents with erythema and blisters which later get denuded to form superficial ulcerations more over flexures and trauma prone sites (Nicole, 2005). The blistering improves with age and is replaced by thick grayish blackish excrescences (Nicole, 2005). The scales have a quill-like (spiny) (Asher Ahmed Mashhood, 2009). Appearance (ichthyosis hystrix) hence also known as porcupine man. About 71% have presentation at birth and 94% by the first year of life (Martina Kucharekova, 2007). Hyperkeratosis of palms and soles is seen when associated with keratin 1 mutation as keratin 10 is not expressed on palms and soles (Martina Kucharekova, 2007). Sixty percent of BCIE have KRT1 mutations (Martina Kucharekova, 2007). Hair, nails and mucosa are usually normal. We found the case 1 in our series had similar findings with absence of palms and sole involvement and negative family history so likely having sporadic mutation of keratin 10. Ichthyosis bullosa of Siemens (IBS) is a milder variant of EHK first described by Hermann Werner Siemens in 1937 (Heiko Traupe, 1986). It is differentiated from BCIE by absence of erythroderma, localisation of dark grey hyperkeratotic skin to flexures and circumscribed areas of superficial peeling of skin known as 'Mauserungs phenomenon' or moulting (Heiko Traupe, 1986). It is also known as superficial epidermolytic ichthyosis due to presence of hyperkeratosis and vacuolar degeneration confined to stratum granulosum and upper part of stratum spinosum (Rajiv, 2006), unlike in BCIE it extends upto stratum basale (Gwang Seong, 1997), as the genetic defect involves keratin 2e which is expressed in differentiated cells of epidermis. Case 2 of the series had similar findings but the presence of palmoplantar keratoderma is a rare unique entity.

Ichthyosis hystrix is a term used for spiky verrucous hyperkeratotic skin (Sonya Márina, 2015). It includes systematized verrucous epidermal nevus, inflammatory linear verrucous epidermal nevus and disorders of keratinisation (Gwang Seong Choi, 1997). The condition was first described in the Lambert family in England in the early 18th century. The verrucous epidermal nevus (VEN) is divided based on histology into epidermolytic hyperkeratosis and non epidermolytic hyperkeratosis. EHK is seen in very few cases of VEN ie 5% (Pollozhani Nora, 2016).

Non epidermolytic VEN shows hyperkeratosis, hypergranulosis, acanthosis, and papillomatosis with or without inflammation (Pollozhani Nora, 2016). In a study conducted by Tsubota *et al.* epidermal nevi with EHK histological features are associated with mutations in the genes encoding keratin 10 and keratin 1 and represent mosaic forms of BCIE (Akiko Tsubota, 2007). In addition to cutaneous mosaicism parents with epidermolytic epidermal nevi are also likely to have gonadal mosaicism and likely to produce

offsprings with BCIE indicating EHK as a important prognostic factor (Pollozhani Nora, 2016 and Sonya Márina, 2015). Case 4 of the series had linear verrucous lesions along Blaschko's lines with extension to palm and soles suggestive of systematized verrucous epidermal nevus Ichthyosis hystrix is differentiated from BCIE of Brocq by absence of blistering and erythroderma and nevoid form. There are 4 types of Ichthyosis hystrix (Table 3) (Pragya, 2017). Based on features shown in table 3, case 3 had classic clinical findings with EHK and no family history suggestive of sporadic variant of Ichthyosis hystrix Curth and Macklin.

Case 5 of the series showed sparing of palms and soles, hyperkeratotic verrucous skin over body with absence of blistering suggestive of ichthyosis hystrix Lambert type. The most common complication in blistering disorders are foul smelling odour due to secondary bacterial infection, if untreated can cause sepsis. Also chances of fluid and electrolyte imbalance secondary to erythroderma is seen in infancy. There is no role for any therapeutic intervention, symptom reduction and prevention of complication is the mainstay. Also genetic counselling of the parents of affected infants should be done to plan further pregnancies and advise on prenatal testing as tonofilament clumps can be detected in epidermal cells in affected fetus (ShyhDyi Chuang, 1993). A regimen of daily bathing with antiseptic cleansers to reduce the bacterial load on skin with application of moisturisers at regular interval would keep the skin supple. Urea based moisturisers and alpha hydroxy acids help reduce hyperkeratosis. Keratolytic agents in the form of topical and oral such as Acitretin and Etretinate can be tried (Surajit Nayak, 2013). Topical agents on localised sites of hyperkeratosis such as in IBS can be used. However keratolytic agents reduce scaling but increases skin fragility and blistering thus should be used judiciously (ShyhDyi Chuang, 1993).

Conclusion

EHK can have varying clinical presentations. Based on the clinical presentation it can be grouped into specific type most of the times. All extensive linear epidermal nevi should be biopsied and in case of EHK the parents should be given genetic counselling and offered prenatal diagnosis.

REFERENCES

- Akiko Tsubota, Masashi Akiyama, Kaori Sakai, Maki Goto, Yukiko Nomura, Satomi Ando, Masataka Abe, Daisuke Sawamura and Hiroshi Shimizu; Keratin 1 Gene Mutation Detected in Epidermal Nevus with Epidermolytic Hyperkeratosis; The Society for Investigative Dermatology; (2007), Volume 127. 1371-1374
- Asher Ahmed Mashhood, Nadia Iftikhar, Zafar Iqbal Sheikh. Epidermolytic hyperkeratosis a histological hallmark in the diagnosis of bullous ichthyosiform erythroderma. *Journal of Pakistan Association of Dermatologists* 2009; 19: 168-170
- Compton, J.G., Di Giovanna, J.J., Santucci, S.K., Kearns, K.S., Amos, C.I., Abangan, D.L., Korge, B.P., McBride, O.W., Steinert, P.M., Bale, S.J. 1992. Linkage of epidermolytic hyperkeratosis to the type II keratin gene cluster on chromosome 12q: Nat Genet. Jul;1(4):301-5.

- Gwang Seong Choi, Ji Sub Song, Eun So Lee, Won Hyoung Kang, Sungnack Lee. *Annals of Dermatology*, vol9,no 3, July 1997
- Heiko Traupe, Dr.med., Gerhard Kolde, Dr.med., Henning Hamm, Dr.med., and Rudolf Happle, Dr.med. Miinster, Federal Republic of Germany. Ichthyosis bullosa of Siemens: A unique type of epidermolytic hyperkeratosis. *Journal of the American Academy of Dermatology*. Volume 14 Number 6 June, 1986
- John J. DiGiovanna, Sherri J. Bale. Clinical Heterogeneity in Epidermolytic Hyperkeratosis. *Arch Dermatol*. 1994; 130: 1026-1035
- Koushik Pan, Subrata Chakrabarti, Rajdip Choudhury, Anup Sarkar, Ritabrata Mitra. Epidermolytic hyperkeratosis: a rare case. *International Journal of Research in Medical Sciences* 2014 Feb;2(1):347-349
- Marcos Takeyoshi, Hayashida I Grasiela Lissa Mitsui, Natalia Ivanoff dos Reis Giovana Fantinato I Domingos Jordão Neto Ana Maria da Cunha Mercante. Epidermolytic Hyperkeratosis - case report. *An Bras Dermatol*. 2015; 90(6): 888-91
- Martina Kucharekova, Klara Mosterd, Veronique Winnepenninckx, Michel van Geel, Anja Sommer, Maurice A. M. van Steensel,. Bullous congenital ichthyosiform erythroderma of Brocq. *International Journal of Dermatology*., 46 (Suppl. 3), 36-3
- Nicole L. Lacz, Robert A. Schwartz, George Kihiczak. Epidermolytic hyperkeratosis: a keratin 1 or 10 mutational event. *International Journal of Dermatology February* 2005; 44:1-6
- Pollozhani Nora, Damevska Katerina, Silviya Duma, Adjievska Nevena and Gocev Gorgi. Epidermolytic hyperkeratosis: clue for diagnosis. *Glob Dermatol*, 2016, Volume 4(1): 1-3
- Pragya, A. Nair, Rochit Singhal, Shailee Gandhi, Nilofar Diwan. A sporadic case of ichthyosis hystrix: Curth and Macklin; *Indian Dermatology Online Journal* | Volume 8 | Issue 2 | March-April 2017
- Rajiv, S., Rakesh, S.V. 2006. Ichthyosis bullosa of Siemens: Response to topical tazarotene. *Indian J Dermatol Venereol Leprol* | January-February 2006 | Vol 72 | Issue 1
- Shriya Dave, S. V Rakesh, Devinder Mohan Thappa. Bullous Congenital ichthyosiform Erythroderma - PS 1 Type: 2003 | Volume : 48 | Issue : 2 | Page : 108-111
- Shyh Dyi Chuang, Hsein-ching chiu, Chun-Hsiang Chang, Wen Lee Kuo. Bullous congenital ichthyosiform erythroderma (Epidermolytic hyperkeratosis), *Dermatolol-Sinica* 1993 11:185-198
- Sonya Márina, Kristina Semkova, Jana Kazandjieva, Dimitrina Guleva: Systematized epidermolytic epidermal nevus (ichthyosis hystrix); *Scripta Scientifica Medica*, vol. 47, No 3, 2015, pp. 78-81
- Surajit Nayak, Basanti Acharjya, Prasenjit Mohanty, Ichthyosis hystrix: *Indian Dermatology Online Journal* - January-March 2013 - Volume 4 - Issue 1.
