



## CASE STUDY

### ACUTE NECROTIZING ULCERATIVE GINGIVITIS

**\*Dr. Chitra Patil**

GDC, Mumbai, India

#### ARTICLE INFO

##### Article History:

Received 24<sup>th</sup> June, 2017  
Received in revised form  
20<sup>th</sup> July, 2017  
Accepted 13<sup>th</sup> August, 2017  
Published online 30<sup>th</sup> September, 2017

##### Key words:

Acute necrotizing ulcerative gingivitis,  
Stress, Pregnancy.

Copyright©2017, Dr. Chitra Patil. This is an open access article distributed under the Creative Commons Attribution License, which permits unrestricted use, distribution, and reproduction in any medium, provided the original work is properly cited.

Citation: Dr. Chitra Patil, 2017. "Acute necrotizing ulcerative gingivitis", *International Journal of Current Research*, 9, (09), 57652-57655.

#### ABSTRACT

Acute Necrotizing Ulcerative Gingivitis (ANUG) is described as "a rapidly destructive, non-communicable, gingival infection of complex etiology". It is characterized by necrosis of the crest of the gingival papillae, spontaneous bleeding, pain and halitosis. If left untreated, it may spread laterally and apically to involve the entire gingival complex, including the mucosa and alveolar bone, leading to necrotizing ulcerative periodontitis to necrotizing ulcerative stomatitis and finally Noma. There are various predisposing factors like poor oral hygiene, stress, smoking, hormonal imbalance, nutritional deficiencies etc. This case report presents the conservative management of ANUG in patient and probable mechanism of pathogenesis of predisposing factors involved.

## INTRODUCTION

Acute necrotizing ulcerative gingivitis (ANUG) is a severe and painful form of gingivitis characterized by gingival pain, bleeding and necrosis of the interproximal papillae. Although known since ancient times by a multitude of names, ANUG was first described by Plaut (Barnes *et al.*, 1973) in 1894 and Vincent (Miller, 1950) in 1896. It has been called by many names like Vincent's disease, trench mouth, and fusospirochetalgingivitis. This form of gingivitis is relatively rare. Proliferating oral anaerobic bacteria are involved in the development of the clinical signs and symptoms of the disease, possibly as opportunistic pathogens. Studies have speculated on the importance of secondary predisposing etiologic factors, such as stress, impaired chemotaxis, poor oral hygiene, alcohol consumption, smoking, general debilitation and malnutrition.

### Case report -1

A 20 year old female patient reported to the Department of Periodontology of Government Dental College and Hospital, Mumbai with a chief complain of generalized pain, swelling and bleeding in the gums and showing necrotic appearance and visible suppuration (Figure 1A and 1B). There was greyish pseudomembrane in the palatal gingival which had extended into the attached gingiva of the hard palate (Figure 2A and 2B). There was difficulty in chewing since last 4 days. Patient was apparently alright 4 days back when pain of sudden onset initiated in the gums, generalized in nature especially in lower

left back region. This was followed by swelling in lower left region with raised temperature which subsided on taking medication. Patient was unable to eat and drink due to the acute pain with presence of foul breath. Patient gave history of pregnancy and was in the 3<sup>rd</sup> trimester (7<sup>th</sup> month). On extra oral examination, there was no gross facial asymmetry detected but submandibular lymphnodes were palpable and extraoral swelling seen (Figure 3). Since the patient was pregnant, a written consent was asked for from the patient's Gynecologist for starting dental prophylaxis and for initiating Metronidazole regimen. A written consent was given by the Gynecologist for dental prophylaxis and initiating Metronidazole under due risk. Tablet Metrogyl 400mg was initiated only after the patient was counseled about the due risk and a written consent obtained. In the first visit after thorough examination, only conservative treatment like removal of local factors and maintenance of oral hygiene was planned. She was also instructed to rinse with 3% H<sub>2</sub>O<sub>2</sub> & sterile warm water (1:1) four times a day and also with 0.12% chlorhexidine rinses to maintain oral hygiene as she was unable to clean her teeth with a brush. Patient was recalled on second day and supragingival scaling was done. After 3 days the patient was re-evaluated and scaling and curettage was performed. After 7 days patient was almost symptom free so thorough scaling & root planing was done. Warm saline gargles were advised as an adjunct. Patient was advised to take adequate rest, proper diet and maintain proper oral hygiene and was on maintenance phase.

### Case report -2

A 24 year old female patient reported to the Department of Periodontology of Government Dental College and Hospital,

\*Corresponding author: Dr. Chitra Patil,  
GDC, Mumbai, India.

Mumbai with a chief complain of ulcerations on gums since 2 days. She gave a history of fever and foul breath and difficulty in eating food. Her history revealed of unemployment of her husband since past one year. There were ulcers which were covered with pseudomembranous slough present on marginal and papillary gingiva. On extra oral examination, there was no facial asymmetry detected, lips were competent, bilateral submandibular lymphnodes were tender on palpation and local rise in temperature was detected. Patient gave the history of elevated temperature for the past 1 week. On intraoral examination poor oral hygiene was noticed with plaque and calculus deposition. There was swollen marginal gingiva and interdental papilla with rounded contour and also necrosis of the interdental papillae (Figure 4A and 4B). There were ulcers present on vermillion border of lower lip (Figure 5). Bleeding was present on slight stimulation of gums. In the first visit after thorough examination, only conservative treatment like removal of local factors and maintenance of oral hygiene was planned. Supragingival scaling was attempted as thoroughly as the condition allowed. Patient was advised to take adequate rest, proper diet and maintain proper oral hygiene. She was prescribed amoxicillin 500 mg every 6 hours for 5 days and local application of gel containing metronidazole three-four times a day. She was also instructed to rinse with 3% H<sub>2</sub>O<sub>2</sub> & sterile warm water (1:1) four times a day and also with 0.12% chlorhexidine rinses to maintain oral hygiene. Patient was recalled on second day and again supragingival scaling was done. After 3 days the patient was re-evaluated and scaling and curettage was performed. After 7 days, patient was almost symptom free so thorough scaling & root planing was done. 3% H<sub>2</sub>O<sub>2</sub> rinses were now discontinued but 0.12% chlorhexidine rinses continued. Patient was re-evaluated after one month & a good response was found in the form of healing of the necrotic areas. Patient was kept on maintenance with instructions of oral hygiene and proper nutrition.

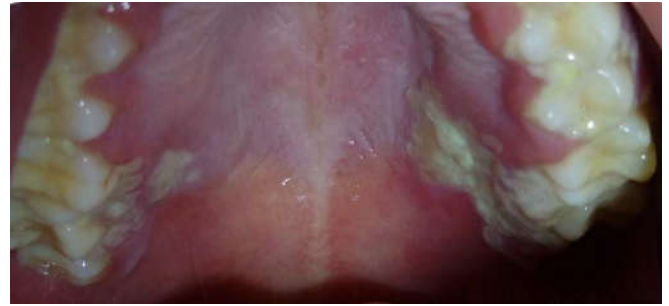

Figure 2A. Preoperative view of palate showing pseudomembrane in case 1

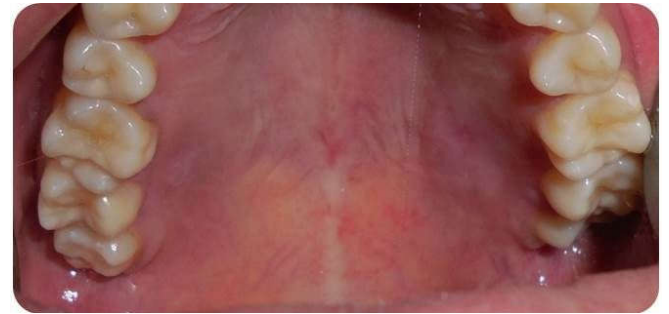


Figure 2B. Postoperative view of palate showing complete healing in case 1

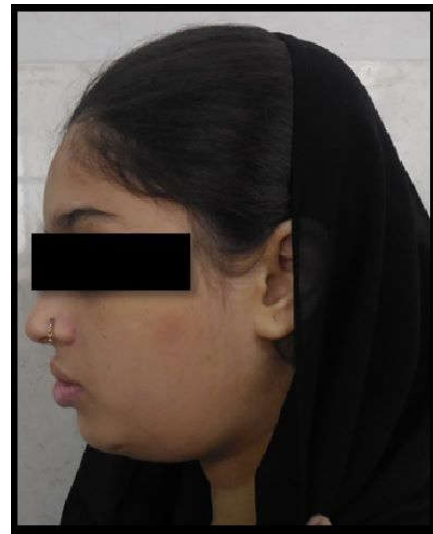

Figure 3. Submandibular swelling seen preoperatively in case 1

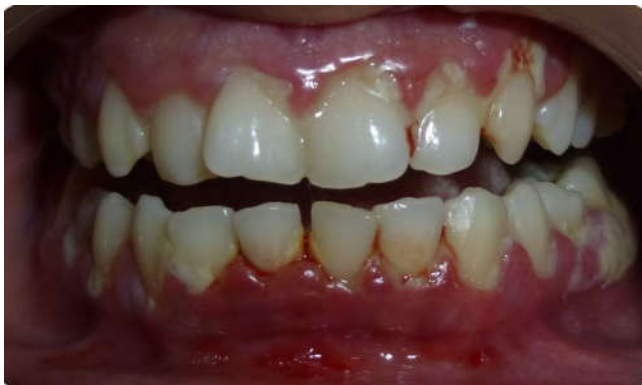

Figure 1A. Preoperative view of case 1 showing pseudomembrane

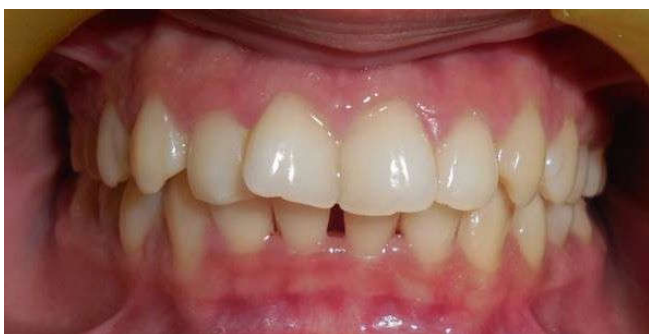

Figure 1B. Postoperative view of case 1 showing complete healing

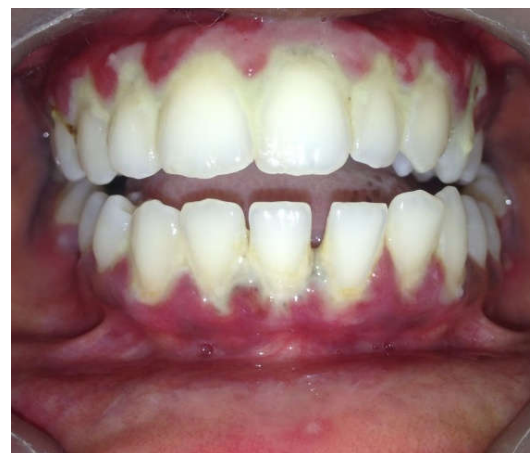

Figure 4A. Preoperative view showing pseudomembrane formation in case 2

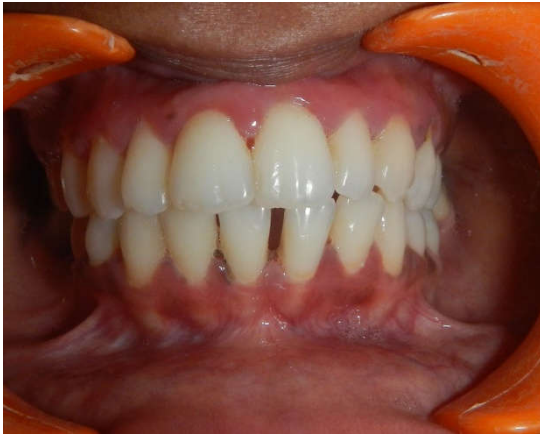

Figure 4B. Postoperative view showing complete healing in case 2

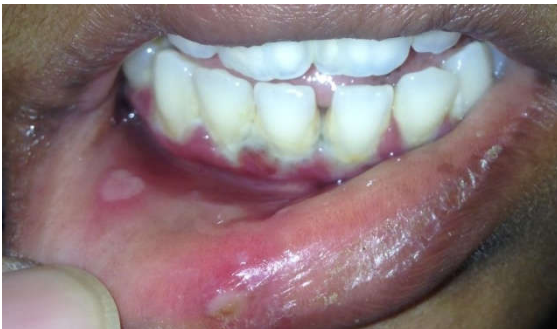

Figure 5. Ulcer present on the vermillion border of the lower lip in case 2

## DISCUSSION

Early reports on the treatment of ANUG focused on management of the microbial aspects of the disease with available antimicrobial and chemical agents. Initially, arsenicals were used because of their effectiveness against spirochetes associated with venereal disease. Vincent employed topical iodine applications and rinses of boric acid solution. In the first two decades of this century, oxidizing agents, especially chromic acid, were a popular mode of therapy, since the involved microorganisms are anaerobic. Mercury, silver compounds, and aniline dyes were also used. In 1949, Schluger<sup>3</sup> (Schluger, 1949) reported treatment of his patients by deep and thorough curettage, followed by hydrogen peroxide and water rinses six to eight times a day. However, because of the preconceived notions of potential bacteraemia and spread of infection, scaling and root planning did not gain wide acceptance by the profession as a treatment of choice for ANUG. In fact, in 1944, Fish recommended resting the tissues beneath periodontal dressings and, as late as 1950 by Miller in his text. In the early 1960s, Fitch<sup>4</sup> suggested that ultrasonic instrumentation was effective in managing ANUG. Goldhaber, in 1968, proposed repeated gentle scaling, diluted hydrogen peroxide rinses, and establishment of good oral hygiene programs. He stated that "the more meticulous and complete the subgingival curettage, the more complete will be the response, side effects from the use of topical metronidazole include the occurrence of black tongue, generalized erythema, and thrush. Generally, the topical mode of antibiotic therapy is not recommended because of the increased risk of sensitivity and potential development of resistant strains in the normal oral flora. Shapiro has proposed a technique, developed by Kramer, which uses periodic curettage to stimulate regeneration of the

interdental papillae to eliminate or lessen the need for surgical intervention.

ANUG can cause tissue destruction involving the supporting structures. It usually runs an acute course and therefore the term acuteis often included in the diagnosis. When bone loss occurs the condition is called necrotizing ulcerative periodontitis. If left untreated infection reaches into systemic circulation, and may spread to other parts of the body. In the present case report we have discussed the pre-treatment and post treatment clinical picture of ANUG and its management. The local debridement and proper oral hygiene practice with antibiotic coverage healed the lesion considerably. Patient were relieved from pain, swollen gingiva and fetid odour completely with this initial approach. This conservative mode of treatment is reliable method for treating ANUG. The main predisposing factors in our cases were hormonal imbalance in pregnancy and stress<sup>5</sup> probably because of her husband's unemployment. During pregnancy progesterone and oestrogen levels are increased, and by the end of the third trimester they increases upto 10 to 30 times the levels during the menstrual cycle. In pregnancy there are changes in vascular permeability, gingival edema and an increased inflammatory response to dental plaque. (Carranza's Clinical Periodontology 11<sup>th</sup> Edition) In our first case, effect of pregnancy on gingival tissues may be recognized as early as the second month of gestation and gingival inflammation increases to maximum severity in the eighth month. During the last month, a sudden and definite improvement occurs.

A bacterial smear is not necessary because bacterial picture is not apparently different from marginal gingivitis or periodontal pocket. Study did not reveal any elevated risk of congenital abnormalities, preterm delivery or low birth weight among women exposed to Metronidazole. The non teratogenic effect is difficult to prove but existing data indicates no major risk and no indication for termination of pregnancy (Safety of metronidazole during pregnancy, a cohort study of risk of congenital abnormalities, preterm delivery and low birth weight in 124 women, 1999). Metronidazole still remains the gold therapy for ANUG. Proper counselling by the Gynecologist is important. There should be an interdisciplinary approach between the Gynecologist and the Periodontist. Most cases of necrotizing stomatitis reported in the literature are associated with systemic factors such as AIDS, chemotherapy or tumor growth. In contrast, the presenting patients did not have any significant systemic disease or treatment that could be associated with the disease. Horning and Cohendescribed seven stages of necrotizing periodontal disease according to the oral regions affected, ranging from necrosis of the tip of the papilla (stage 1) to necrosis that perforates the skin of the cheek (stage 7) (Horning and Cohen, 1995). This classification accords with the general view that this disease advances in a vestibular direction. The present case 1 could be considered to be stage 5 of Horning and Cohen (necrotizing stomatitis) because they showed a palatine progression and even approached the midline, where the palatal masticatory mucosa is affected instead of vestibular alveolar mucosa. However, unlike in other published cases no bone destruction was observed clinically in either patient; this is notable because bone destruction is expected in necrotizing stomatitis, which is considered to be a progression of necrotizing periodontitis. Our present cases showed similar symptoms as observed in necrotizing stomatitis that is, intense, disabling pain that makes food or liquid intake difficult and becomes extreme during periodontal probing or

scaling and root planning procedures (Holmstrup, 2015). Due to the impossibility of mechanical debridement because of the pain, we adopted a more conservative approach in both cases, with the application of hydrogen peroxide and prescription of oral rinses of chlorhexidine to prevent plaque formation over the debrided lesions. We also prescribed antibiotics and anti-inflammatory drugs metronidazole, which is considered the first choice antibiotic in these cases. Amoxicillin/clavulanic acid is a broad-spectrum antibiotic that is also effective in necrotizing periodontal diseases, which have a great variety of microbial species involved in their etiology (Ramos *et al.*, 2012). Both patients showed an excellent response within 48 hours of treatment.

### Summary

Interdental craters that result from ANUG can be permanently disfiguring, especially in the anterior gingiva. Therapeutic mode involving nonsurgical treatment—periodic scaling and root planing combined with daily rinses with chlorhexidine—is prescribed. Satisfactory results can often be achieved using this conservative approach to therapy. A multidisciplinary approach also plays an important role.

### REFERENCES

Barnes GP, Bowles WF, Carter HG. 1973. Acute necrotizing ulcerative gingivitis: A survey of 218 cases. *Periodomol.*, 44:35-2.

- Carranza's Clinical Periodontology, 11<sup>th</sup> Edition.  
 Fitch HB, Bethart H. and Ailing CC. 1963. Necrotizing ulcerative gingivitis. *J Periodontol.*, 34:42.  
 Holmstrup P. 2015. Necrotizing periodontal disease. In: Lindhe J, Lang NP, editors. Clinical periodontology and implant dentistry. 6th ed. Oxford: Wiley-Blackwell.  
 Horning GM. and Cohen ME. 1995. Necrotizing ulcerative gingivitis, periodontitis, and stomatitis: clinical staging and predisposing factors. *J Periodontol.*, 66:990-8.  
 Miller SC. 1950. Textbook of Periodontia, Edition 3. Philadelphia, The Blakiston Co, p 484.  
 Ramos MP, Ferreira SM, Silva-Boghossian CM, Souto R, Colombo AP, Noce CW, *et al.* 2012. Necrotizing periodontal diseases in HIV-infected Brazilian patients: a clinical and microbiologic descriptive study. *Quintessence Int.*, 43:71-82.  
 Safety of metronidazole during pregnancy, a cohort study of risk of congenital abnormalities, preterm delivery and low birth weight in 124 women. *Journal of Antimicrobial Chemotherapy*, 1999; 44: 847-855.  
 Schluger, S. 1949. Necrotizing ulcerative gingivitis in the army. Incidence, communicability and treatment. *Journal American Dental Association*, 38:174-183.  
 Schoor RS. and Havrilla, J. 1586. Acute necrotizing ulcerative gingivitis: etiology and stress relationships. *Int J Psychowm*, 33-35.

\*\*\*\*\*