



ISSN: 0975-833X

Available online at <http://www.journalcra.com>

International Journal of Current Research
Vol. 9, Issue, 10, pp.59345-59347, October, 2017

INTERNATIONAL JOURNAL
OF CURRENT RESEARCH

RESEARCH ARTICLE

COMPUTED TOMOGRAPHIC STUDY ON PATTERNS OF FRONTAL SINUS

*¹Sushma, ²Dr. Sandhya Rani and ³Dr. Rajitha, P.

¹Gandhi Medical College and Hospital, India

²Oral and Maxillofacial Surgery (Dentistry), India

³Conservative Dentistry and Endodontics, India

ARTICLE INFO

Article History:

Received 20th July, 2017

Received in revised form

18th August, 2017

Accepted 27th September, 2017

Published online 31st October, 2017

Key words:

Frontal sinus,
Superciliary arches,
Patterns, CTscan,
Measurements.

ABSTRACT

Frontal sinuses are paired lobulated cavities located posterior to the superciliary arches in the frontal bone and each frontal sinus opens in to the corresponding middle meatus via the infundibulum.

Aims and objectives: The aim of this study was to determine the sizes and patterns of frontal sinus in both genders which can be used for personal identification.

Materials and methods: This study was conducted retrospectively on the paranasal CT scans of 2 mm thickness in the axial and coronal planes of 60 cases (30 male and 30 female) taken by a Siemens Emotion Tomography Machine in the Gandhi medical college and Hospital. The mean age range of the cases was 20- 67. All evaluations and measurements were done together by two radiologists. The measurements of widths, heights and total width of the two sinuses were performed on coronal plane. Antero posterior length was measured on axial plane. Measurements of both sides were compared with each other for total population and each gender. Cases were divided in to 2 subgroups according to age as 20- 40, 40-70 for each gender and each measurement parameter was also compared among the subgroups.

Results: Bilateral absence of frontal sinus was observed in one case (female). There were four cases with unilateral absence of frontal sinus. The values of the measurements were higher for male in elderly age group (40-70) and also in young age group except height (left and right) and length (right). In males, anteroposterior length on left side is significantly higher ($p < 0.05$). In females, height on left side and anteroposterior length on right side is highly significant. ($p < 0.05$).

Copyright©2017, Sushma et al. This is an open access article distributed under the Creative Commons Attribution License, which permits unrestricted use, distribution, and reproduction in any medium, provided the original work is properly cited.

Citation: Sushma, Dr. Sandhya Rani and Dr. Rajitha, P. 2017. "Computed tomographic study on patterns of frontal sinus", *International Journal of Current Research*, 9, (10), 59345-59347.

INTRODUCTION

The frontal sinus is a triangular, pyramid-shaped (its apex is superior and its base is inferior) cavity extending between the anterior and posterior tables of the ascending portion of the frontal bone. Frontal sinuses are paired lobulated cavities located posterior to the superciliary arches in the frontal bone and each frontal sinus opens in to the corresponding middle meatus via the infundibulum (Susan Standring, 2005 and Moore, 1992). They make an important contribution to normal forehead and glabellar contour. Frontal sinus is not apparent at birth and development begins during the second year of life, rarely visible on radiographs earlier than the second year of life. The sinus invades the frontal bone by about 5 years of age and slowly grows to reach an adult size in late adolescence. The development of the frontal sinus is complete by about 20 years of age and remains stable until further enlargement of the

chambers can occur from bone resorption during the advanced ages. Sinus radiography has been used for identification of remains and determination of sex and race (Igbigbi, 2003). Computerized tomography is a significant advance in radiology and it is becoming increasingly available and replacing gradually the conventional radiographs.

Aim

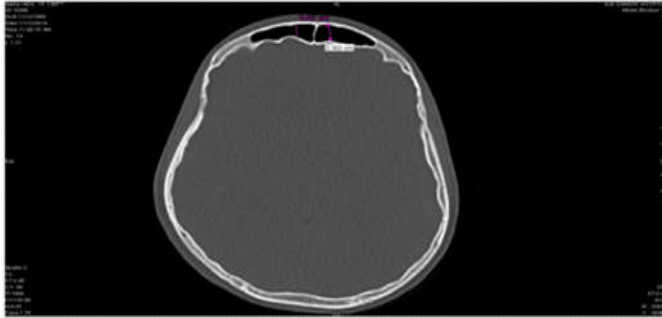
The aim of this study was to determine the sizes of frontal sinus in both genders which can be used for personal identification.

MATERIALS AND METHODS

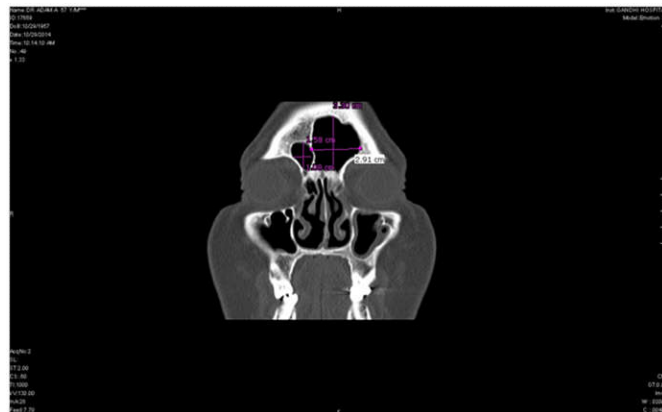
This study was conducted retrospectively on the paranasal CT scans of 2 mm thickness in the axial and coronal planes of 60 cases (30 male and 30 female) taken by a Siemens Emotion Tomography Machine in the Gandhi medical college and Hospital. No apparent sinonasal pathology was present in the CT scans used for the study. The mean age range of the cases

*Corresponding author: Sushma,
Gandhi Medical College and Hospital, India

was 20- 67. All evaluations and measurements were done together by two radiologists. Any visible pneumatization was accepted as presence of the sinus. The measurements of widths, heights and total width of the two sinuses were performed on coronal plane. Antero posterior length was measured on axial plane. All measurements were done from the CT sections which had highest values. The measurements were presented in centimeter. Measurements were determined for total population and each gender. Measurements of both sides were compared with each other for total population and each gender. Cases were divided in to 2 subgroups according to age as 20- 40, 40-70 for each gender and each measurement parameter was also compared among the subgroups.



Measurements on axial plane



Measurements on coronal plane

RESULTS

Bilateral absence of frontal sinus was observed in one case (female). There were four cases with unilateral absence of frontal sinus (two male and two female) and three of them at the right and one of them at the left side. Left dominant asymmetry noted in 3 female and 5 male and right dominant asymmetry noted in 11 individuals (5 females and 6 males).

The values of the measurements were higher for male in elderly age group (40-70) and also in young age group except height (left and right) and length (right). Among the subgroups in female population the highest values were always observed in the 20-40 age groups in all measurements. In male population the highest values were observed in the 20-40 age groups except the height and length of the right frontal sinus.

Measurements were evaluated for each gender at right and left sides and they were different in the favor of the left sides for both genders. In males, anteroposterior length on left side is significantly higher ($p < 0.05$). In females, height on left side and anteroposterior length on right side is highly significant

($p < 0.05$). In males height on right side and anteroposterior length on left side is significant.

Frontal sinus patterns

Table 1. Comparison of different patterns in both groups

Classification	No. of individuals		Percentage
	Males	Females	
Symmetry total	36	32	68
Asymmetry			27
Right	6	8	
Left	7	6	
Total	27	6	
Aplasia bilateral	1	1	5
Aplasia unilateral	2	1	

Table 2. Comparison in different age groups

PATTERNS	GROUPS			
	1		2	
	N	%	N	%
Bilateral Aplasia	1	3.3%	0	.0%
Bilateral Symmetric	19	63.3%	17	56.7%
Left Aplasia	0	.0%	1	3.3%
Left Dominant Asymmetry	3	10.0%	5	16.7%
Right Aplasia	2	6.7%	1	3.3%
Right Dominant Asymmetry	5	16.7%	6	20.0%

Table 1. Mean of measurements in total population

PATTERNS	AGE GROUP			
	20-40		40-70	
	N	%	N	%
Bilateral Aplasia	0	.0%	1	3.3%
Bilateral Symmetric	18	60.0%	18	60.0%
Left Aplasia	0	.0%	1	3.3%
Left Dominant Asymmetry	5	16.7%	3	10.0%
Right Aplasia	2	6.7%	1	3.3%
Right Dominant Asymmetry	5	16.7%	6	20.0%

Age group	Dimension	Side	Group				p-value
			1		2		
			Mean	SD	Mean	SD	
20-40	Width	Right	2.68	.85	2.68	1.10	0.093; NS
		Left	2.73	.78	2.93	.98	0.073; NS
	Height	Right	2.19	1.07	1.91	.96	0.063; NS
		Left	2.37	1.05	2.19	.84	0.038; Sig
40-70	Length	Right	1.12	.70	1.00	.33	0.043; Sig
		Left	1.10	.33	1.13	.24	0.032; Sig
	Width	Right	2.10	.99	2.65	.48	0.934; NS
		Left	2.18	.82	2.32	.94	0.096; NS
Height	Right	1.54	.73	2.12	.52	0.466; NS	
	Left	1.68	.60	1.83	.69	0.215; NS	
Length	Right	.70	.34	1.03	.26	0.783; NS	
	Left	.83	.32	.91	.35	0.053; NS	

DISCUSSION

Bilateral absence of frontal sinus observed in one female in the present study. Frequencies of bilateral absence of frontal sinus in several population were reported as follows: Japanese, 4.8 % in males ; Alaskan Eskimo, 25 % in males and 36 % in females ; Canadian Eskimo, 43% in males and 40 % in females ; Buschman, 11 % in males and 11 % in females ; Awarisch, 8 % in males and 13 % in females ; Austrian, 10 % in males and 10 % in females ; Germans, 3.4 % : Turkish, 2.6 % in males and 5.1 % in females (Aydinlioglu, 2003).

It is known that genetic and environmental factors control the configuration of the frontal sinus within each population and differences among the frequencies could be explained with regional differences. There were four cases with unilateral absence of frontal sinus (two male and two female) in the present study. Frequencies of unilateral absence of frontal sinus in several reports were as Japanese, 14.3 % in males and 7.1 % in females; Germans, 3.6 % in males and 2.8 % in females; Turkish, 3.8 % in males and 5.9 % in females. Although not always statistically significant, frontal sinus was generally larger in males than females in previous studies except for Canadian Eskimo population whose age ranged from 25 to 50 years. The radiographs were recorded using a KODAK 8000 C machine and Dental Imaging Software 6.3.4. Frontal sinus and Nasal septum patterns were observed and classified. It made use of two patterns which could be covered in one radiograph. When combined usage of both frontal sinus and nasal septum patterns were assessed, they obtained 41 unique combinations, and nine individuals whose patterns matched one of the patterns of 41 individuals. Thus authors observed that frontal sinus and nasal septum patterns had considerable individual variations. They also observed frontal sinus symmetry in 29 individuals (58%) and asymmetry in 16(32%), absent in 2 individuals (4%) and unilateral aplasia in 3 individuals (6%) (David, 2010). In another study conducted by neha patil *etal* using Waters radiographs of 100 individuals, observed that the overall percentage of bilateral frontal sinus absence was 1% (1 person, female), and the bilateral frontal sinus presence was 96% (96 persons).

In 3% of the cases (all three females), there was unilateral absence. Amongst the three, the left frontal sinus was absent in one case and the right was absent in the other two (Neha Patil, 2015), whereas in present case bilateral absence noted in one female patient. In a study conducted by vidya cs *etal* 50 macerated skulls (Males=28, Females=22) of age group 40-60 yrs are cleaned and subjected to 3D axial multislider CT scan. Axial and coronal images of slice thickness of 4mm were obtained. Frontal sinus (symmetry and lobulations) were observed and classified. Frontal sinus symmetry was observed in 34 (68%) individuals, asymmetry in 15 (30%) individuals and frontal sinus was absent in 1(2%) (Dr Vidya, 2014). In another study Postmortem skull radiographs were collected in 209 forensic autopsy and 163. Clinical cases. In total cases, a combined use of the nasal septum deviation patterns (straight, left, right, sigmoid, reverse sigmoid and rare types) and the frontal sinus patterns (aplasia, symmetry, left or right dominant asymmetry in combination with the number of lobulations) achieved a classification of at least 204 different types (incidence up to 5%).

Comparison of the ante- and postmortem films (n=24) gave an identical result in about 75%. The cases of inconsistency suggested the influences of the positioning in radiographic examination, the quality of radiographs and the complicated structures of the nasal septum and frontal sinus as possible causes of missing identity (Marl taniguchi, 2003).

Conclusion

Proper understanding of variations in the anatomy of frontal sinus helps the surgeon to avoid unnecessary complications during surgical procedures involving the frontal sinus and skull base. Finally we could conclude that use of frontal sinus patterns, as seen on; CT Images could be used as one of the aids for personal identification. It could be adjunct to other methods of personal identification.

REFERENCES

- Aydinlioglu, A, Kavakli A, Erdem S. 2003. Absence of frontal sinus in Turkish individuals. *Yonsei Med J.* 44 (2), 215- 8.
- David MP, Saxena R. 2010. Use of Frontal Sinus and Nasal septum patterns as an aid in personal identification: A digital radiographic pilot study. *J Forensic Den Sci.* July; 2(2):77-80.
- Dr. Vidya, C. S., Dr. Shamasundar, N.M. 2014. Computer tomographic study of frontal sinus patterns in skulls of south Indian population *International Journal of Scientific and Research Publications*, Volume 4, Issue 9, September 4 ISSN 2250-3153.
- Igbigbi PS, Nanono-Igbigbi AM. Determination of sex and race from the subpubic angle in Ugandan subjects. *Am J Forensic Med Pathol.*, 24: 168-72.
- Marl taniguchi, 2003. Shigeki sakoda, possible Use of Nasal Septum and Frontal Sinus Patterns to Radiographic Identification of Unknown Human Remains Osaka City *Med. J.* Vol. 49, 31-38.
- Moore, K. L., 1992. Clinically oriented anatomy, third ed., Williams & Wilkins, Baltimore, pp. 760- 762.
- Neha Patil, Freny R. Karjodkar 2012. Uniqueness of radiographic patterns of the frontal sinus for personal identification *Imaging Science in Dentistry.*, 42 : 213-7.
- Susan Standing (Ed.), 2005. Gray's Anatomy, 39th ed., Elsevier Churchill Livingstone, Spain, 2 pp. 575- 576.
