



## RESEARCH ARTICLE

### ATTEMPTED REMOVAL OF FOREIGN BODY EYE BY TRADITIONAL METHOD GONE WRONG – BRASSICA JUNCEA SEEDS

\*Anchit Wapa and Anu Namgyal

MS Ophthalmology, Regional Hospital, Kullu, Himachal Pradesh - 175131, India

#### ARTICLE INFO

##### Article History:

Received 14<sup>th</sup> December, 2017  
Received in revised form  
20<sup>th</sup> January, 2018  
Accepted 03<sup>rd</sup> February, 2018  
Published online 28<sup>th</sup> March, 2018

##### Key words:

Intra Ocular foreign Body, Brassica  
Junceaseeds, Conjunctival Chemosis.

**Copyright** © 2018, Anchit Wapa and Anu Namgyal. This is an open access article distributed under the Creative Commons Attribution License, which permits unrestricted use, distribution, and reproduction in any medium, provided the original work is properly cited.

**Citation:** Anchit Wapa and Anu Namgyal. 2018. "Attempted removal of foreign body eye by traditional method gone wrong – brassica juncea seeds", *International Journal of Current Research*, 10, (03), 66572-66573.

#### ABSTRACT

Brassica juncea, commonly known as Indian mustard is a species of mustard plant (Brassica juncea, 1992). Powdered seeds mixed with castor oil is used as a soothing agent for application on burns, itch and insect bites; oil is used for massage in fever, insomnia, headache, lethargy, chest and back pain. The cooked leaves are eaten as vegetables to improve appetite (Singh, 1986). Presenting a peculiar case where a woman inserted mustard seeds in her eye as a traditional method to remove foreign body from eye leading to multiple foreign bodies embedded in eye. This is the first ever case reported of such type.

## INTRODUCTION

Brassica juncea, commonly known as Indian mustard is a species of mustard plant (Brassica juncea, 1992). Powdered seeds mixed with castor oil is used as a soothing agent for application on burns, itch and insect bites; oil is used for massage in fever, insomnia, headache, lethargy, chest and back pain. The cooked leaves are eaten as vegetables to improve appetite (Singh, 1986). Presenting a peculiar case where a woman inserted mustard seeds in her eye as a traditional method to remove foreign body from eye leading to multiple foreign bodies embedded in eye. This is the first ever case reported of such type.

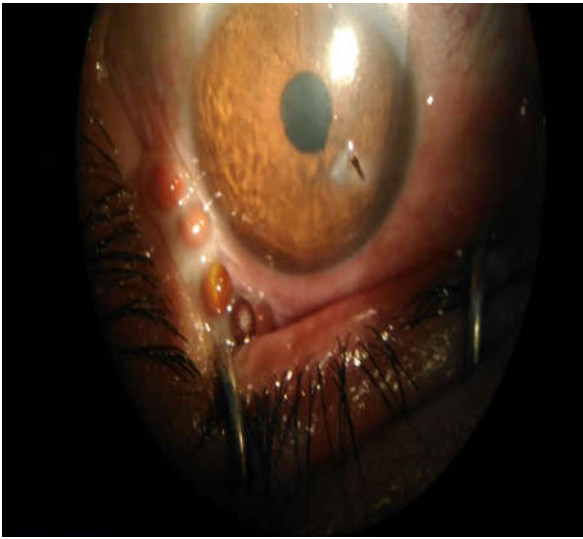
### Case Report

A 35-year-old woman presented to the emergency department of a hospital in North India with complaints of wooden foreign body (thorn) in her right eye 2 days back for which she was advised by her mother in law to insert the seeds of brassica juncea (mustard seeds) as a traditional mean to remove the foreign body from her eye. Following which she had developed severe irritation, pain, watering and foreign body sensation in her right eye. On examination the unaided visual acuity of the right eye was found to be 6/9. There was chemosis of the bulbar conjunctiva.


\*Corresponding author: Anchit Wapa,  
MS Ophthalmology, Regional Hospital, Kullu, Himachal Pradesh -  
175131, India.

The cornea showed a wooden foreign body 2-3mm, embedded transversely, deep stromal almost reaching the endothelial layer, at a position 2mm away from 4 clock limbal area, away from the pupillary area with just a tip visible in superficial corneal surface. The anterior chamber was quiet, pupil normally reactive, and fundus normal on direct ophthalmoscopy. Xylocaine 4% was instilled in the right eye and the eye speculum was applied, after which 2 round foreign bodies in form of seeds of brassica juncea were found in the lower fornix. On further exploring four seeds were also found in the superior fornix (Fig. 1 and Fig. 2). After removal of these mustard seeds and proper irrigation of the eye, the wooden foreign body removal was attempted in the opd under slit lamp. The patient was admitted to the ophthalmology department and was started on topical moxifloxacin and natamycin hourly drops and cyclopentolate tid. The mustard seeds (6 in number) and a wooden foreign body approximately 2\*1 cm was removed from the cornea. On subsequent follow-up, the conjunctival chemosis resolved and the cornea infiltration was contained (Fig. 3). Conjunctival swabs were sterile, and the patient was discharged from the hospital with the advice to put eye drops and follow up after 7 days. The patient was non-compliant and after 2 weeks of discharge she came for follow up when the chemosis had decreased, vision was 6/9, the anterior chamber was silent but synechiae had formed between the iris and the anterior lens surface at 5 o'clock and corneal infiltration and opacification remained at the entry point. She was advised topical antifungal (natamycin)

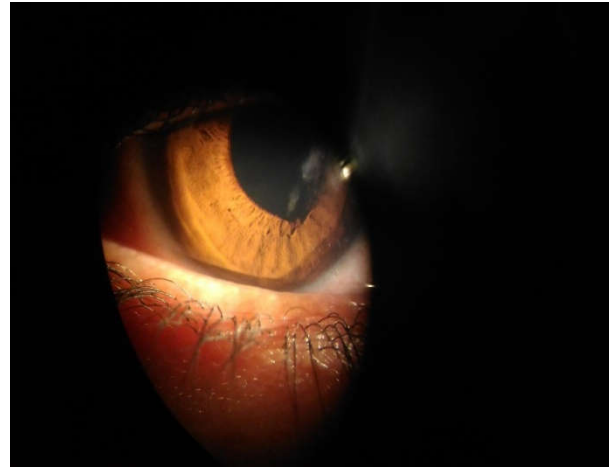and moxifloxacin again along with lubricant eye drops. The vision remained 6/9 R/E and the patient was symptomatically better.



**Figure 1.** Four mustard seeds embedded in superior fornix of right eye



**Figure 2.** Mustard seeds removed from right eye – Total six in number



**Figure 3.** Follow up

## DISCUSSION

As India is an agricultural country, we often come across the cases of perforating injuries with intraocular foreign body which may lead to partial visual loss to complete blindness. The common type of foreign bodies leading to perforation are thorns, twigs, metallic and non-metallic etc. Out of these twigs and thorns usually lead to perforation causing infection (Agrawal, 1980). In the case report that we have presented we can see how ignorance can lead to severe consequences. The patient inserted a foreign body to get rid of a foreign body, hence causing more damage to the eye. Moreover, she was non-compliant which hindered her recovery.

**DISCLOSURE:** The authors report no conflicts of interest in this work.

**ETHICAL STATEMENT:** Written consent has been obtained from patient.

**FUNDING:** Nil

## REFERENCES

- Alam, M., Ahmad, H., Quazi, M.H. and Khawaja, H.I.T. 1992. Cross compatibility studies with in the genus Brassica 1. Amphidiploid combinations, Sci. kyber 5. 89-92
- Singh YN. 1986. Traditional medicine in Fiji: some herbal folk cures used by Fiji Indians. *J. Ethnopharmacol.* Jan; 15(1):57-88.
- Agrawal R L, Agrawal J, Bhasin S, Nagar C K. 1980. Intraocular foreign body. *Indian J Ophthalmol.*, 28:151-4

\*\*\*\*\*