



RESEARCH ARTICLE

A RARE CASE OF MULLERIAN DUCT ANOMALY KNOWN AS UTERUS DIDELPHYS WITH SPONTANEOUS CONCEPTION AND A TERM PREGNANCY ON LEFT HORN

^{1,*}Karnel Singh and ²Ong Tjandra

¹General Practitioner of Sehati Specialist Clinic

²Consultant Department Gynecology Oncology of Bethsaida Hospital, Tangerang-Indonesia

ARTICLE INFO

Article History:

Received 30th June, 2018
Received in revised form
21st July, 2018
Accepted 25th August, 2018
Published online 30th September, 2018

Key Words:

Fertility, Herlyn-Werner-Syndrome,
Uterus Didelphys.

Copyright © 2018, Karnel Singh and Ong Tjandra. This is an open access article distributed under the Creative Commons Attribution License, which permits unrestricted use, distribution, and reproduction in any medium, provided the original work is properly cited.

Citation: Karnel Singh and Ong Tjandra. 2018. "A rare case of mullerian duct anomaly known as uterus didelphys with spontaneous conception and a term pregnancy on left horn", *International Journal of Current Research*, 10, (09), 73408-73409.

ABSTRACT

Uterus Didelphys is known to be one of the rare Mullerian Duct anomaly where in its development the uterus fails to unite so that the uterus separates into 2 parts: right and left which also have cervix in each part. Pregnancy with uterus didelphys may occur without infertility therapy and able to maintain its pregnancy to term. We report a rare case of Mullerian Duct Anomaly known as uterus Didelphys with spontaneous conception and a term pregnancy on left horn.

INTRODUCTION

Mullerian duct anomaly is a congenital aberration that occurs in the female genital system that originates from abnormal development of the Mullerian ducts. This disorder is a uterine failure in developing, failing to unite, or failing to reabsorption, which normally occurs between weeks 6 and 22. Various sources estimate the incidence of these disorders that occur between 0.5 to 5% in the population as a whole. Septate uterus is the most frequent uterine abnormality with an average incidence of 35% followed by a 25% bicornuate uterus and a 20% arcuate uterus. Uterine abnormalities occur because of delays in natural conception in women especially in secondary infertile cases. Rates of uterine pregnancies on the uterus unikornu and uterus didelphys were detected at 45% and the rates of pregnancy in untheraped patients with bicornuate uterus and septate uterus were also low with the likelihood of a 40% in term pregnancy. The arcuate uterus has a slightly better pregnancy rate of 65%. The uterus didelphys is characterized as a complete failure of Mullerian duct to unite so that the uterine cavity is separated and has two cervices. The uterine longitudinal septum also varies from thin and easy to move up to thick and rigid. The initial suspicion of the condition is followed by a diagnosis that begins with a routine inspective examination in

which an anatomical abnormality is found and needs further examination. Furthermore, since Mullerian duct often develops and is associated with the Wolffii duct, abnormalities of the kidneys may be found along with the uterine abnormality that occurs.

MATERIALS AND METHODS

A 32-year-old woman did antenatal care in her second pregnancy. The woman has a regular menstruation history and no history of menstrual disorders. The spontaneous conception of each pregnancy and the first pregnancy occurs 1 month after her marriage. History of using condom contraception, lactation amenorrhea method, and periodic abstinence after her first pregnancy. There was no dyspareunia and no history of bleeding during pregnancy. The woman has a history of previous sectio caesarean. In TAUS examination, she has double uterus and cervix, single fetus, head presentation, fetal weight prediction 3290 grams, pregnancy is in the left uterus. Planned for sectio caesarean operation at 39 weeks' gestation. At the time of operation there are two separate uteruses in which each ovary is attached to each uterus. Pregnancy currently occurring in the left uterus is different from the previous pregnancy that occurs on the right side and also appears the sectio scar on the right uterus and was born a baby boy weighing 3200 grams, body length 49 cm, and APGAR score 9/10.

*Corresponding author: Karnel Singh

General Practitioner of Sehati Specialist Clinic

DOI: <https://doi.org/10.24941/ijcr.32095.09.2018>

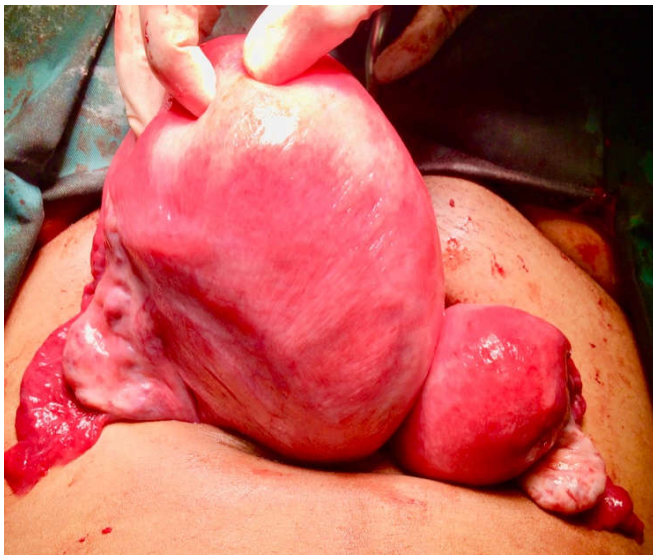


Figure 1. Uterus Didelphys, pregnancy on the left uterus

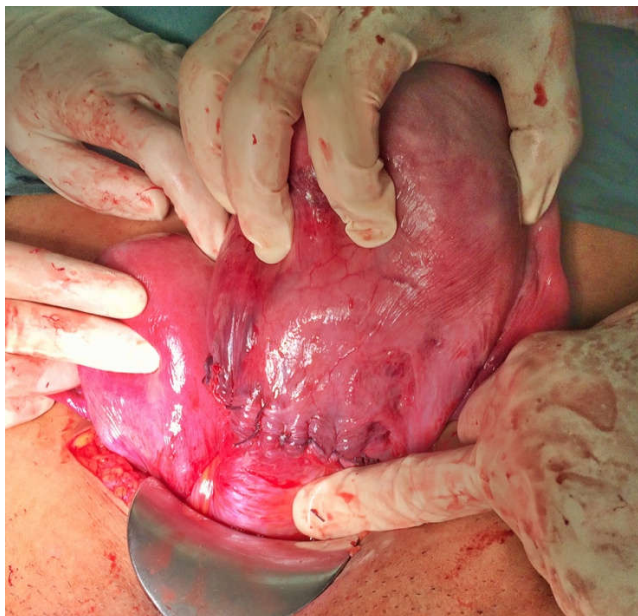


Figure 2. Caesarean scar on the right uterus and Polyglycolic Acid interrupted suture on low segment left uterus

DISCUSSION

In this case there is no infertility problem, the patient can quickly become pregnant and no problems occur in every pregnancy. The level of fertility of the untreated uterus didelphys is still higher when compared with other Mullerian duct deformities. There is also an increased risk of spontaneous abortion, fetal death, and prematurity with a 45% (or lower) percentage when compared with normal uterus, which is similar to a uterus unicornuate. This indicates that the ability to reproduce is still lacking, but is still better than that of the uterus septate or uterus bicornuate which is also common among other Mullerian duct anomalies. Another study conducted by Ludmir et al. also found that with obstetric intervention, many pregnancies of woman with the uterus didelphys were detected to reach aterm gestational age and the fetal survival rate was higher than that of the uterus bicornuate and uterus septate. Furthermore, it has been reported that there was a woman with uterus didelphys who was pregnant twins or

triplets in which this shows an ability to conceive and maintain a healthy pregnancy in each of the uterus. In contrast a larger retrospective study was conducted by Raga et al which found the incidence of the Mullerian duct anomaly was significantly higher in infertile women than in fertile women, which indicated an association between infertility and Mullerian duct disorder. Uterus didelphys have been reported as part of a more specific syndrome called the Herlyn-Werner-Wunderlich (HWW) Syndrome. It is a very rare congenital anomaly of the urogenital tract which involves the structure of the duct of Mullerian and Wolfian and this is characterized by 3 features, namely: uterus didelphys, hemivaginal obstruction, and ipsilateral renal agenesis. The didelphys uterus is an extremely rare anomaly with reproductive features and varied pregnancy when compared with other abnormalities. The relationship between didelphys and infertility is still debated

Conclusion

Uterus didelphys is not a condition indicated for caesarean unless a thick and rigid vaginal septum is found which increases the risk of dystocia. When uterus didelphys is found it should also be done an examination on the renal to find out the existence of Herlyn-Werner-Wunderlich (HWW) syndrome Overall, the availability of literature on uterus didelphys is still limited. Therefore more studies are needed on reproductive and pregnancy images, so clinicians can adequately advise and care for their patients.

Conflict of Interest: None of the authors have affiliations with or involvement in any organization or entity with any financial interest or nonfinancial interest in the subject matter or materials discussed in this study

REFERENCES

- Acien. P. 1993. Reproductive performance of women with uterine malformations. *Human Reproduction*, vol.8, no.1, pp.122-126.
- Grimbizis, G.F., Camus, M., Tarlatzis, B.C., Bontis, J.N. and Devroey, P. 2001. Clinical implications of uterine malformations and hysteroscopic treatments results, *Human Reproduction Update*, vol.7, no.2, pp.161-174.
- Heinonen, P.K 2000. Clinical implications of the didelphic uterus: long-term follow-up to 49 cases. *European Journal of Obstetrics and Gynaecology and Reproductive Biology*, vol.91, no.2, pp.183-190.
- Heinonen, P.K. 1984. Uterus Didelphys a report of 26 cases. *European Journal of Obstetrics and Gynaecology and Reproductive Biology*, vol.17, no.5, pp.345-355.
- Karaca, L., Pirimoglu, B., Bayraktutan, U., Ogul, H., Oral, A. and Kantarci, M. 2015. Herlyn-Werner-Wunderlich syndrome : a very rare urogenital anomaly in a teenage girl. *The Journal of Emergency Medicine*, vol.48, no.3, pp.e73-e75.
- Ludmir, J., Samuels, P., Brooks, S. and M.T. Mennuti. 1990. Pregnancy outcome of patient with uncorrected uterine anomalies managed in a high-risk obstetric setting. *Obstetric and Gynaecology*, vol.75, no.6, pp.906-910.
- Raga, F., Bauset, C., Remohi, J., Bonilla-Musoles, F., Simon, C. and Pellicer. A. 2000. Reproductive impact of congenital Mullerian anomalies, *Human Reproduction*, vol.12, no.10, pp. 2277-2281.