



ISSN: 0975-833X

Available online at <http://www.journalcra.com>

INTERNATIONAL JOURNAL  
OF CURRENT RESEARCH

International Journal of Current Research  
Vol. 10, Issue, 12, pp.75985-75988, December, 2018

DOI: <https://doi.org/10.24941/ijcr.32899.12.2018>

## RESEARCH ARTICLE

### A RARE VARIANT OF CAUDAL REGRESSION SYNDROME MIMICKING OHVIRA SYNDROME

<sup>1</sup>Dr. A. Madhu Mitha, <sup>2</sup>Dr. Rahul Manchanda, <sup>3</sup>Dr. P. P. Singh, <sup>4</sup>Dr. Jagdeep Balyan,  
<sup>4</sup>Dr. Amit Singh Malhotra and <sup>5</sup>Dr. Preeti Yadav

<sup>1</sup>Fellow, Gynae Endoscopy Unit, PSRI Hospital, New Delhi

<sup>2</sup>HOD, Gynae Endoscopy Unit, PSRI Hospital, New Delhi

<sup>3</sup>HOD, Department of Urology and Kidney Transplant, PSRI hospital, New Delhi

<sup>4</sup>Senior Consultant, Department of Urology and Kidney Transplant, PSRI hospital, New Delhi

<sup>5</sup>Fellow, Gynae Endoscopy Unit, PSRI Hospital, New Delhi

#### ARTICLE INFO

##### Article History:

Received 16<sup>th</sup> September, 2018

Received in revised form

04<sup>th</sup> October, 2018

Accepted 21<sup>st</sup> November, 2018

Published online 29<sup>th</sup> December, 2018

##### Key Words:

Caudal regression syndrome,  
OHVIRA syndrome.

#### ABSTRACT

Obstructed hemivagina and ipsilateral renal agenesis (OHVIRA), or Herlyn-Werner-Wunderlich syndrome (HWWS), is a rare congenital müllerian and mesonephric anomalies presenting with a characteristic triad of uterine didelphys, unilateral obstructed hemivagina, and ipsilateral renal agenesis. Suspicion and knowledge of this anomaly are essential for a precise diagnosis. Caudal regression syndrome (CRS) is characterized by a wide range of abnormalities including partial absence of sacrum or coccyx with no apparent associated anomalies to extensive deformity of the lower vertebrae, pelvis and fused lower limbs (sirenomelia). Herein we report a case of 16 year old girl, a case of CRS mimicking OHVIRA.

Copyright © 2018, A. Madhu Mitha et al. This is an open access article distributed under the Creative Commons Attribution License, which permits unrestricted use, distribution, and reproduction in any medium, provided the original work is properly cited.

Citation: Dr. A. Madhu Mitha, Dr. Rahul Manchanda, Dr. P. P. Singh, Dr. Jagdeep Balyan, Dr. Amit Singh Malhotra and Dr. Preeti Yadav. 2018. "A rare variant of caudal regression syndrome mimicking ohvira syndrome", *International Journal of Current Research*, 10, (12), 75985-75988.

#### INTRODUCTION

Obstructed hemivagina and ipsilateral renal agenesis (OHVIRA), or Herlyn-Werner-Wunderlich syndrome (HWWS), is a rare congenital müllerian and mesonephric anomalies presenting with a characteristic triad of uterine didelphys, unilateral obstructed hemivagina, and ipsilateral renal agenesis (Fertil Steril, 1988 and Vercellini, 2007). The exact incidence of OHVIRA syndrome is unknown, but according to the literature it is estimated to be around 0.1-3.5 % (Orazi, 2007 and Ahmad, 2013). The usual clinical presentations of this anomaly are dysmenorrhea, pelvic pain, and a mass per abdomen after menarche. Presence of such nonspecific symptoms causes a delay in the diagnosis of this condition which may lead to complications like pelvic endometriosis, pyohematocolpos, pyohematometra, pyosalpinx, pelvic adhesions and primary infertility (Epelman, 2013 and Aydin, 2014). Therefore, strong suspicion and knowledge of this anomaly are essential for a precise diagnosis. Caudal regression syndrome (CRS) is a rare congenital disorder with an estimated incidence of 0.1-0.25:10000 of normal pregnancies (Tortori-Donati, 1999) and is characterized by a wide range of abnormalities including

partial absence of sacrum or coccyx with no apparent associated anomalies to extensive deformity of the lower vertebrae, pelvis and fused lower limbs (sirenomelia). CRS may also be associated with other genitourinary abnormalities, cardiac and orthopaedic malformations in severe cases (Boulas, 2009). Herein we report a case of 16 year old girl, a case of CRS mimicking OHVIRA.

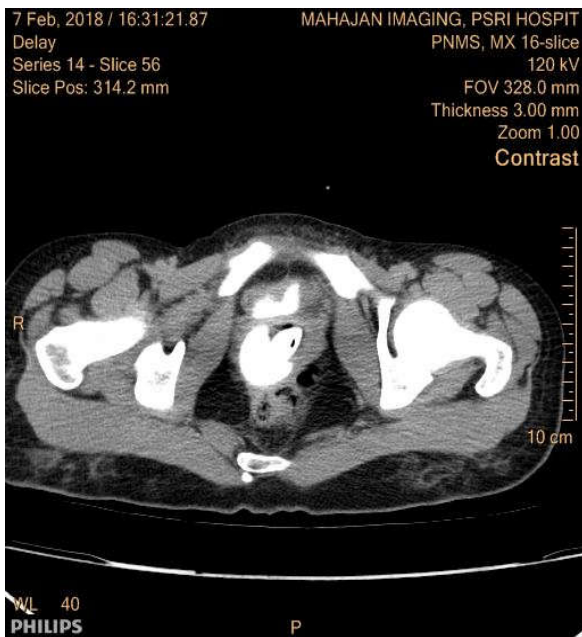
#### Case History

A 16 year old girl came with chief complaints of primary amenorrhoea and severe continuous lower abdomen pain. She is a diagnosed case of congenital hypospadias with the urethra opening in to the vagina and has a suprapubic catheter insitu for the same since birth. She has also undergone rectal pull up probably for imperforate anus when she was 2 years old (documented details of the same are not available) and currently having anal incontinence. On examination there was a irregularly enlarged tender abdominal mass of about 18 weeks size. Ultrasonography revealed left adnexal endometriosis cyst of size 10\*15cms and non visualisation of the uterus and left kidney. Contrast enhanced CT scan showed uterus didelphys with obstructed left hemi vagina and congenital absence of left kidney (OHVIRA)- suggestive of Herlyn Werner Wunderlich 's syndrome. Other findings were endometriotic cyst of size 10\*15cms and densely calcified area in the right hemivagina. MRI revealed vertebral segmentation

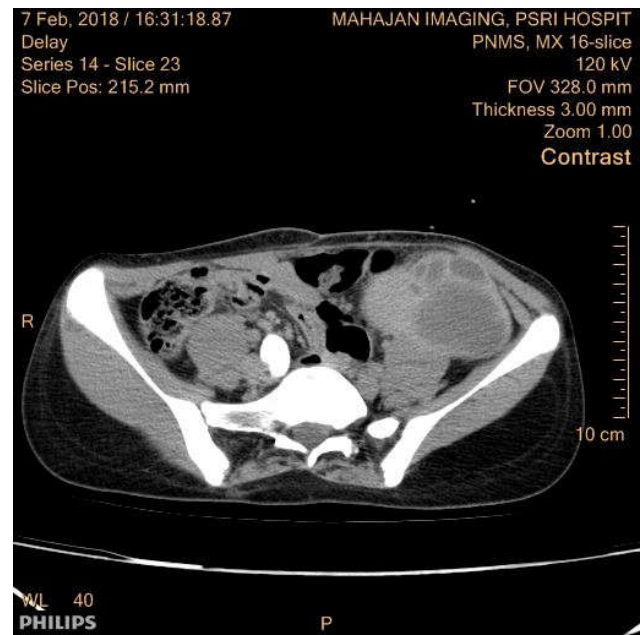
\*Corresponding author: Dr. A. Madhu Mitha

Fellow, Gynae Endoscopy Unit, PSRI Hospital, New Delhi

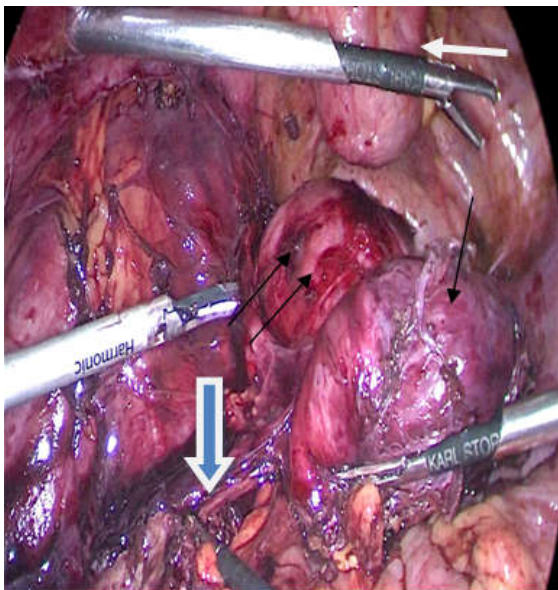
defects in the form of left sided hemivertebra at L5-S1 with absent coccyx thus falling in to the spectra of caudal regression syndrome.



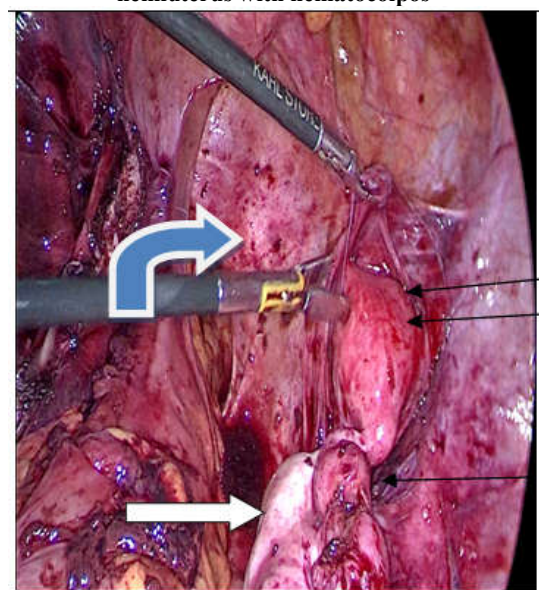
**Figure 1** shows the CT image of the patient. White arrow shows the bladder stone in the vagina Black arrow shows the vagina and the communication



**Figure 2.** Shows the CT image of the patient White single arrow shows the left hemiuterus with hematocolpos with left endometriotic cyst White double arrow shows the right hemiuterus with hematocolpos



**FIGURE 3.** shows the left hemiuterus with left endometriotic cyst. White arrow shows the bladder. Single black arrow shows the endometriotic cyst. Double arrow shows the left hemi uterus Blue arrow shows the bowel adherent to the endometriotic cyst



**Figure 4.** Shows the right hemiuterus with right tube and ovary. White arrow shows normal right ovary Single black arrow shows right tube with hematosalpinx Double arrow shows right hemiuterus Blue arrow shows vagina with the stone

On examination under anaesthesia, urethral opening was not found. A blind vaginal pouch with no cervical opening was seen. Cystoscopy was done through the suprapubic catheter opening which revealed communication of bladder with the vagina (hypospadias) and presence of 8 \*8 cms bladder stone in the vagina. The patient was planned for diagnostic laparoscopy and preoperative consent was taken for hysterectomy as well. On laparoscopy

- Left hemiuterus of size 10 \*15 cms adhered to the left tuboovarian mass of 15\*13 cms, chocolate coloured fluid (Figure 3)

Left hemihysterectomy with left side salpingoopherectomy and right hemihysterectomy with right side salpingectomy was done. On examining the specimen cervix was absent in both the hemi uterus and it was found to be noncanalised as well. HPE confirmed the operative findings and showed presence of active endometrium in both the hemi uterus. Cystoscopy was done and the presence of large calculus measuring 8\*8 cm in the vagina was confirmed. Laparoscopic extraction of the calculus done by incising and suturing back the posterior vaginal wall as shown in Figure 6.

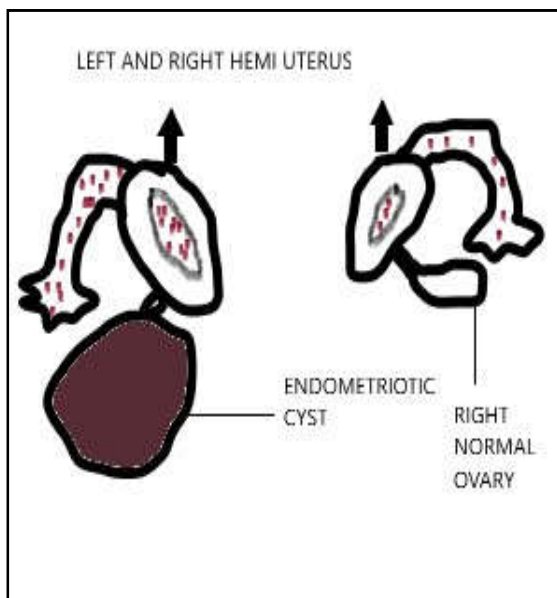


Figure 5. Diagrammatic representation of the mullerian anomaly present in the case

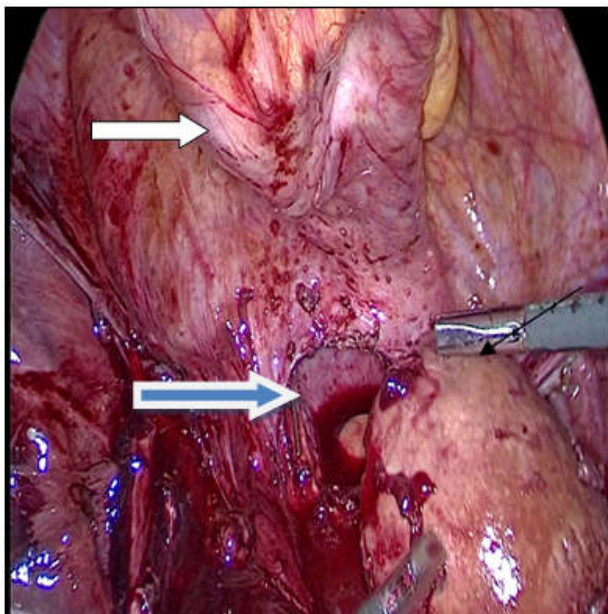


Figure 6. Shows the extraction of the bladder stone by incising the vagina. White arrow shows bladder Black arrow shows bladder stone Blue arrow shows vaginal wall incision

Future plan of management in our case

- Plan for closure of the communication between the bladder and the vagina.
- Creation of neovagina—vaginoplasty to facilitate sexual function in the future
- Plan for appendicovesiculostomy or any other urinary diversion procedures

## DISCUSSION

The embryopathogenesis of OHVIRA starts at around 8 weeks of gestation, simultaneously affecting both mullerian and metanephric ducts. An early failure of metanephric diverticulum to develop (around 5 weeks) from mesonephric duct results in agenesis of ureteric bud, which leads to agenesis of ipsilateral ureter and kidney, which in turn affects the position of ipsilateral mullerian duct.

Due to this failed positioning of paired paramesonephric duct, the two hemiuteri and hemicervices fail to unite, resulting in uterus didelphys. developmental arrest of ipsilateral mesonephric duct results in failure of distal hemivagina to develop, thereby resulting in obstructed hemivagina, all 3 components being secondary to mesonephric duct-induced müllerian anomalies (Bajaj, 2012). Haddad *et al.* (2013). studied the associations of blind hemivagina in 42 patients and found that it was associated with renal agenesis in almost all the patients. In addition, blind hemivagina with ipsilateral renal agenesis was generally associated with uterus didelphys; however, rare cases of septate uterus were also found. Whenever a genitourinary anomaly is suspected, an initial screening ultrasound of the pelvis and kidney, followed by MRI or computed tomography (CT) scan. However Laparoscopy is the gold standard diagnostic modality with the additional advantages of therapeutic drainage of hematocolpos/hematometra and vaginal septectomy. Vaginal septum excision is the treatment of choice for HWWS (Heinonen, 2000 and Sugiura-Ogasawara, 2013). Women with uterus didelphys have a high likelihood of becoming pregnant, with approximately 80% of patients able to conceive, but with elevated rates of premature delivery (22%) and abortion (74%) (Sugiura-Ogasawara, 2013 and Duhamel, 1961). CRS is usually sporadic. Though the exact aetiology is not known, Dunhamel (Becerra, 1990), postulated that it may occur due to deficiency or extrinsic insult to the caudal eminence. Table 1 shows the possible anomalies associated with CRS. Detailed clinical examination and radiological investigations are essential for proper management of condition. Myelography and CT myelography has been replaced by MRI as gold standard. as it can provide details of almost all the anatomical abnormalities associated with the condition.

S.NO	SYSTEM AFFECTED	DEFORMITY
1	Urology	Congenital hydronephrosis Hypospadias Cryptorchidism Duplication of collecting system Renal agenesis, renal ectopia Vesico-ureteral reflux
2	gastrointestinal system	imperforate anus, tracheo-oesophageal fistula, anorectal atresia, inguinal and umbilical hernias, Duodenal atresia malrotations and situs inversus.
3	neural tube abnormalities	tethered-cord, diastematomyelia, Hypoplastic anomalous distal cordlipomyelomeningocele and congenital narrow spinal tract
4	Orthopaedic deformities	dysplastic vertebrae, scoliosis, hip dislocation and contracture, knee flexion contracture accompanied by popliteal webbing, narrow pelvis, syringomyelia, club foot and frog leg.
5	Genital abnormality	In the male, the most common genital duct anomalies are hypospadias, bifid scrotum and epispadias, whereas in the female, paramesonephric (Mullerian) duct dysplasia gives rise to salpingo-ovarian aplasia, partial vaginal atresia, duplicated vagina, uterine didelphia, and bicornuate uterus.
6	Miscellaneous	Hydrocephalus, Strabismus Congenital heart disease

The syndrome occurs more frequently in the offspring of diabetic mothers. It has a varying clinical spectrum from being an incidental finding in MRI to morbid multiorgan anomalies. The patient reported in our study is diagnosed to have congenital hypospadias (urethra opening in to vagina) and

unilateral renal agenesis, she is yet to have urodynamic flow studies to diagnose neurogenic bladder. Therapeutic options such as the bladder training (if some detrusor function remains), intermittent catheterization, bladder trigonoplasty and urinary diversion with a vesicostomy or an ileal conduit may provide some amount of normalcy related to the bladder function. Imperforate anus which was present in our case, is always primarily repaired at birth either by colostomy or a pull-through procedure, but complete fecal continence is seldom achieved postoperatively. The unique and confusing factor in our case which has caused so much difficulty in preoperative diagnosis is its association with mullerian anomaly. Literature about association of CRS with mullerian anomaly is sparse. In our case preoperatively the patient was presumed to have uterine didelphys with obstructed hemivagina. Intraoperatively the patient was found to have left and right unfused hypoplastic hemiuterus without cervixes, with active endometrium and bilateral apparently normally formed tubes and ovaries. The preliminary step in the management of CRS should be an accurate prenatal diagnosis. Informations regarding the potential sequelae should be discussed with parents because of the wide spectrum of the associated anomalies and inaccuracy of the available prenatal diagnostic tests in predicting the same, once the diagnosis is made, Multidisciplinary unit should be involved in formulating a plan of management and should work as a team to support the patient and family emotionally, physically and medically. Because the primary pathology is irreversible and the treatment is only supportive and surviving patients are managed according to the degree of clinical complaints and the systems affected.

## REFERENCES

- Ahmad Z, Goyal A, Das CJ, Deka D, Sharma R. Herlyn-Werner-Wunderlich syndrome presenting with infertility: Role of MRI in diagnosis. *Indian J Radiol Imaging*. 2013; 23(3):243-6.
- Aydin R, Ozdemir AZ, Ozturk B, Bilgici MC, Tosun M. A rare cause of acute abdominal pain: Herlyn-Werner-Wunderlich syndrome. *Pediatr Emerg Care*. 2014; 30(1):40-2.
- Becerra JE, Khoury MJ, Cordero JF, Erickson JD. Diabetes mellitus during pregnancy and the risks for specific birth defects: A population-based case-control study. *Pediatrics* 1990; 85: 1-9.
- Boulas MM. Recognition of caudal Regression Syndrome. *Adv Neonatal Care* 2009; 9: 61-69.
- Duhamel B. From the mermaid to anal imperforation: the syndrome of caudal regression. *Arch Dis Child*., 1961;36:152-55.
- Epelman M, Dinan D, Gee MS, Servaes S, Lee EY, Darge K. Müllerian duct and related anomalies in children and adolescents. *Magn Reson Imaging Clin N Am*. 2013; 21(4):773-89.
- Heinonen PK. Clinical implications of the didelphic uterus: longterm follow-up of 49 cases. *Eur J Obstet Gynecol Reprod Biol*. 2000; 91(2):183-90. 32.
- Orazi C, Lucchetti MC, Schingo PM, Marchetti P, Ferro F. Herlyn-Werner-Wunderlich syndrome: uterus didelphys, blind hemivagina and ipsilateral renal agenesis. Sonographic and MR findings in 11 cases. *Pediatr Radiol*. 2007;37(7):657-65.
- S.K. Bajaj, R. Misra, B.B. Thukral, R. Gupta OHVIRA: Uterus didelphys, blind hemivagina and ipsilateral renal agenesis: advantage *MRI J Hum Reprod Sci*, 5 (2012), pp. 67-70.
- Sugiura-Ogasawara M, Ozaki Y, Suzumori N. Müllerian anomalies and recurrent miscarriage. *Curr Opin Obstet Gynecol*., 2013;25(4):293-8
- The American Fertility Society classifications of adnexal adhesions, distal tubal occlusion, tubal occlusion secondary to tubal ligation, tubal pregnancies, Müllerian anomalies and intrauterine adhesions. *Fertil Steril*. 1988;49(6):944-55
- Tortori-Donati P, Fondelli MP, Rossi A, Charlers AR, Armando C, Valeria C. Segmental spinal dysgenesis: neuro-radiologic findings with clinical and embryologic correlation. *Am J Neuroradiol* 1999; 20: 445-456.
- Vercellini P, Daguati R, Somigliana E, Vigano P, Lanzani A, Fedele L. Asymmetric lateral distribution of obstructed hemivagina and renal agenesis in women with uterus didelphys: institutional case series and a systematic literature review. *Fertil Steril*. 2007;87(4):719-24
- Wilmshurst JM, Kelly R, Borzyskowski M: Presentation and outcome of sacral agenesis: 20 Years' experience. *Dev Med Child Neurol*., 1999; 41: 806-812.
- Youssef .obstructed hemivagina and ipsilateral renal anomaly syndrome with Uterus didelphys(OHVIRA). *Middle east fertile soc J*., 2013; 2012(12): 004.

\*\*\*\*\*