



ISSN: 0975-833X

Available online at <http://www.journalcra.com>

INTERNATIONAL JOURNAL
OF CURRENT RESEARCH

International Journal of Current Research
Vol. 10, Issue, 12, pp.76434-76440, December, 2018

DOI: <https://doi.org/10.24941/ijcr.33264.12.2018>

RESEARCH ARTICLE

THE ANALGESIC EFFECT OF PARACETAMOL WHEN ADDED TO LIDOCAINE FOR INTRAVENOUS REGIONAL ANESTHESIA

*Dr. Lamyaa Malik Mohammed, Dr.Sura Mustafa Abbas and Dr. Ali Abdulhammeed

Ministry of Iraqi Health, AL- Yarmouk – Teaching Hospital

ARTICLE INFO

Article History:

Received 10th September, 2018
Received in revised form
24th October, 2018
Accepted 06th November, 2018
Published online 31st December, 2018

Key Words:

Intravenous Regional Anesthesia,
Paracetamol, Lidocaine.

ABSTRACT

Background: Intravenous regional anesthesia (IVRA) technique is easy, reliable and cost effective with a high success rate of 94–98% when used in short operative procedures of hand or forearm (Mahmoud *et al.*, 2015; Scott, 2014). Many adjuvant drugs have been added to local anesthetics, such as, NSAIDs, paracetamol, opioids and adrenergic receptor agonists. **Objective:** To evaluate the effect of paracetamol on sensory and motor block onset time, sensory and motor recovery and postoperative analgesia, when added to lidocaine in IV regional anesthesia (IVRA). **Patient and methods:** 60 patients were enrolled in simple randomized double blinded prospective clinical study in Baghdad in Al-Yarmouk teaching hospital from 1st of February 2016 to 1st of December 2016. They were ASA I and II patients with upper limb (forearm and hand) elective surgery the expected time of surgery was 20 – 60 min planned for intravenous regional anesthesia. The patients were divided into 3 groups; Group 1: patients received IVRA 40 ml of 0.5% lidocaine with normal saline, Group 2: received IVRA 40ml 0.5% lidocaine with 300mg paracetamol, Group 3: received IVRA 40 ml of 0.5% lidocaine solution with normal saline with systemic 300 mg paracetamol. **Results:** There was no significant differences noted among the three groups regarding the age, sex, height, weight, BMI and VAS score. There were significant differences in sensory block onset time between group 2 and group 1 (more rapid sensory block onset time in group 2 as p value < 0.001) and between group 2 and group 3 (more rapid sensory block onset time in group 2 as p value was 0.023) and between group 1 and group 3 (more rapid sensory block onset time in group 3 as p value was 0.001). There was a significant difference regarding sensory recovery between group 2 and 1 (prolonged sensory recovery in group 2 as p value < 0.001) and between group 2 and 3 (prolonged sensory recovery in group 2 as p value < 0.001) but no difference between group 1 and 3 (as p value 0.994). There was a significant difference regarding motor block onset time, between group 2 and 1 (more rapid motor block onset time in group 2 as p value < 0.001) and between group 2 and 3 (more rapid motor block onset time in group 2 as p value < 0.001) but no differences between group 1 and 3 (as p value 0.507). Also there was a significant difference regarding motor recovery between group 2 and 1 (prolonged in group 2 as p value < 0.001) and between group 2 and 3 (prolonged in group 2 as p value < 0.001), but no differences between group 1 and 3 (as p value 0.088). There was no difference in VAS score among all groups as p value more than 0.05. There was a significant difference in the time for the first analgesic request between group 2 and 1 (prolonged in group 2 as p value < 0.001) and between group 2 and 3 (prolonged in group 2 as p value < 0.001) and between group 1 and 3 (prolonged in group 3 as p value < 0.001). **Conclusion:** IVRA paracetamol cause a decrease in sensory block onset time, motor block onset time, and increase in motor and sensory recovery time with no change in VAS score postoperatively as compared with systemic paracetamol or lidocaine alone.

*Corresponding author:

Copyright © 2018, Lamyaa Malik Mohammed *et al.* This is an open access article distributed under the Creative Commons Attribution License, which permits unrestricted use, distribution, and reproduction in any medium, provided the original work is properly cited.

Citation: Dr. Lamyaa Malik Mohammed, Dr.Sura Mustafa Abbas and Dr. Ali Abdulhammeed, 2018. "The Analgesic Effect of Paracetamol When Added to Lidocaine for Intravenous Regional Anesthesia", *International Journal of Current Research*, 10, (12), 76434-76440.

INTRODUCTION

Inguinal hernia repair, a common day-surgery procedure, is associated with considerable postoperative discomfort (Mahmoud, 2015). The perioperative management of pain following abdominal surgery can pose a challenge to anesthesia providers. Conventional practice has involved the use of opioids as well as neuraxial analgesic techniques.

Unfortunately, these therapies are not without potential risks and side effects. These include nausea, vomiting, pruritus, urinary retention, constipation, respiratory depression, and sedation (Scott, 2014). As a result, the goal to reduce perioperative pain has taken on a multimodal approach. Multimodal or "balanced" analgesia uses a combination of opioid and nonopioid analgesics to improve pain control and minimize opioid related side effects (White, 2010).

These include the use of nonsteroidal anti-inflammatory drugs, local anesthetics, peripheral nerve blocks, gabapentinoids, and α_2 adrenergic agonists. Any combination of these therapies can help reduce the surgical stress response and improve patient outcomes such as pain control, patient satisfaction, time to discharge, and return to daily activities (White, 2010; Kehlet, 1993; Kehlet *et al.*, 2001). Uncontrolled postoperative pain may produce a range of detrimental acute and chronic effects. The attenuation of perioperative pathophysiology that occurs during surgery through reduction of nociceptive input to the CNS and optimization of perioperative analgesia may decrease complications and facilitate recovery during the immediate postoperative period and after discharge from the hospital (Ronald, 1999). Uncontrolled postoperative pain may activate the sympathetic nervous system and thereby contribute to morbidity or mortality. Sympathetic activation may increase myocardial oxygen consumption, which may be important in the development of myocardial ischemia and infarction, and may decrease myocardial oxygen supply through coronary vasoconstriction and attenuation of local metabolic coronary vasodilation (Besson, 1999). Activation of the sympathetic nervous system may also delay return of postoperative gastrointestinal motility, which may develop into paralytic ileus. Although postoperative ileus is the result of a combination of inhibitory input from central and local factors, an increase in sympathetic efferent activity, such as from uncontrolled pain, may decrease gastrointestinal activity and delay return of gastrointestinal function (Kehlet, 2001). Innervation of the inguinal region arises from the distal extensions of the more cephalad lumbar plexus nerves. Both the iliohypogastric and ilioinguinal nerves emanate from the first lumbar spinal root. Superomedial to the anterior superior iliac spine, the iliohypogastric and ilioinguinal nerves pierce the transversus abdominis to lie between it and the internal oblique muscles.

After traveling a short distance inferomedially, their ventral rami pierce the internal oblique to lie between the internal and external oblique muscles before giving off branches, which pierce the external oblique to provide cutaneous sensation. The iliohypogastric nerve supplies the skin over the inguinal region. The ilioinguinal nerve runs anteroinferiorly to the superficial inguinal ring, where it emerges to supply the skin on the superomedial aspect of the thigh (Figure 1.1) (Figure 1.2) (Atlas of Anatomy on site; <http://doctorlib.info/medical/anatomy/29.html>). The authors applied a transversely orientated ultrasound probe to the anterolateral abdominal wall where the three muscle layers are most distinct. After identification of the TAP between the internal oblique and transversus abdominis muscles, the probe was moved posterolaterally to lie across the midaxillary line just superior to the iliac crest (i.e., over the triangle of Petit). The block needle was then introduced anteriorly and advanced in an in-plane approach (Figure 1.4) (Hebbard, 2007).

Ultrasound-Guided TAP Block: Real-time ultrasonography facilitates easy needle visualization as it approaches and reaches the target fascial plane. A hypoechoic layer, created by injection of local anesthetic, is also easily visualized. The external oblique, internal oblique and transversus abdominis muscles are identified (Figure 1.6) (Hebbard, 2007). The needle is inserted medial to the transducer and advanced in plane using a medial to lateral direction until the needle tip reaches the TAP and local anesthetic is deposited. This provides analgesia for inguinal hernia (Mark, 2012).

The analgesic effect of the TAP block is dependent on the surgical procedure, block technique, local anesthetic dose and volume, and timing of injection (<http://www.nysora.com/mobile/techniques/nerve-stimulator-and-surface-based-techniques/truncal-and-cutaneous-blocks/3027-ilioinguinal-and-iliohypogastric-blocks.html>). There is no clear consensus regarding the optimal local anesthetic type, dose, or volume of injection. This has led some investigators to use a weight based dose of local anesthetic, whereas others use a predetermined injection volume. This may increase the risk of local anesthetic toxicity in patients with low body weight (Niraj, 2011). The distribution and spread of local anesthetics within the TAP are dependent on the site of injection. According to McDonnell *et al.*,⁽¹⁹⁾ a sensory block was achieved from T7 to L1 via the triangle of Petit. Further clinical studies showed a lower level of sensory block from T10 to L1 using the triangle of Petit and ultrasound-guided midaxillary approaches (Griffiths, 2010).

Bupivacaine is a local anesthetic drug belonging to the aminoamide group. It is commonly marketed under various trade names, including Marcain, Marcaine (CareStream Dental®), Sensorcaine (Astra Zeneca®) and Vivacaine (Septodont®). With a half life of 3.5 hr in adult and 8.1 hr in paediatrics. Bupivacaine was the first long-acting amide local anesthetic. Chemical structure makes bupivacaine significantly more hydrophobic than mepivacaine and lidocaine, slower in onset but of longer duration. Bupivacaine is highly protein bound, which is consistent with long duration and potential for cardiotoxicity. Indeed, the cardiotoxicity of bupivacaine prompted the development of ropivacaine and levobupivacaine.

J.A. Aguirre *et al.* Bupivacaine is popular for use in a wide array of applications, including infiltration (0.25%), peripheral nerve blocks (0.375-0.5%), spinal (0.5 and 0.75%), and epidural (0.5 and 0.75%) anesthesia. Because of systemic toxicity, it is not used for IV regional anesthesia (Kanazi, 2010). Bupivacaine has a lower therapeutic index, concerning cardiovascular toxicity compared to lidocaine. Bupivacaine is more slowly absorbed into plasma than lidocaine and produces plasma peak concentrations that are approximately 40% lower. Clinically used concentrations of bupivacaine vary from 0.05% (epidural continuous infusions for labor analgesia and acute pain management) to 0.5% (spinal anesthesia and peripheral nerve blocks). Peripheral nerve blocks provide sensory block for 4-12 h, sometimes up to 24 h (Kanazi, 2010). Bupivacaine is indicated for local anesthesia including infiltration, nerve block, epidural, and intrathecal anesthesia. Bupivacaine often is administered by epidural injection before total hip arthroplasty. It also is commonly injected to surgical wound sites to reduce pain for up to 20 hours after the surgery. Sometimes, bupivacaine is co-administered with epinephrine to prolong the duration of its action, fentanyl for epidural analgesia, or glucose. Bupivacaine is contraindicated for intravenous regional anaesthesia (IVRA) because of potential risk of tourniquet failure and systemic absorption of the drug. Compared to other local anaesthetic, bupivacaine is markedly cardiotoxic. However, adverse drug reactions (ADRs) are rare when it is administered correctly. Most ADRs relate to administration technique (resulting in systemic exposure) or pharmacological effects of anesthesia, however allergic reactions can rarely occur. Systemic exposure to excessive quantities of bupivacaine mainly result in central nervous system (CNS) and cardiovascular effects, CNS effects usually occur at lower blood plasma concentrations and additional cardiovascular effects present at higher concentrations, though

cardiovascular collapse may also occur with low concentrations. include CNS excitation(nervousness, tingling around the mouth, tinnitus, tremor, dizziness, blurred vision, seizures) followed by depression(drowsiness, loss of consciousness, respiratory depression and apnea). Regarding cardiovascular toxicity include hypotension, bradycardia, arrhythmias, and/or cardiac arrest - some of which may be due to hypoxemia secondary to respiratory depression (Aveline *et al.*, 2011). Treatment of overdose: lipid rescue There is animal evidence (Rosenblatt, 2016; Litz *et al.*, 2006) that Intralipid, a commonly available intravenous lipid emulsion, can be effective in treating severe cardiotoxicity secondary to local anaesthetic overdose, and human case reports of successful use in this way (Kaye *et al.*, 2012; Rossi, 2006) Plans to publicize this treatment more widely have been published (Rosenblatt *et al.*, 2006). Bupivacaine binds to the intracellular portion of sodium channels and blocks sodium influx into nerve cells, which prevents depolarization. Since pain transmitting nerve fibres tend to be thinner and either unmyelinated or lightly myelinated, the agent can diffuse more readily into them than into thicker and more heavily myelinated nerve fibreslike touch, proprioception, etc. (Myelin is non-polar / lipophilic).It should be noted, however, that bupivacaine also blocks specific potassium channels, an effect contributing to resting membrane potential depolarization. All local anesthetics are membrane stabilizing drugs; they reversibly decrease the rate of depolarization and repolarization of excitable membranes (like nociceptors). Local anesthetic drugs act mainly by inhibiting sodium influx through sodium-specific ion channels in the neuronal cell membrane, in particular the so-called voltage-gated sodium channels. When the influx of sodium is interrupted, an action potential cannot arise and signal conduction is inhibited. The receptor site is thought to be located at the cytoplasmic(inner) portion of the sodium channel. Local anesthetic drugs bind more readily to sodium channels in an activated state, thus onset of neuronal blockade is faster in neurons that are rapidly firing. This is referred to as state dependent blockade. In this technique Local anesthetics can block almost every nerve between the peripheral nerve endings and the central nervous system. Where local anesthetic of a volume concentration where irrigated in a wound or on a mucous membrane and kept for period of time to obtain analgesic or anesthetic effect (Litz, 2006).

Aim of the study: To compare the postoperative pain relief provided by Ultrasound guided TAP block technique with ultrasound guided ilioinguinal/ iliohypogastric nerve blockade in adult undergoing unilateral hernia repair surgery regarding duration and any further addition of other medications postoperatively.

PATIENTS AND METHODS

A prospective randomized controlled study was carried out in General Surgery theatres of Baghdad. Teaching Hospital, during the period from the first of January 2016 to the 1st of January 2017. sixty patients were included, who were operated on for inguinal hernia repair.

Inclusion criteria: The patients were included in the study if they met the following.

- Gender: Male
- Age: 18-62 years
- Patients of ASA grade I and II medical condition.
- All patients were scheduled for elective hernia repair.

Exclusion criteria

- Patient refusal
- Neurological or psychiatric disorder.
- Bilateral inguinal hernia.
- Drug allergy
- BMI >40 kg m⁻².
- Skin infection at the puncture site.
- Preoperative opioid or non-steroidal anti-inflammatory drugs treatment for chronic pain.

The verbal consent was obtained from all patients before enrolling them in the Study, and the study was approved by the scientific council of anaesthesia and intensive care. Data were collected using a pre-constructed form sheet (Figure 5) and a detailed history was taken from each patient; information about the age of the patient and past medical history. A clinical examination was performed by general examination and vital signs measurement. All patients received 50mg ranitidine, 10 mg metoclopramide, 8mg dexamethasone and 0.02mg/kg midazolam as pre-induction agent. Anesthesia was induced with a sleeping dose of propofol up to 1.5-2.5 mg/kg, 1^μg/kg fentanyl, and tracheal intubation(with size 7.0-8.0 ID endotracheal tube) was facilitated with 0.6 mg/Kg of Rocuronium. Anesthesia was maintained with isoflurane 1.25% in 100% oxygen. Neuromuscular blockade was maintained with incremental doses of 0.1mg/kg Rocuronium

Then all patients were divided randomly into two groups:

Group A: 30 patients, under ultrasound guide who received anterior approach TAP block at the end of the operation and after aseptic preparation to the puncture site and ultrasound probe, placed the ultrasound probe oblique on abdomen on line joining the anterior superior iliac spine with umbilical using in plane technique insert 22G needle between internal oblique and transversus abdominis muscle by using 20ml of bupivacaine 0.25% concentration where 8ml used for ilioinguinal nerve, 8ml for iliohypogastric nerve, and the remaining 4 ml for genitofemoral nerve.

Group B: 30 patients, under ultrasound guide who received TAP block posterior approach at the end of the operation under aseptic preparation to the puncture site and the ultrasound probe, placed the probe over the triangle of petit(mid axillary line), in plane technique insert 22G needle between internal oblique and transversus abdominis by using 20ml of bupivacaine 0.25% concentration. In both groups, according to patient request and the pain score, 75 mg Diclofenac sodium injection was given intramuscularly to relief pain. Post-operatively, data, including pain score, the need for analgesia, pulse rate, blood pressure and respiratory rate, were recorded after 10 min post-operative period and considered as(zero hour "Oh"), then the same data were taken and reported in the data sheet(figure 5) at Recovery, 2nd,4th& 8th hourly(recovery, 2h, 4h &8h) post-operatively. Numerical rating scale was used as a pain scoring system, as it is the simplest and most commonly used scale. The numerical scale is most commonly 0 to 10' with 0 being "no pain" and 10 being "the worst pain imaginable" as the patient picks. The number that best describes the pain dimension, usually intensity. Advantages of numerical rating scale include simplicity, reproducibility, easy comprehensibility, and sensitivity to small changes in pain. (Picard, 2006).

Statistical analysis: Data were analyzed using SPSS (statistical package for social sciences) version 20/IBM. Descriptive statistics were expressed as mean \pm SD(standard deviation.) Student's paired t - test was used for comparison among vital signs, pain score and the need for analgesia within groups, Student's independent t- test was used to compare variables in between both groups. All data were presented in tables, figures or paragraphs and in all statistical analysis and procedures level of significance was set at p-value(sig.) 0.05 to be considered as significant difference

RESULTS

By using the SPSS V20.0/IBM using the independent sample t- student test, it was found that no significant differences between both groups in Age, Weight were the p-Value was more than 0.05 and as shown in the tables and graphs below: According to the ASA classification its shown that 23 patient were ASA 1 and 7 patient ASA2 in group A and 25 patient ASA1 and 5 patient were ASA 2 in group B.

DISCUSSION

Transversus abdominis plane blocks are a relatively new technique used in a multimodal approach to provide postoperative analgesia following abdominal surgery. It is considered a technically simple block to perform' with a high margin of safety, especially with ultrasound guidance (Kampe, ?). The benefit of TAP block in patients undergoing various procedures such as abdominal hysterectomy, (Shorten, 2006) Cesarean section (Young, 2012; Carney, 2008), large bowel resection (McMorrow, 2011), open retropubic prostatectomy (McMorrow, 2011), laparoscopic cholecystectomy (McDonnell, 2007; O'Donnell *et al.*, 2006) and appendectomy (El-Dawlatly, 2009) has been demonstrated. Most studies compared TAP block with placebo or with other type of local surgical wound infiltration the aim of our study is to compare of different approach of TAP block regarding postoperative analgesia and duration of pain relief. According to the result there is no significant difference between both groups regarding age distribution, ASA, weight, systolic, diastolic blood pressure, pulse rate and respiratory rate. Regarding to postoperative analgesia and pain relief our study show no significant difference in both group in the first 8 hours this is may be due to the use of the same type of drug which was bupivacaine, and because of the two approaches same sensory nerve fibers and both groups were effective, In concern to the need of analgesia only 2 patient from the group B required analgesia at recovery time and only 1 patient required analgesia at 8 hour postoperatively from group A and that represent 6.666% and 3.333% respectively.

F.W. ABDALLAH *et al* during their study about the Duration of analgesic effectiveness after the posterior and lateral transversus abdominis plane block techniques for transverse lower abdominal incisions: a meta- analysis shows that the posterior TAP block appears to produce more prolonged analgesia than the lateral TAP block, this is regarding the comparison between posterior approach and lateral approach of TAP block, suggest that performing the posterior TAP block may be a better technique for prolonged analgesia after lower abdominal transverse incision surgeries. The posterior technique can reduce opioid consumption, rest and dynamic pain scores, and the incidence of sedation up to 48 h postoperatively³⁷¹

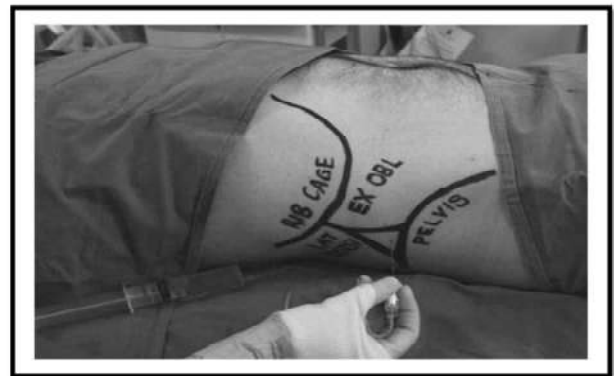

Figure 1.3. Surface anatomical landmarks identify the triangle of petit

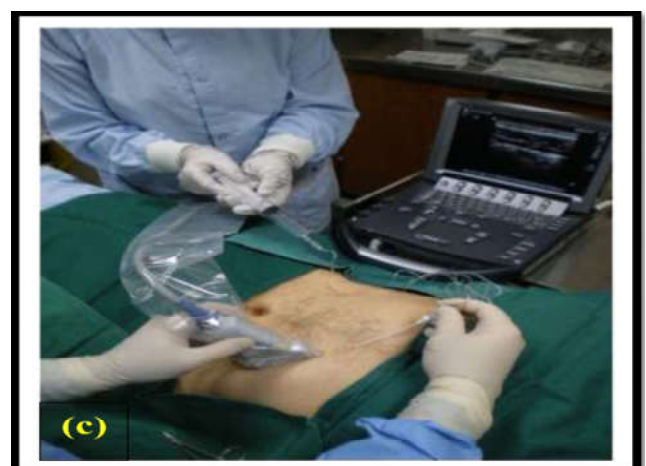
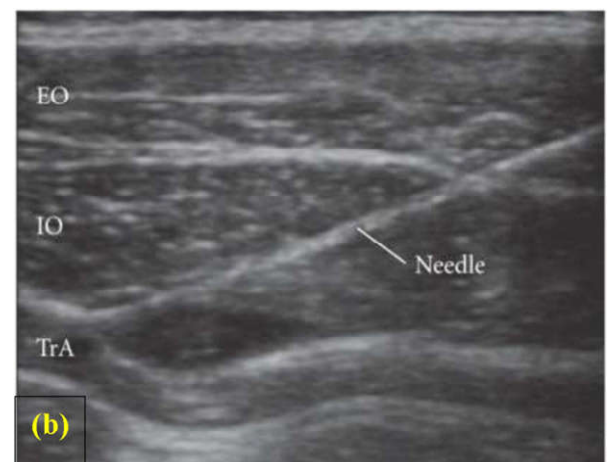
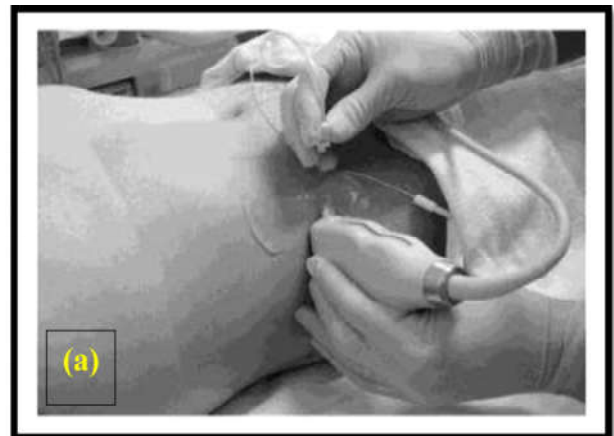Figure 2. (a, b, c), Ultrasound-Guided TAP Block

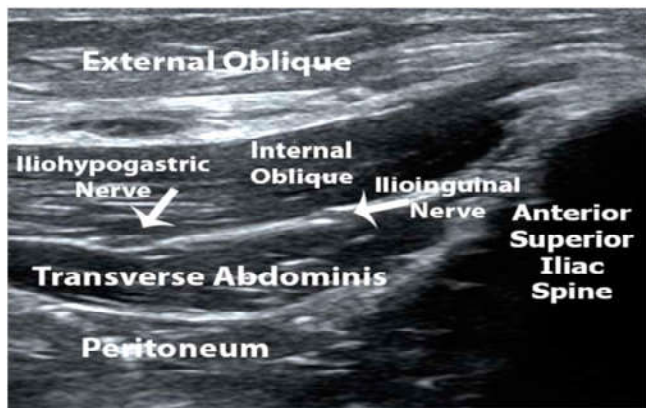


Figure 3. Ultrasound Guided Iliohypogastric Ilioinguinal Nerve Block Image

Table 1. Age distribution between both groups

Group	18-30years	31-45 years	>45 years
Anterior	19 (63.333%)	9 (30%)	2 (6.333%)
Posterior	18 (60%)	9 (30%)	3 (10%)

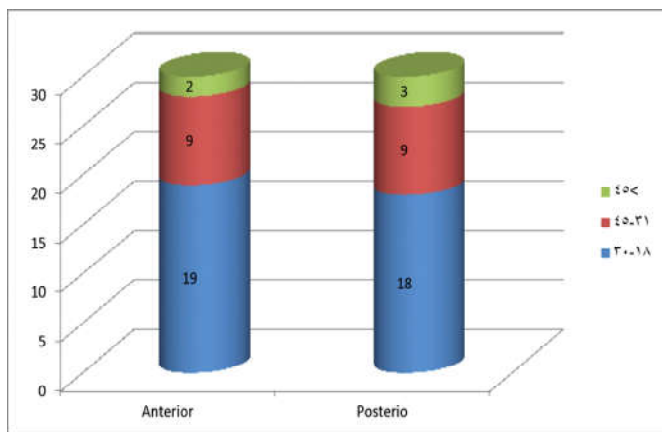


Figure 3.1. Age distribution between both groups

Table 2. Mean of age and weight for both groups

	Group	Mean	Standard deviation	p-Value
Age (years)	Anterior	29.83	11.185	0.865
	Posterior	31.37	11.950	
Weight (Kg)	Anterior	84.40	11.294	0.841
	Posterior	83.77	11.566	

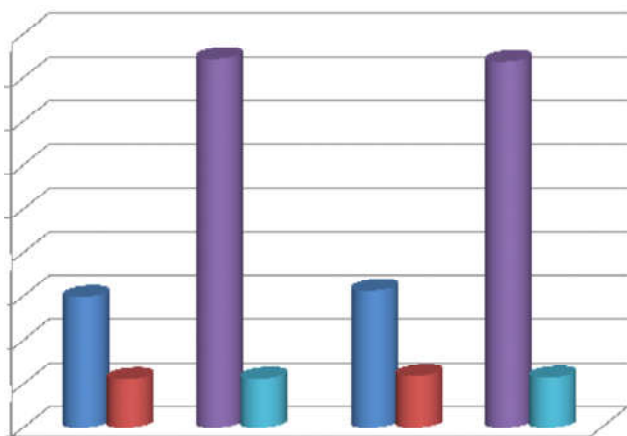


Figure 5. Mean and Standard deviation of age and weight

Table 3.3: Systolic blood pressure in both groups

Time	Group	Mean	Standard deviation	p-Value
Pre-Induction	Anterior	121.93	8.614	.441
	Posterior	122.00	9.770	
Recovery	Anterior	120.87	6.169	.808
	Posterior	121.53	6.274	
2 hours	Anterior	118.47	5.355	.462
	Posterior	118.60	6.117	
4 hours	Anterior	119.23	6.678	.641
	Posterior	119.93	7.220	
8 hours	Anterior	119.03	6.921	.359
	Posterior	120.90	7.997	

Table 3.5: mean of Pulse rate

Time	Group	Mean	Standard deviation	p-Value
Pre-Induction	Anterior	76.13	8.792	.616
	Posterior	77.40	9.576	
Recovery	Anterior	78.17	6.788	.723
	Posterior	78.67	6.551	
2 hours	Anterior	76.30	7.096	.576
	Posterior	76.67	7.662	
4 hours	Anterior	77.60	8.597	.885
	Posterior	76.70	7.630	
8 hours	Anterior	77.03	9.182	.961
	Posterior	77.17	8.209	

Table 3.6: Mean of respiratory rate in both groups

Time	Group	Mean	Standard deviation	p-Value
Pre-Induction	Anterior	12.30	.877	.876
	Posterior	12.27	1.112	
Recovery	Anterior	12.30	.651	.169
	Posterior	12.47	.776	
2 hours	Anterior	12.67	1.626	.176
	Posterior	12.40	1.354	
4 hours	Anterior	12.03	.183	.001
	Posterior	12.33	1.061	
8 hours	Anterior	12.47	1.456	.937
	Posterior	12.50	1.306	

In compare to our study no difference found regarding postoperatively analgesia, but the same in decrease opioid consumption. MC Donnell *et al* Demonstrate benefits include reduction of narcotic usage and pain, with The TAP block reduced visual analog scale pain scores(TAP versus control, mean \pm sd) on emergence(1 ± 1.4 vs 6.6 ± 2.8 , $P < 0.05$), and at all postoperative time points, including at 24 h(1.7 ± 1.7 vs 3.1 ± 1.5 , $P < 0.05$). Morphine requirements in the first 24 postoperative hours were also reduced (21.9 ± 8.9 mg vs 80.4 ± 19.2 mg, $P < 0.05$). There were no complications attributable to the TAP block. All TAP patients reported high levels of satisfaction with their postoperative analgesic regimen (Niraj, 2009). In compare to our study same regarding postoperatively analgesia need of potent effect analgesia of TAP block. Carney *et al* shows that The extent of analgesia provided by transversus abdominis plane blocks depends upon the site of injection and pattern of spread within the plane, The studies demonstrated that the anterior subcostal and mid-axillary ultrasound approaches resulted in a predominantly anterior spread of the contrast solution within the transversus abdominis plane and relatively little posterior spread. There was no spread to the paravertebral space with the anterior subcostal approach. The mid-axillary transversus abdominis plane block gave faint contrast enhancement in the paravertebral space at T12-L2. In contrast, the posterior approaches, using both landmark and ultrasound identifications, resulted in predominantly posterior spread of contrast around the quadratus lumborum to the paravertebral space from T5 to L1 vertebral levels (Abdallah *et al.*, 2012).

In compare to our study they found difference in spread of analgesia while in our study was the same. Yuexing Wang *et al* demonstrate a systematic review and metaanalysis of randomized controlled trials on Improved perioperative analgesia with ultrasound-guided ilioinguinal/iliohypogastric nerve or transversus abdominis plane block for open inguinal surgery they found from there data collections that Ultrasound-guided II/IH nerve or TAP blocks were associated with a reduced use of intraoperative additional analgesia and a significant reduction of pain scores during day-stay. The use of rescue drugs was also significantly lower in the ultrasound-guided group (McDonnell *et al.*, 2007) And it was the same as our study in regard to analgesia consumption.

Mahmoud Hassan Mohamed and Manal Mohamed Kamal study the postoperative analgesia of ultrasound-guided ilioinguinal/ iliohypogastric nerve block versus ultrasound-guided TAP block for pediatric inguinal hernia repair they conclude that US-guided II/IH nerve block provides longer and more efficient postoperative analgesia compared with TAP block for pediatric inguinal herniorrhaphy (Mahmoud, 2015). While in our study was the same regarding postoperatively analgesia consumption. Aveline *et al* study the Comparison between ultrasound-guided transversus abdominis plane and conventional ilioinguinal/iliohypogastric nerve blocks for day-case open inguinal hernia repair they found that Median VAS pain scores at rest were lower in the ultrasound-guided TAP group at 4 h(11 vs 15, P=0.04), at 12 h(20 vs 30, P=0.0014), and at 24 h(29 vs 33, P=0.013). Pain after the first 24 h, at 3 and 6 months after surgery, and DN4 scores were similar in both groups(P=NS).

The proportion of patients with VAS >40 mm on movement at 6 months was comparable {18.2% (95% CI(12.2-26.1%)) vs 22.4%(15.8-30.6%) in the TAP and IHN groups, respectively, P=0.8}. Postoperative morphine requirements were lower during the first 24 h in the TAP block group(P=0.03) (Carney, 2011). Regarding to our study it was the same consumption of postoperatively analgesia. Ahmed M. Faried *et al* shows that TAP block is an easy regional nerve block technique that provides postoperative pain relief for longer duration as compared to ilioinguinal/iliohypogastric nerve blockade in Children Undergoing Lower Abdominal Surgery⁽⁴²⁾. It was the same to our study.

Conclusion and Recommendations

Conclusion

- Ultrasound guided TAP block is an easy regional nerve block technique that provides postoperative pain relief for longer duration same as ultrasound guided ilioinguinal/iliohypogastric nerve blockade in adult undergoing unilateral groin surgery, there is no significant difference between both methods..
- Those two methods provide good analgesia with less postoperative other medication use without any significant side effect..

Recommendations

- Studying both methods in larger groups..
- Compare both methods in other type of surgical procedures.
- Using of other additive drugs with local anesthetics for improving postoperative pain relief.

REFERENCES

- Abdallah FW., Chan VW., Brull R. 2012. Transversus abdominis plane block: a systematic review. *Reg Anesth Pain Med.* Mar-Apr. 37(2): 193-209.
- Ahmed M. Faried, *et al.* Ultrasound guided Transverses Abdominal Plane Block versus Ilioinguinal/ iliohypogastric Nerve Blocks for Postoperative Analgesia in Children Undergoing Lower Abdominal Surgery. *Enliven. J Anesthesiol Crit Care Med.* 2(1): 001.
- Atkinson RS., Rushman GB., Lee JA. 1987. A Synopsis of Anaesthesia. 10th edition. Bristol. UK: Wright.
- Atlas of Anatomy on site:
- Aveline C., Le Hetet H., Le Roux A. *et al.*, 2011. Comparison between ultrasound-guided transversus abdominis plane and conventional ilioinguinal/iliohypogastric nerve blocks for day-case open inguinal hernia repair. *British Journal of Anaesthesia.* 106(3): 380-386.
- Aveline, C. *et al.* 2011. Study the Comparison between ultrasound-guided transversus abdominis plane and conventional ilioinguinal/iliohypogastric nerve blocks for day-case open inguinal hernia repair. *Br J Anaesth.* 106(3): 380-386.
- Besson JM. 1999. The neurobiology of pain. *Lancet.* 353:1610.
- Carney J. *et al.*, 2008. The transversus abdominis plane block provides effective postoperative analgesia in patients undergoing total abdominal hysterectomy. *Anesth Analg.* 107:2056-60.
- Carney, J. *et al.* 2011. Studies on the spread of local anaesthetic solution in transversus abdominis plane blocks. *Anaesthesia.* Nov. 66(11): 1023-30.
- Chiono J. *et al.* 2010. The ultrasound-guided transversus abdominis plane block for anterior iliac crest bone graft postoperative pain relief: a prospective descriptive study. *Regional Anesthesia and Pain Medicine.* 35(6):520-524.
- El-Dawlatly AA., *et al.* 2009. Ultrasound-guided transversus abdominis plane block: Description of a new technique and comparison with conventional systemic analgesia during laparoscopic cholecystectomy. *Br J Anaesth.* 102:763-7.
- Griffiths JD., *et al.*, 2010. Transversus abdominis plane block does not provide additional benefit to multimodal analgesia in gynecological cancer surgery. *Anesthesia and Analgesia.* 111(3):797-801.
- Hebbard P. *et al.*, 2007. Ultrasound-guided transversus abdominis plane(TAP) block. *Anaesthesia and Intensive Care.* 35(4): 616617.
- <http://doctorlib.info/medical/anatomy/29.html>
- <http://www.nysora.com/mobile/techniques/nerve-stimulator-and-surface-based-ra-techniques/truncal-and-cutaneous-blocksa/3027-ilioinguinal-and-iliohypogastric-blocks.html>
- <https://trenningorehab.no/identify-treat-lumbar-plexus-compression-syndrome-lpcs/>
- Kampe S., Warm M., Kasper S. Concept for postoperative analgesia after pedicled TRAM flaps: Continuous wound instillation with 0.2% ropivacaine via multilumen catheters. *British Journal of Plastic Surgery.* 56(5): 478-483.
- Kanazi GE. *et al.*, 2010. The analgesic efficacy of subarachnoid morphine in comparison with ultrasound-guided transversus abdominis plane block after cesarean delivery: a randomized controlled trial. *Anesthesia and Analgesia.* 111(2):475-481.

- Kaye A D., Urman R D., Vadivelu N. 2012. Essentials of regional anesthesia. 1st edition. Springer.139-40.
- Kehlet H, Holte K. Effect of postoperative analgesia on surgical outcome.Br J Anaesth. 2001. 87(1):62-72.
- Kehlet H., Dahl JB. 1993. The value of 'multimodal' or 'balanced analgesia' in postoperative pain treatment. *Anesth Analg.* 77(5): 1048-1056.
- Kjetil L., 2017. How to identify and treat lumbar plexus compression syndrome(LPCS). ARTIKLER. March. On site:
- Litz, RJ. *et al.* 2006. Successful resuscitation of a patient with ropivacaine-induced asystole after axillary plexus block using lipid infusion. *Anaesthesia.* 61(8): 800-1.
- Mahmoud HM., Manal M Kamal. 2015. Comparison of postoperative analgesia of ultrasound-guided ilioinguinal/iliohypogastric nerve block versus ultrasound-guided TAP block for pediatric inguinal hernia repair. *ASJA.* 8(4): 658-663.
- Mark JY. *et al.*, 2012. Clinical Implications of the Transversus Abdominis Plane Block in Adults. *Anesthesiol Res Pract.* 2012(731645).
- McDonnell JG, *et al.* 2007. The analgesic efficacy of transversus abdominis plane block after abdominal surgery: a prospective randomized controlled trial. *Anesth Analg.* 104(1): 1937.
- McDonnell JG. *et al.* 2008. The analgesic efficacy of transversus abdominis plane block after caesarean delivery: A randomized controlled trial. *Anesth Analg.* 106:186-91.
- McDonnell JG., *et al.* 2007. Analgesic efficacy of transversus abdominis plane(TAP) block after abdominal surgery: A prospective randomized controlled trial. *Anesth Analg.* 104:193-7.
- McMorrow RC. *et al.* 2011. Comparison of transversus abdominis plane block vs spinal morphine for pain relief after Caesarean section. *Br J Anaesth.*, 106:706-12.
- Niraj G. *et al.* 2009. Analgesic efficacy of ultrasound-guided transversus abdominis plane block in patients undergoing open appendectomy. *Br J Anaesth.*, 103:601-5.
- Niraj G. *et al.*, 2011. Comparison of analgesic efficacy of subcostal transversus abdominis plane blocks with epidural analgesia following upper abdominal surgery. *Anaesthesia.* 66(6): 465-471.
- O'Donnell BD., McDonnell JG., McShane AG. 2006. The transversus abdominis plane(TAP) block in open retropubic prostatectomy. *Reg Anesth Pain Med.*, 3:91.
- Picard J, Meek T. Lipid emulsion to treat overdose of local anaesthetic: the gift of the glob. *Anaesthesia.* February 2006. 61(2): 107-9.
- Ra YS., Kim CH., Lee GY., Han JI. 2010. The analgesic effect of the ultrasound-guided transverse abdominis plane block after laparoscopic cholecystectomy. *Korean J Anesthesiol.* 58: 362-8.
- Rafi AN. 2001. Abdominal field block: a new approach via the lumbar triangle. *Anaesthesia.* 56(10): 1024-1026.
- Ronald DM., Lars IE., Lee AF., *et al.*, 2009. Miller's Anesthesia. Churchill and Livingstone 7th edition. 1210
- Rosenblatt MA., *et al.*, 2006. Successful use of a 20% lipid emulsion to resuscitate a patient after a presumed bupivacaine-related cardiac arrest. *Anesthesiology.* July. 105(1): 217-8.
- Rossi S. Australian Medicines Handbook. 2006. Adelaide: Australian Medicines Handbook. 2006.
- Scott U., Jeffrey M. 2014. Transversus Abdominis Plane(TAP) Blocks. *AANA Journal.* February. 82(1): 72-79.
- Shorten G, *et al.* Postoperative pain management: an evidence-based guide to practice. 1st edition. Saunders. 2006:102-3.
- White PF, Kehlet H. Improving postoperative pain management: what are the unresolved issues?. *Anesthesiology.* 2010. 112(1): 220-225.
- Young MJ. *et al.*, 2012. Clinical implications of the transversus abdominis plane blocks in adults. *Anesthesiol Res Pract.* 2012.1-11.
- Yuexiang W. *et al.*, 2016. Improved perioperative analgesia with ultrasound-guided ilioinguinal/iliohypogastric nerve or transversus abdominis plane block for open inguinal surgery: a systematic review and meta-analysis of randomized controlled trials. *J Phys Ther Sci. March.* 28(3): 1055-1060.
- Yuexiang Wang, *et al.* 2015. Improved Perioperative Analgesia with Ultrasound- Guided Ilioinguinal/iliohypogastric Nerve or Transversus Abdominis Plane Block for Open Inguinal Surgery: A Systematic Review and Meta-Analysis of Randomized Controlled Trials. *Phys Med Rehabil Int.*, 2(6): 1055.
