



ISSN: 0975-833X

Available online at <http://www.journalcra.com>

INTERNATIONAL JOURNAL  
OF CURRENT RESEARCH

International Journal of Current Research  
Vol. 11, Issue, 01, pp.833-836, January, 2019

DOI: <https://doi.org/10.24941/ijcr.34235.01.2019>

## RESEARCH ARTICLE

# CLINICAL RADIOGRAPHIC CT AND MRI EVALUATION OF PELVIC INJURIES IN THE ELDERLY: A COMPARATIVE ANALYSIS

<sup>1</sup>Sonali Sharma, <sup>\*2</sup>Sudesh Sharma, <sup>3</sup>Ghanshyam Dev Gupta, <sup>4</sup>Shashi Sudan

<sup>1</sup>Assistant Professor, Radiodiagnosis, ILBS, New Delhi

<sup>2</sup>Professor Orthopaedics, GMC Jammu, 180001

<sup>3</sup>Professor and Head, Radiodiagnosis, GMC Jammu

<sup>4</sup>Professor Microbiology GMC Jammu

### ARTICLE INFO

#### Article History:

Received 08<sup>th</sup> October, 2018

Received in revised form

26<sup>th</sup> November, 2018

Accepted 14<sup>th</sup> December, 2018

Published online 31<sup>st</sup> January, 2019

#### Key Words:

Clinical – Radiological – CT – MRI – LOW Energy – Pelvic Trauma.

### ABSTRACT

**Aims of Study:** Pelvic injuries in elderly patients are usually missed because osteoporotic cancellous bone fractures of Pelvis are poorly visualized, especially with poor quality portable X rays and this becomes a bigger problem, not only from treatment angle but due to medico legal and consumer forum implications. So, this study was undertaken to compare the results of clinical, radiological, computed tomographic and MR imaging of pelvic injuries. The fragility of bones due to senile osteoporosis, makes the elderly population vulnerable to fractures of the pelvis, following minor trauma. Majority of these fractures are minimally displaced or undisplaced and likely to be missed on clinical and routine conventional radiography (wet films) by junior residents in busy emergency department. A prospective study on various diagnostic modes like clinical, radiographic, CT and MRI, was conducted in elderly patients with low energy pelvic injuries attending emergency department of GMC Jammu from June 2015 to June 2017. Out of 131 patients of low energy pelvic trauma, 86 fulfilled the inclusion criteria and consented for the study. The clinical and investigative parameters were evaluated in all the cases by a senior orthopedic surgeon and two senior radiologists. There were 65 (75.5%) females and 21 (24.5%) males. Mean age was 72.7(50 – 90) years. Commonest mode of trauma was domestic falls in 62 (72%) of cases. There were 146 fractures and 14 soft tissue injuries. The clinical examination was sensitive in 80.8% cases with low specificity of (58.6%). Plain X rays Pelvis AP view was diagnostic in 69 (80.2%) cases. Computed tomography had an accuracy level of 94.1% and MRI was effective in 97.7% of fracture cases and 85.7% in soft tissue injuries. Posterior ring fractures were missed in 2.3% by MRI, 11.5 by C T scan, 68.6% by Conventional X rays and 14.3% by clinical examination. There were 12 false positive cases clinically, 10 cases radiologically, 6 cases in CT and 2 cases of MRI. The false negative cases were 8 in clinical, 12 radiological, 2 in C T and 1 amongst MRI. **Conclusion:** C T scan of pelvis is highly accurate in picking up most of pelvic fractures (94.1%) in the present study and the study proves that C T scan being easily available in most of the secondary and tertiary care hospitals, should be the investigation of first choice. Its 3D pictures are very useful for the surgeons to understand the spatial displacement of fragments, especially in cases requiring surgical intervention. Contrast enhanced C T is also helpful in delineating soft tissue collections, extravagation of urine or hematoma / pus and can assist aspirations. MRI certainly gives better results than C T in the diagnosis of occult bony as well as soft tissue injuries. MRI is better in efficacy highly sensitive investigation especially in undisplaced fractures in osteoporotic patients but is costly, time consuming and not available in most of secondary care centers in developing countries, hence should be reserved for patients associated with soft tissue injuries or in cases where C T has failed in picking up a fracture.

Copyright © 2019, Sonali Sharma et al. This is an open access article distributed under the Creative Commons Attribution License, which permits unrestricted use, distribution, and reproduction in any medium, provided the original work is properly cited.

Citation: Sonali Sharma, Sudesh Sharma, Shashi Sudan, Ghanshyam Dev Gupta, 2019. "Clinical radiographic ct and mri evaluation of pelvic injuries in the elderly: A comparative analysis", International Journal of Current Research, 11, (01), 833-836.

## INTRODUCTION

The workload in the emergency wing of most of the secondary and tertiary care hospitals is constantly on the rise (Liew, 2003), due to increase in the motor vehicle accidents in the younger age group, however the incidence of injuries in the elderly is also on the rise because of the increase in life expectancy and population explosion (Pines, 2006). Injuries of pelvis are known for high incidence of morbidity and mortality, especially in poly trauma (10 – 50%) (Gilberto Jose Caca et al., 2017).

\*Corresponding author: Sudesh Sharma  
Professor Orthopaedics, GMC Jammu, 180001

In presence of heavy rush of serious patients with multiple fractures and compound injuries, the more benign looking, low energy injuries of the pelvis due to domestic falls, minor road hits, and tripping in the elderly patients, are usually taken lightly, especially by inexperienced junior resident doctors, who are likely to miss minimally displaced or undisplaced fractures of the pelvis due to poor visibility of osteoporotic bones as seen on wet films of portable Xrays, without view box. A high percentage of the pelvic fractures especially of posterior ring are likely to be missed (Chaumoitre et al., 2008), hence we felt the need for comparing all the diagnostic modalities and make definite protocol so as to minimize false negative cases and help elderly patients to get the best

treatment of their injuries and thus minimize the morbidity and mortality.

## MATERIALS AND METHODS

There were 131 patients of low energy trauma of pelvic fractures, however 25 patients did not fulfill the inclusion criteria, 12 patients refused to be a part of study and another 8 patients were lost to follow up. The remaining 86 patients of low energy pelvic trauma attending the emergency department of GMC Jammu from June 2015 to June 2017 were included in the study. All the patients were subjected to a detailed clinical examination (Assessment of hemodynamic status, localizing tender areas, bitrochanteric compression / distraction tests, noting obvious deformity, measure LLD, crepitus, ecchymosis in groin / SI, or any palpable hematoma), AP radiograph of Pelvis, computed tomography and MRI. Clinical examination was done by a senior orthopedic surgeon within one week of injury in routine OPD / Emg. and findings noted on prescribed proforma. The patient was then referred for C T and MRI to be reported by two senior radiologists independently. DEXA scan (T score= $\leq$  -2.5 was taken as osteoporosis) performed in all cases to know the severity of osteoporosis.

## RESULTS

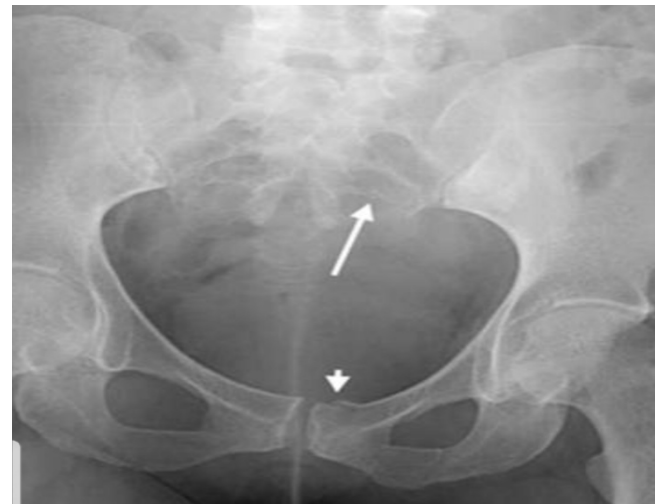The females dominated the study with 65 (75.5%) cases as compared to males 21 (24.5%). The age ranged from 50 to 90 with a mean age of 72.7 years.

**Mode of trauma:** Commonest mode of trauma was domestic ground falls in 62 (72.0%), followed by missing a step, tripping, fall from a height less than 1 meter, hit by a bull or any other animal or a two wheeler in low speed. Osteoporosis was detected in 78% cases overall, 95% cases with posterior ring fractures and 60% cases with anterior ring fractures had osteoporosis. MRI detected Posterior ring fractures in 70 (80.1%) cases and Anterior ring fractures in 76 (88.3%). C T scan picked up Posterior ring fractures in 62 (88.5%) out of 70 of MRI and Anterior ring fractures in 74 (97.3%) cases out of 76 of MRI. X rays showed Posterior ring fractures in 22 (31.4%) out of 70 of MRI and Anterior ring fractures in 58 (76.3%) cases out of a total of 76 of MRI. Clinically, Posterior ring fractures were diagnosed in 60 (85.7%) out of 70 cases diagnosed by MRI and Anterior ring in 58 (76.3%) out of a total of 76 of MRI cases. X Ray was overall sensitive in picking up (80%) fractures and useful in classifying injuries patho anatomically as per mechanism of injury but it lacked specificity. False negative cases with C T scan were 10, Anterior ring in 2 (2.7%) and posterior ring in 8 (11.5%) cases. False negative cases of X rays were 66, 18 (23.7%) in Anterior and 48 (68.6%) in Posterior ring fractures. False negative on Clinical diagnosis were 28 in number, Anterior ring 18(23.7%) and Posterior ring fractures 10 (23%).

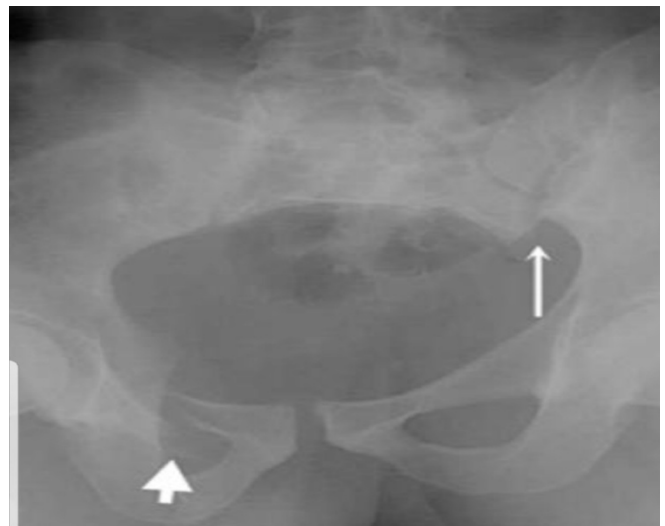
## DISCUSSION

There is high degree of morbidity associated with fracture of pelvis in elderly population<sup>5</sup>. The old age is known for the fragility of bones due to senile osteoporosis and the incidence of osteoporosis in females is still higher due to postmenopausal hormonal changes. The fractures of insufficiency require trivial trauma to be induced (Flint, 2010). These minimally displaced or undisplaced fractures are likely to be missed due to minimal

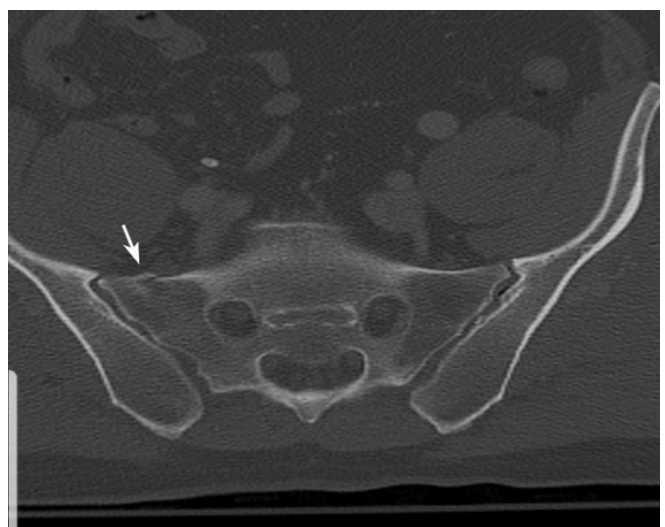signs and symptoms, more so when focused attention is not paid to diagnose them clinically or by suitable investigations.



(a)



(b)



(c)

**Fig 1a.1b(X Rays showing anterior & posterior ring fractures). And Fig.1c (C T scan showing impacted fracture of Rt. Sacral ala) in the same order as sent along with Manuscript entitled, "Clinical, Radiographic, CT, MRI evaluation of pelvic injury in elderly." For early publication as urgent. Pl. send Acceptance letter with names of all the authors immediately, so I send the due subscription. Regards.**

This prospective comparative study was undertaken to find out the best diagnostic tool to diagnose these fractures accurately so as to reduce the morbidity of these patients to a minimum. There were 86 patients of pelvic injuries included in the study. There was female dominance of 75.5%, as compared to males 24.5%. Preponderance of female patients was due to high degree of osteoporosis in females because of their lesser involvement in physical activities and reduced level of growth hormones in postmenopausal period (Krappinger *et al.*, 2010). The female dominance in the injuries of the pelvis, like our study, has been reported uniformly by many a studies (Liew, 2003; Chaumoitre, 2000; Breuil, 2008).

The age group ranged from 50 to 90 years, with the mean age of 72.7 years. The incidence of pelvic/hip fractures is as high as 70% in old age group due to increased vulnerability of fragile weak bones. Higher the age, higher is the incidence of fractures of pelvis, In the younger age, the incidence of pelvic fracture reported was 2-37/100 000, by age of 60 it goes to 92/100 000 and at the age of 85 it jumps to 446/100 000 (Morris, 2000). The incidence of osteoporosis in our series was as high as 78% on an average and it was 95% in posterior ring and 60% in anterior ring fractures. Higher rates of osteoporosis have also been reported by other workers (Chaumoitre *et al.*, 2000; Breuil *et al.*, 2008; Morris *et al.*, 2000). Similar high incidence of 85% has been reported by Nuchtern *et al.* 2015, in posterior ring fractures. Our results of 80.1% of posterior ring fractures (70 out of 86) detected by MRI match well with 80% (48 out of 60) of Nuchtern JV, *et al* 2015 (Nuchtern *et al.*, 2015). In our series, C T gave 88.5% successful results in detecting posterior ring fractures, even impacted or un displaced ones (Fig. 1c). It also gave detailed information about spatial rotation and morphology of broken fragments in hidden areas and also soft tissue collections and loose bodies. In their series C T had missed 8(17%) of posterior ring fractures and in our series C T could not pick up posterior ring fractures in 11.5% cases. and clinically in 10 (14.2%) of cases. Clinical accuracy as reported by Nuchtern JV *et al* was 100% for posterior ring fractures in their series. Conventional radiography in our series missed posterior ring fractures in 48(68.2%) cases. However good X ray films could pick up even minimally displaced posterior ring fractures (Fig. 1a,1b).

Overall, clinical accuracy of picking up posterior ring fractures matched reasonably well with C T sensitivity in our series as well as that of Nuchtern JV *et al* 2015. MRI proved to be superior to all the diagnostic tools, far superior to radiography and clinical. It was marginally superior to C T scan. It has a distinct superiority in diagnosing occult, undisplaced osteoporotic fractures of posterior pelvic ring in elderly patients. Considering easy availability of C T Scans in most of the secondary and tertiary care centres, less time consuming, cheaper, reasonably high degree of accuracy and its ability to pick up fluid / hemorrhage / urinary extravasation by contrast enhancement, combined along with focused clinical examination form, a safe reliable method for the accurate diagnosis of pelvic injuries of elderly. Conventional X-rays are useful as an urgent immediate bedside tool, for initial cursory screening, it gives good idea of classifying fractures as per mechanism of injury in nearly 80% of cases, provided one examines a well dried (not wet) film in a view box, otherwise one can miss even a simplest of injury. It is known to miss high percentage of posterior ring fractures in elderly, osteoporotic bones (Gilberto Jose Caca, 2017; Wajnberg, 2012; Morris, 2000).

## Conclusion

- Fracture Pelvis can be labelled as fracture of Insufficiency / Fragility
- There is female dominance as compared to males.
- The incidence of fracture goes higher with the advancement of age.
- Posterior ring fractures can easily be missed on conventional X rays.
- MRI gives the Best results out of all diagnostic modalities compared.
- C T Scan combined with meticulous clinical examination gives the best overall results and should be the protocol routinely followed to diagnose pelvic injuries of elderly population, so as to provide them the best medical care and minimize the morbidity and lessen chances of consumer forum and medico legal embarrassment.

**Conflict of Interest:** Nil

## Acknowledgements

We are thankful to all the patients who fully cooperated and gave their free consent to be a part of this study and allowed us to publish this data. We are also thankful to College Ethical committee who had no objection to this venture.

## REFERENCES

- Breuil V., Roux CH., Testa J. *et al.*, 2008. Outcome of osteoporotic pelvic fractures: An underestimated severity of 60 cases. *Joint Bone Spine.*,75(5):585-588 doi:
- Chaumoitre, K., Portier, F., Petit P. *et al.*, 2000. CT Imaging of pelvic injuries in poly trauma patients: *Journal de radiologie, Paris.*, 81:111-122.
- Flint L., Cryer HG. 2010. Pelvic Fracture: The last 50 years. *J Trauma. Sep.* 69(3):483-88(Medicine)
- Gertzbein SD., Chenoweth DR. 1977. Occult injuries of the pelvic ring. *Clin Orthop Relat Res.*, 128:202-207. (PubMed).
- Gilberto Jose Caca O Pereira, Erik Ribeiro *et al.*, 2017. Epidemiology of Pelvic ring fractures & injuries: Brazilian Society of Orthopaedics and traumatology May.
- Gotis-Graham I., McGuigan L., Diamond T. *et al.*, 1994. Sacral Insufficiency fractures in the elderly. *J Bone Joint Surg Br.*, 76(6):882 (PubMed)
- Krappinger D., Kammerlander, David JH., Blauth M. 2010. Low energy osteoporotic pelvic fractures. *Arch Orthop Trauma surg.* 130(9):1167-1175.(PubMed).
- Liew D., Liew D., Kennedy MP. 2003. Emergency department length of stay independently predicts excess inpatient length of stay. *Med J Aust.*, Nov 17;179 (10):524-526.
- Morris RO., Sonibare A., Green DJ. *et al.*, 2000. Closed Pelvic Fractures: characteristics outcomes in older geriatric wards. *Postgrad Med J.*, 76(900):.646-650.doi:Groth M, J
- Nuchtern JV., Hartel MJ., Henes FO., Groth MJ., Jauch SY., Haegele J., Briem D., Hoffmann M. *et al.*, 2015. Significance of clinical examination, C T, and MRI scan in the diagnosis of posterior pelvic ring fractures; Injury. Feb, Vol 46, Issue 2, pp 315-319.
- Peh WC., Khong PL., Yin Y. *et al.*, 1996. Imaging of pelvic insufficiency fractures. *Radiographics.* 16 (2):335-348. (PubMed).

Pines JM., Hollander JE., Localio AR., Metlay JP. 2006. The association between emergency department crowding and hospital performance. *Acad Emerg Med.*, Aug; 13(8)873-78.

Rommens PM., Wagner .D, Hofmann A. 2012. Osteoporotic fractures of the pelvic ring. *Zeitschrift fur Orthopadie und Unfallchirurgie*, 150,(3): e 107-18; quiz e 119-20.

Wajnberg, A., Wang, UH., Torres, L., Yang. S. 2012. *The journal of emergency*, 4(7): Elsevier,pp238-246.

\*\*\*\*\*