



ISSN: 0975-833X

Available online at <http://www.journalcra.com>

INTERNATIONAL JOURNAL
OF CURRENT RESEARCH

International Journal of Current Research
Vol. 11, Issue, 02, pp.1407-1410, February, 2019

DOI: <https://doi.org/10.24941/ijcr.34476.02.2019>

RESEARCH ARTICLE

BASIC APPROACH FOR PROSTHODONTIC REHABILITATION OF A HEMIMANDIBULECTOMY PATIENT: CASE REPORT

¹Dr. Nidhi Duggal, ²Dr. Pratibha, ³Dr. Sarabjit kaur and ⁴Dr. Deepika

¹Associate Professor and Head of Department of Government Dental College and Hospital Patiala, Punjab

³Assistant Professor of Government Dental College and Hospital Patiala, Punjab

^{2,4}Post Graduate student of Government Dental College and Hospital Patiala, Punjab

ARTICLE INFO

Article History:

Received 11th November, 2018

Received in revised form

07th December, 2018

Accepted 12th January, 2019

Published online 28th February, 2019

Key Words:

Dentulous, Hemimandibulectomy,
Rehabilitation,
Guide Flange Prosthesis.

Copyright © 2019, Nidhi Duggal et al. This is an open access article distributed under the Creative Commons Attribution License, which permits unrestricted use, distribution, and reproduction in any medium, provided the original work is properly cited.

Citation: Dr. Nidhi Duggal, Dr. Pratibha, Dr. Sarabjit kaur and Dr. Deepika. 2019. "Basic approach for prosthodontic rehabilitation of a hemimandibulectomy patient: Case report", *International Journal of Current Research*, 11, (02), 1407-1410.

ABSTRACT

Neoplastic lesions of the oral cavity mostly need surgical treatment which requires resection of the tongue, floor of the mouth, part of maxilla and mandible. Mandibulectomy & radical neck surgery involves the comprehensive loss of tissues and affiliated functions. So the rehabilitation of such patients is more challenging as there are many limitations like limited tissue coverage and retention, deviation towards resected site, loss of control on mandibular movements that alters the normal function. Dentulous patients can be retrained to achieve acceptable maxillomandibular relationship with the help of guide flange or ramp prosthesis. This paper describes the basic approach for the prosthodontic rehabilitation of a dentulous patient with hemimandibulectomy to achieve better function.

INTRODUCTION

Neoplastic lesions of the oral cavity are mostly surgically treated, which necessitates radical surgery of the tongue, floor of the mouth, part of maxilla and mandible that disturbs both form and function of normal stomatognathic system and also the facial contour⁽⁸⁾. Surgical resection such as segmental resection and hemimandibulectomy of the mandible results in physiological, functional and esthetic problems, especially if condylectomy has been performed as it causes the mandible to deviate toward the resected side with the loss of occlusal contacts and control on mandibular movements that alters the normal function. With the help of guide flange prosthesis, maxillomandibular relationship can be achieved in dentulous patients. The success of guide flange prosthesis depends upon how early it has been placed after surgery.

CASE REPORT

A 45-year-old man who had undergone hemimandibulectomy reported to the Department of Prosthodontics at Government Dental College & Hospital, Patiala. The chief complaint of the patient was difficulty in mastication due to missing teeth and no occlusal contacts.

*Corresponding author: Dr. Nidhi Duggal,

Associate Professor and Head of Department of Government Dental College and Hospital Patiala, Punjab.

Patient's history revealed that he was a tobacco chewer for 30 years. One and a half year back, he was diagnosed with squamous cell carcinoma of right buccal mucosa involving alveolus and lymph nodes. He had undergone right hemimandibulectomy with radical neck dissection and reconstruction with PMMF (pectoris major myocutaneous flap). As per Cantor and Curtis classification of resection, it was Type II resection. On extra oral examination, there was facial asymmetry with deviation of mandible towards the resected site (Fig-1a). Intraoral examination showed missing teeth 36, 43, 44, 45, 46, 47, no occlusal contacts and reduced mouth opening (approx 12mm) (Fig-1b). So Guide flange prosthesis was planned to restore and maintain the occlusal contacts on the non-affected side. Due to limited mouth opening, primary impressions of the non- defect side were made using irreversible hydrocolloid (alginate) in sectional trays (Fig-2a) and the casts were poured in dental stone to fabricate guide flange prosthesis. The casts were articulated in appropriate occlusion on mean value articulator (Fig-2b). The clasps were placed around 35 and 37 and the maxillary framework (continuous clasp) with buccal plate extending 7-10 mm laterally and superiorly on the buccal surfaces of bicuspid and molars using 20 gauge stainless steel wire was incorporated in the wax pattern. It was necessary to construct a maxillary framework with buccal plate with in design so that when the patient closed his mouth, the guidance flange attached to the

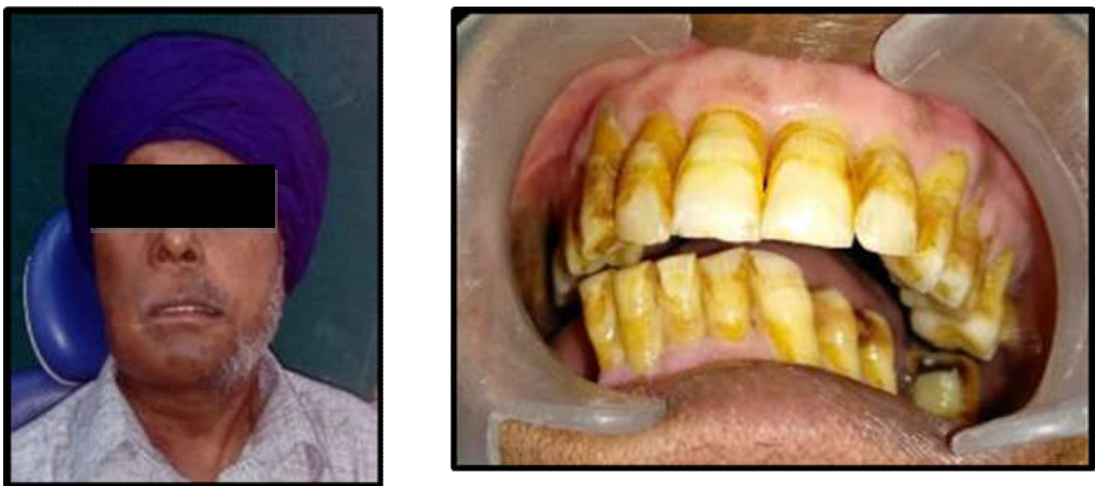

Fig-1(a,b). Preoperative(a) Extraoral view (b) Intraoral view

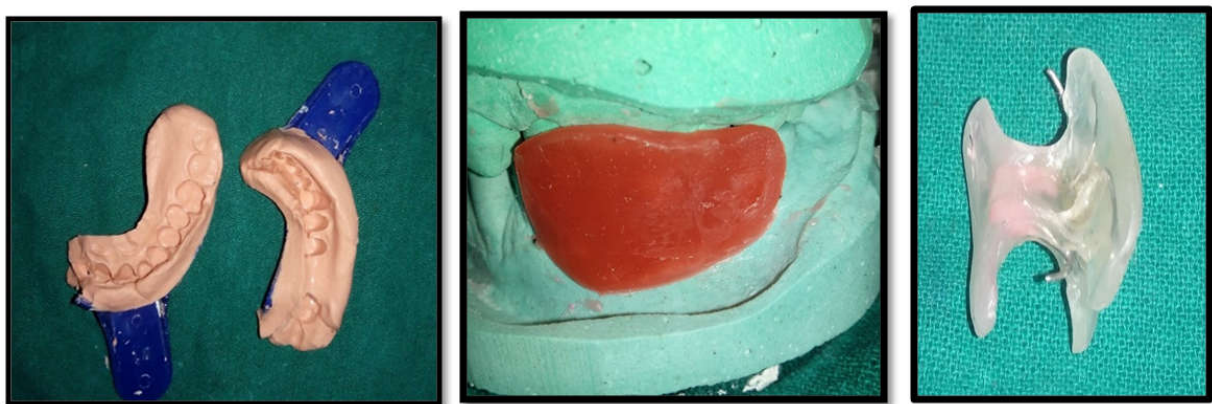


Fig 2 (a,b,c). (a) Sectional impressions of upper and lower arch of non-resected side (b) Articulated casts in occlusion with wax pattern (c) Guide flange prosthesis

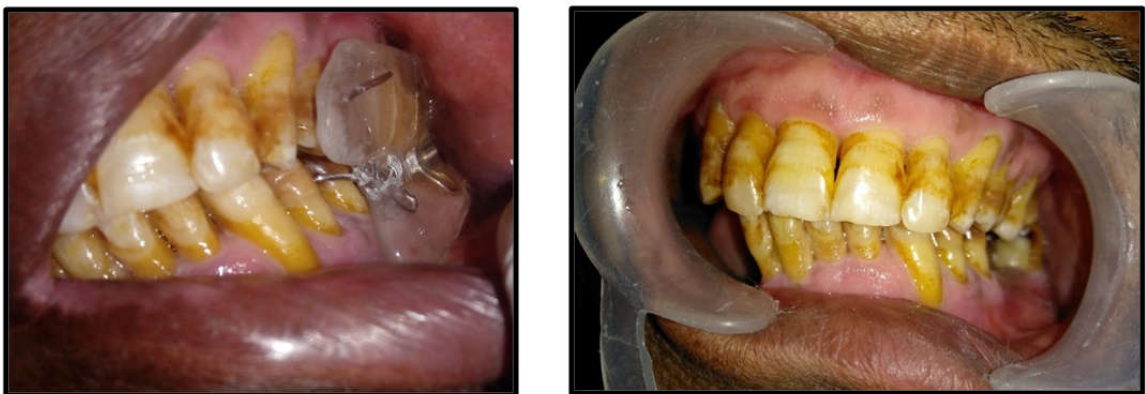

Fig 3(a,b). (a) Guide flange prosthesis in patient's mouth (b) Occlusion achieved after 4 months

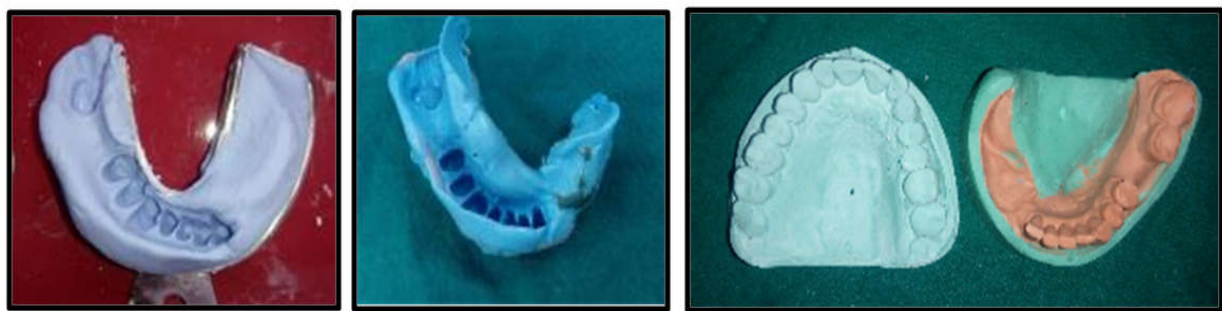


Fig. 4. (a,b,c): (a) Primary impression of mandibular arch (b) Final impression of mandibular arch (c) Final casts

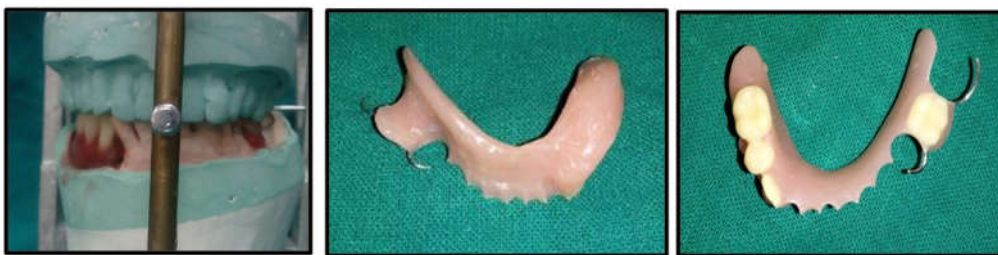

Fig 5 (a,b,c). (a)Artificial teeth arranged 36, 43,44,46 (b,c) final removable prosthesis

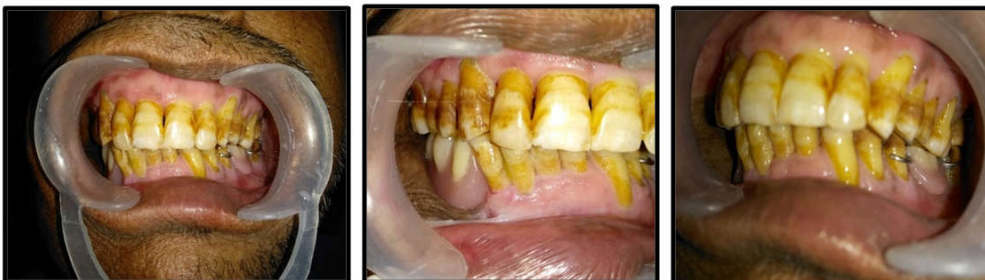

Fig. 6. (a,b,c) : Intraoral view of the patient with denture

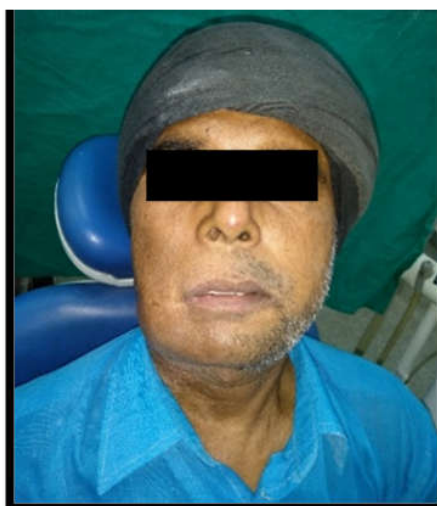

Fig. 7. Extra oral view after treatment

mandibular prosthesis did not traumatize the maxillary teeth and gingiva and served to resist the forces of arch contracture and maintain the maxillary teeth on the defect side in proper alignment until an acceptable position was achieved. The wax pattern was checked before processing and cured in heat cure acrylic resin. After curing, the appliance was finished & polished (Fig-2c) and checked intraorally (Fig-3a). The patient was advised to use the guide flange prosthesis throughout the day, except at night and during meals and instructed about the exercises i.e. maximum opening of the jaw followed by grasping the chin and moving the mandible away from the surgical side and straight opening and closing exercise to reduce trismus and avoid deviation. The patient was recalled after every 3 weeks to reevaluate the occlusal relationship. After 3 months, acceptable occlusion was achieved (Fig-3b). Patient's mastication was improved and he was able to move into maximum intercuspation by his own. For final removable prosthesis, primary impressions were made with irreversible hydrocolloid (Fig-4a) and poured with type III dental stone. A custom tray was fabricated with autopolymerising acrylic resin. To record lingual extension on non-defect side and the depth of the defect, border moulding was done with low fusing impression compound and final impression of lower arch was made with medium body polyvinyl siloxane impression

material (Fig-4b). Over the cast (Fig-4c) denture base with wax occlusal rim was fabricated. Centric relation was recorded, artificial teeth were arranged and waxed up partial denture was checked intraorally for occlusion, aesthetic and comfort (Fig-5a). Trial waxed partial denture was processed in heat cure acrylic resin and polished (Fig-5b, c). The prosthesis was checked intraorally for function, comfort & esthetics (Fig-6a, b,c). Oral hygiene instructions were given and the patient was advised for recall visit. On follow up visits after 1 month and 3 month, patient was functionally comfortable with the prosthesis.

DISCUSSION

Management of patients with hemimandibulectomy is a challenge to restore the function, comfort and esthetics. Prognosis will depend upon the remaining mandible and presence & condition of teeth (Beumer, 1996). Mostly the consequences after surgical procedures due to anatomical compromise are difficulty in mastication, speech and deglutition. The primary objective of Prosthodontics treatment is to achieve acceptable occlusion. Following surgical resection, remaining mandibular segment will retrude and deviate toward the resected side at vertical dimension of rest.

Also due to loss of muscle attachments at the surgical side, mandible rotation occurs in frontal plane. On opening and closing of mouth, deviation increases and follow an angular pathway (Beumer *et al.*, 1996). The most common difficulty in treating such patients is the deviation of mandible which makes difficult for the patient to perform normal function like closure of mandible and mastication. The loss of proprioception of occlusion on resected side causes the mandible to deviate into the unco-ordinated and imprecise movement. To achieve maxillomandibular relationship in edentulous patient, mandibular guidance therapy is effective. The success of mandibular guidance therapy varies and depends upon the nature of the surgical defect, early initiation of guidance therapy, patient co-operation and other factors (Beumer *et al.*, 1996). Guide flange prosthesis fabricated by two designs either guidance ramp in mandibular prosthesis with extension on buccal aspects of maxillary premolars and molars or guidance (palatal) ramp in maxillary prosthesis. These prosthesis are usually constructed of acrylic resin with wrought wire retainers or cast metal retainers. They serve only on interim basis until an acceptable occlusion can be established. If patient is not able to achieve acceptable maxillomandibular relationship by its own, there is need for guidance ramp in definitive prosthesis (Beumer, 1996). Defect can be restored with implant supported denture or conventional partial denture. Restoring the defect with implants was a good treatment option but considering the high reoccurrence rate of oral cancer, economic feasibility and requirement of multiple surgical procedures makes implants a lesser chosen option over mandibular guidance flange prosthesis (Singh, 2015). The literature shows various types of cast metal guidance prostheses which are effective in managing the mandibular deviation. But such appliances are complex, the technique is sensitive and costly and they require a number of patient visits. The acrylic guide flange prosthesis which is presented here is a simple and cost effective method for managing the mandibular deviation. The number of patient visits is also less as compared to the cast metal guidance prosthesis. The other advantage is its ease of adjustability (Sahu, 2010). Although it is true that even after successful guidance therapy where the patient was able to achieve intercuspal position efficient mastication may not be possible and occlusal equilibration is often necessary after guidance therapy was completed (Singh, 2015).

Conclusion

The prosthodontic aim and approach should focus not only on replacement of missing oral structures; it should also emphasize on improving quality of patient's life, restoring function and esthetics; provide support, stability and retention to the prosthesis along with preservation of remaining orofacial structures, either it is for single missing tooth or any maxillofacial defect. Outcome of treating such patient with hemimandibulectomy depends upon various factors. With the use of guide flange prosthesis and restoration of the defect with simple techniques, the prosthodontist may provide better function, esthetic and comfort to improve well-being of the patient.

REFERENCES

- Beumer, J. III, Curtis T.A., Marunick MT. 1996. Maxillofacial Rehabilitation. Prosthodontic and surgical consideration. St. Louis: Ishiyaku. *Euro America*.
- Cantor R., Curtis TA. 1971. Prosthetic managements of edentulous mandibulectomy patients. Part 1. Anatomic, physiologic and psychologic consideration. *J Prosthet Dent.*, 25:446-57
- Kar S., Tripathi A., Madhok R. 2015. Treatment outcome with guiding flange prosthesis in hemimandibulectomy patients: Case series of three patients. *Ann Maxillofac Surg.*, 5:266-70
- Lingeswar D., Appadurai R.S., swedheni U., Padmaja C. 2017. Prosthodontics Management of Hemimandibulectomy Patients To Restore Form And Function – A Case Series. *World J Clin Cases.*, 5(10):384-389
- Sahu SK. 2010. Mandibular Guide Flange Prosthesis following Mandibular Resection: A Clinical Report. *Journal of Clinical and Diagnostic Research.* October; 4: 3266-3270
- Singh B., Sinha N., Sharma R., Parekh N. 2015. Non-Surgical Correction of Mandibular Deviation and Neuromuscular Coordination after Two years of Mandibular Guidance Therapy: A Case Report. *J Clin Diagn Res.*, Nov;9(11)
- Taylor TD. 1997. Clinical maxillofacial prosthetics. Quintessence Publishing Co, Illinois, p. 171-188
