



ISSN: 0975-833X

Available online at <http://www.journalcra.com>

International Journal of Current Research
Vol. 11, Issue, 08, pp.6119-6121, August, 2019

DOI: <https://doi.org/10.24941/ijcr.35893.08.2019>

INTERNATIONAL JOURNAL
OF CURRENT RESEARCH

RESEARCH ARTICLE

BILATERAL SYMMETRICAL NONSYNDROMIC CANINE- PREMOLAR TRANSPOSITION IN MAXILLARY ARCH:-A REPORT OF A RARE CASE

¹*Dr. Umapathy Thimmegowda, ²Dr. Praveen M.N., ³Dr. Amrutha, B., ⁴Dr. Prasanna Kumar Bhat and ⁵Dr. Ashwini Chikkanayakanahalli Prabhakar

¹Professor, Dept of Pedodontics and Preventive Dentistry, Rajarajeswari Dental College and Hospital, Bangalore- 74

²Reader, Dept of Orthodontics and Dentofacial Orthopaedics, KLE Society's Institute of Dental Sciences, Bangalore-560022

³Senior Lecturer, Dept of Pedodontics and Preventive Dentistry, Rajarajeswari Dental College and Hospital, Bangalore- 74

⁴Reader, Dept of Pedodontics and Preventive Dentistry, Rajarajeswari Dental College and Hospital, Bangalore- 74

⁵Shree Vinayaka Dental Clinic, #119 Sri Vinayaka Layout, 2nd Stage, Vijayanagar, Bangalore-40

ARTICLE INFO

Article History:

Received 20th May, 2019

Received in revised form

26th June, 2019

Accepted 28th July, 2019

Published online 31st August, 2019

ABSTRACT

Tooth transposition is a disturbance of tooth eruption and is defined as change in the position of two adjacent teeth within the same quadrant. Tooth transposition is a rare condition and is usually related to eruption disturbances of the teeth and to the subsequent abnormal occlusal relationships. Transposition can be complete when the position of affected teeth is totally transposed or incomplete when only the crowns are transposed, while the roots remain in normal position. The present article reports a rare case where there is complete bilateral transposition of canine.

Key Words:

Dental Anomalies,
Transposition,
Canine, Premolar.

*Corresponding author:

Dr. Umapathy Thimmegowda

Copyright © 2019, Umapathy Thimmegowda et al. This is an open access article distributed under the Creative Commons Attribution License, which permits unrestricted use, distribution, and reproduction in any medium, provided the original work is properly cited.

Citation: Dr. Umapathy Thimmegowda, Dr. Praveen M.N., Dr. Amrutha, B., Dr. Prasanna Kumar Bhat and Dr. Ashwini Chikkanayakanahalli Prabhakar. 2019. "Bilateral symmetrical nonsyndromic canine- premolar transposition in maxillary arch:-A report of a rare case", *International Journal of Current Research*, 11, (07), xxxxxx-xxxxxx.

INTRODUCTION

Tooth transposition is defined as the positional interchange of two neighboring teeth and especially of their roots, or the development or eruption of a tooth in a position normally occupied by a non-neighboring tooth (Peck L 1995). Tooth transposition is a peculiar type of ectopic eruption in which each ectopic tooth changes the normal order of the tooth sequence in the dental arch (Onyeaso CO 2006). The etiology of tooth transposition could be the result of genetic influences in a multifactorial model involving mechanical interference, trauma, tooth buds in altered position, early tooth loss, and long-term retention of deciduous teeth (Mirian Nakane Mastumoto 2018). Maxillary teeth are more frequently transposed teeth as compared to mandibular teeth. Among the maxillary teeth permanent canine is the most frequently involved tooth in transposition usually between the first premolar and less often with lateral incisor (Sherazburki, 2004). Transpositions were more commonly observed in males while some studies reported the female predilection.

A hypothesis was proposed that gender-related genes may be responsible for tooth transposition but this is yet to be confirmed. Chattopadhyay and Srinivas (Chattopadhyay A 1996) stated that higher female predilection might be associated with higher number of females seeking orthodontic treatment (Nagaveni et al., 2015). Unilateral tooth transpositions have been reported far more frequently than bilateral and left side is common site of occurrence than the right side. Only one case of asymmetric transposition in both arches was found in the literature, involving maxillary canine and the first premolar on the right side and mandibular canine and the lateral incisor on the left side (Sherazburki, 2004). Transposition can be detected easily by means of clinical examination and palpation of the area of the roots of the corresponding teeth. For confirmatory diagnosis, a radiographic examination is required. Intraoral periapical radiographs and panoramic radiographs are more useful. The treatment of these patients frequently requires multidisciplinary treatment planning to achieve a long-term aesthetic and functional result.

CASE REPORT

A 38 year old female patient was reported to private clinic with a chief complaint of missing teeth and space present in upper anterior region. The patient was in good general health, medical and dental history were not significant hence indicated no contraindications to dental treatment. A clinical and oral examination showed missing upper canine bilaterally in upper arch. Thorough examination revealed the presence of canine between the first and second premolar on both sides which was then confirmed with OPG (Fig1). Diagnosis was transposition of canine bilaterally in upper arch. Missing teeth in relation to upper left third molar was seen with ectopically erupting upper right third molar. In the lower arch history and clinical examination revealed missing lower left central incisor, lower right central and lateral incisor due to periodontal problem and third molars. Treatment plan was to recon tour the maxillary canines in the upper arch for esthetics. Since the patient did not agree for extraction of sound teeth, recon touring was done. Accordingly crowns of upper canine and first premolar will be recon toured followed by closure of formed space orthodontically. In the lower arch, since incisors were missing, replacement of missing teeth were planned with removable, fixed partial denture or implants.

DISCUSSION

Tooth transposition is a rare positional anomaly that causes problems in both esthetic and functional aspect. Tooth transposition is defined as the positional interchange of two neighboring teeth and especially of their roots, or the development or eruption of a tooth in a position normally occupied by a non-neighboring tooth. A meta-analysis was done on prevalence of tooth transposition and the result obtained was 0.33% of prevalence of tooth transposition (Moschos, 2010). Maxillary tooth transposition was found to be higher compared to mandibular tooth transposition. The reason could be high bone density of the mandible resulting in prohibition of the phenomenon of tooth transposition, and there is higher incidence of transposition in maxillary arch as maxillary bone is porous in nature. The most common type of tooth transposition in the mandibular arch takes place between the canines and lateral incisors, where the bone is more porous than in the posterior area. Contrast to this the lower density of bone in the maxilla may enhance the incidence of tooth transposition as well as the variety of types of transposition like between canines and first premolars, between canines and lateral incisors, between central and lateral incisors (Peck *et al.*, 1998, Sandham, 1985, Shapira, 2001, Thiander, 1968, Plunkett *et al.*, 1998). Unilateral tooth transpositions have been reported commonly than bilateral and left side is common site of occurrence than the right side. Only few cases of asymmetric transposition in both arches was found in the literature, involving maxillary canine and the first premolar on the right side and mandibular canine and the lateral incisor on the left side (Sherazburki BS 2004).

Clinical significance of ectopic canine: The permanent canines are a key tooth in the maxillary arch that defines the smiles of an individual. The canines are the cornerstone of the arch and it has the longest eruption passage that gets influenced by local and general etiological factors easily. The initial calcification of the crowns starts around 4–5 months of age and eruption occurs around 11–13 years of age.

Canine gets displaced buccally or palatally or may sometimes get impacted. Early intervention is the best suited to manage canine eruption patterns. Once erupted ectopically, they possess a great challenge for a clinician to reposition them back into their appropriate position (Thirunavukkarasu *et al.*, 2015). Diagnosis and treatment of ectopically erupting permanent maxillary canines requires timely management by the orthodontist. Orthodontic treatment is justified because ectopic canine teeth can migrate in the jaw bone and may damage the adjacent teeth roots and bone. Orthodontic treatment is also justifiable for aesthetic reasons. Internal or external root resorption of teeth adjacent to the ectopic canine is the most common sequel. Malocclusion with severe crowding is difficult to treat without extraction. Non-extraction treatment of ectopic canines can compromise the patient's profile (Avesh Sachan 2012). In the present case there is bilateral transposition of canine and first premolar. Causative factors of transposition include genetics, retained primary teeth, deviation of eruptive path of permanent teeth and abnormality in the sequence of eruption of permanent teeth. The maxillary canine to first premolar transposition was determined to be an anomaly resulting from genetic influences within a multifactorial inheritance model. According to Peck *et al.* evidence was found to suggest that the maxillary canine to first premolar transposition is genetically influenced, which has been proven by observations such as moderate rate of bilateral occurrence, sex-associated frequency differences, increased prevalence of additional dental anomalies (Peck, 1995). Transposition is very rare in the deciduous dentition. The etiology of tooth transposition has been the subject of much controversy and is still not has been completely understood. Several theories have been proposed to explain the phenomenon. Multifactorial genetic factors an interchange in the position of the developing dental lamina of the involved teeth and even trauma to the deciduous teeth in which dilacerations of the permanent incisor root was found have all been suggested as causes for transposition of teeth (Ciarlantini, 2007).

Tooth transposition is often accompanied by several congenital dental disturbances such as peg-shaped lateral incisors, hypodontia, ankylosed milk teeth, severely rotated teeth, and dilacerated teeth (Shapira Y 1989). It has been reported that 18.5% of the individuals with transposition to have one or more missing teeth, excluding third molars. Lateral incisor was the most frequently missing tooth (14%). This was followed by the maxillary (6%) and the mandibular (3%) second premolar. Small sized lateral incisors were detected in 9% of the cases with transpositions. 32% individuals had retained milk teeth, 45% had severely rotated maxillary canines and 14% had impacted third molar (Shapira, 2001).

Treatment considerations: Early diagnosis of a transposition is extremely important and has a great influence on prognosis. When the alteration is detected early, interceptive procedures including extraction of deciduous teeth and placement of eruption guides for the permanent teeth may be performed, thus preventing complete development of the anomaly. On the other hand, when transposition is detected at a later stage, orthodontic treatment planning and intervention must be addressed. Upper canine premolar transposition in adult patients allows consideration of several treatment options, with or without extraction of the premolar (Filhoa *et al.*, 2007). In nonextraction cases, the position of transposed teeth is maintained without restoring their natural tooth position.

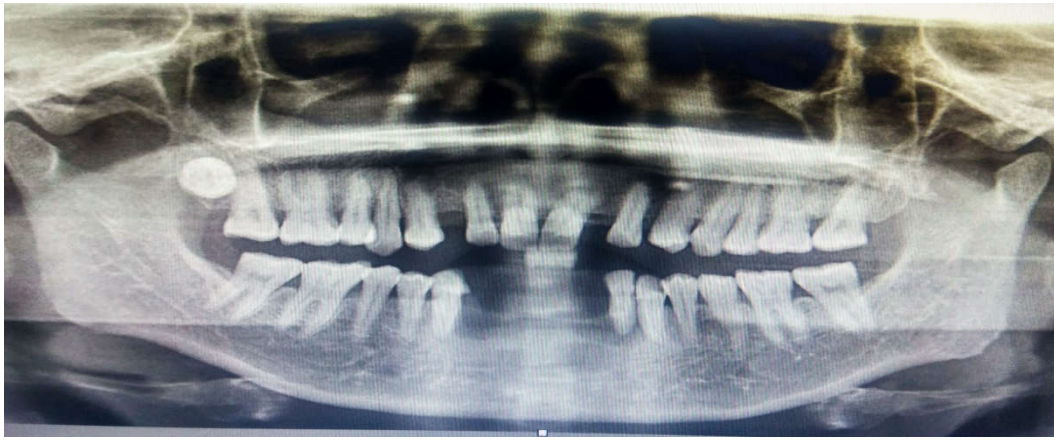


Fig. 1.

However, the upper canine-premolar transposed order provides esthetic and functional considerations. The differences in the size, shape, and tooth color between canine and premolar sometimes cause anterior esthetic problems. The gingival contour of the premolar is lower relative to the canine, requiring a periodontal gingival recontouring procedure. The palatal cusp of the transposed premolar might cause functional interference. The size and shape of premolar are completely recontoured to resemble a canine after root canal treatment (Shapira, 1989, Kurrodaa, 2005). Basically, when treating transpositions, especially maxillary canine and first premolar, many factors that affect the treatment results must be considered, such as esthetics, occlusion, treatment period, patient comfort, patient cooperation, and periodontal support. For the achievement of optimal function and esthetics in cases with tooth transposition requires the utmost care in the design of the treatment.

Conclusion

Tooth transposition is a relatively rare developmental anomaly of the teeth characterized by a positional interchange of a permanent tooth leading to distortion in the alignment of the affected segment, a midline shift, and malocclusion of the teeth. The most suitable treatment depends on the occlusion, level of dental crowding, aesthetics, position of the radicular apices, and specific needs of the patient.

REFERENCES

- Peck L., Peck S. 1995. Classification of maxillary tooth transpositions. *Am J Orthod Dentofacial Orthop.*, 107:505–517.
- Onyeaso CO., Onyeaso AO. 2006. Occlusal/dental anomalies found in a random sample of Nigerian schoolchildren. *Oral Health Prev Dent.*, 4:181–186.
- Mirian Aiko Nakane Matsumoto, Maria Bernadete Sasso Stuani Dental Press J Orthod. 2018 Jan-Feb;23(1):97-107.
- SherazburkiBS, Saharmunawwar, Pakistan Oral & Dent. Jr. 2004 Jun; 24 (1).
- Chattopadhyay A., Srinivas K. 1996. Transposition of teeth and genetic etiology. *Angle Orthod.*, 66:147-52.
- Nagaveni et al. 2015. Nigerian Journal of Experimental and Clinical Biosciences., Jan-Jun; 3(1):52-56.
- Moschos AP., Maria Chatzoudib, Eleftherios GK. 2010. Prevalence of tooth transposition: A meta-Analysis. *Angle Orthodontist.* 80(2).
- Peck S., Peck L., Kataja M. 1998. Mandibular lateral incisor-canine transposition, concomitant dental anomalies, and genetic control. *Angle Orthod.*, 68:455–466.
- Sandham A., Harvie H. 1985. Ectopic eruption of the maxillary canine resulting in transposition with adjacent teeth. *Tandlaegebladet.* 89:9–11.
- Shapira Y., Kuflinec MM. 2001. Maxillary tooth transpositions: characteristic features and accompanying dental anomalies. *Am J Orthod Dentofacial Orthop.*, 119: 127–134.
- Thilander B., Jakobsson SO. 1968. Local factors in impaction of maxillary canines. *Acta Odontol Scand.* 26: 145–168.
- Plunkett DJ., Dysart PS., Kadros TB., Herbison GP. 1998. A study of transposed canines in a sample of orthodontic patients. *Br J Orthod.*, 25:203–208.
- Thirunavukkarasu R., Sriram G., Satish R. 2015. The orthodontic management of ectopic canine *J Pharm Bioallied Sci.*, Aug; 7(Suppl 2): 749–751.
- Avesh Sachan, Chaturvedi TP. 2012. Orthodontic management of buccally erupted ectopic canine with two case reports. *Contemp Clin Dent.*, Jan-Mar; 3(1): 123–128.
- Ciarlantini R, Melsen B. 2007. Maxillary tooth transposition: Correct or accept? *Am J Orthod Dentofacial Orthop.*, 132:385–94.
- Shapira Y, Kuflinec MM. 1989. Maxillary canine-lateral incisor transposition-Orthodontic management. *Am J Orthod Dentofac Orthop.*, 95:439-44.
- Filhoa LC., Cardoso MA., Anc TL., Bertozd FA. 2007. Maxillary Canine—First Premolar Transposition. *Angle Orthod.* 77(1):167 – 175.
- Kurrodaa S., Kurodab Y. 2005. Nonextraction treatment of upper canine-premolar transposition in an adult patient. *Angle Orthod.*, 75:472-477.
