



ISSN: 0975-833X

Available online at <http://www.journalcra.com>

International Journal of Current Research
Vol. 11, Issue, 09, pp.7385-7390, September, 2019

DOI: <https://doi.org/10.24941/ijcr.36759.09.2019>

INTERNATIONAL JOURNAL
OF CURRENT RESEARCH

REVIEW ARTICLE

OPEN BITE: AN OVERVIEW

¹Vijeta Angural and ²Sandhya Jain

¹MDS, Department of Orthodontics and Dentofacial Orthopedics, Government College of Dentistry, Indore, MP, India

²Professor and Head Department(s) and institution(s): Department of Orthodontics and Dentofacial Orthopedics, Government College of Dentistry, Indore, MP, India

ARTICLE INFO

Article History:

Received 17th June, 2019

Received in revised form

28th July, 2019

Accepted 25th August, 2019

Published online 30th September, 2019

ABSTRACT

Anterior open bite cases are very difficult to treat satisfactorily because of their multifactorial etiology and their very high relapse rate. Dependent on the origin of the anterior open bite malocclusion and the patient's age, there are several treatment possibilities ranging from deterrent appliances, high-pull headgear, fixed appliances with and without extractions to orthognathic surgery, and skeletal anchorage with miniplates or minis crews. This article reviews and describes the prevalence, classification, etiology, treatment strategies and stability of open bite malocclusion.

Key Words:

Open bite,
Etiology,
Treatment and Stability

**Corresponding author: Vijeta Angural*

Copyright ©2019, Vijeta Angural and Sandhya Jain. This is an open access article distributed under the Creative Commons Attribution License, which permits unrestricted use, distribution, and reproduction in any medium, provided the original work is properly cited.

Citation: Vijeta Angural and Sandhya Jain, 2019. "Open bite: an overview of literature", *International Journal of Current Research*, 11, (09). 7385-7390.

INTRODUCTION

Malocclusion can occur in three planes of space i.e. sagittal, transverse and vertical plane. In vertical plane, a condition where there is absence of vertical overlapping of the mandibular anteriors by maxillary anteriors is termed as open bite. Caravelli coined the term "open bite". Subtelney and Sakuda (Subtelny, 1964) defined open bite as open vertical dimension between the incisal edges of the maxillary and mandibular anterior teeth. Some use the term *open bite tendency* as a synonym for overlap. Contact occurs when the anterior and posterior teeth touch opposing structures in centric occlusion.

Synonyms: Apertognathia.

Prevalence: According to Cozza P et al. (2005) prevalence in the population ranges from 1.5% to 11%. In the US population, differences in prevalence were detected between the different ethnicities, with 3.5% occurring in Caucasian children and 16.5% in Afro-descendant children. Worms (Worms, 1971) in his study claimed, large decrease in prevalence of open-bite noted at the ages of 10 to 12 years.

Classification

According to Nanda (Nanda, 2005):

- Dentoalveolar open bite
- Skeletal open bite

According to Frank W. Worms (Worms, 1971):

- Simple open-bite: when it existed from canine to canine but did not include the premolar and was 1 mm. or greater in centric relation.
- Complex open-bite: open-bite existing from premolar to premolar, but not including molars.
- Compound open-bite: An open-bite that included molars

On the basis of location: Dentoalveolar open bite can further be classified as:

- Anterior open bite
- Posterior open bite

Characteristics of dental open bite

- Normal craniofacial pattern
- Proclined upper anterior teeth.
- Under Erupted anterior teeth.
- Normal or slightly excessive molar height.
- Mesial inclination of posterior dentition.
- Divergent of upper and lower occlusal planes.
- No gummy smile.
- No vertical maxillary excess.
- Habits like thumb, finger sucking and tongue thrusting.
- There may be spacing between anteriors.
- The patient may have a narrow maxillary arch, due to lowered tongue posture due to a habit.

Skeletal Open Bite: An open bite associated with a divergence of skeletal planes is known as skeletal open bite. This type of malocclusion generally does not improve with growth. The characteristics of a skeletal open bite occur throughout the craniofacial region. It is also known as “Long Face Syndrome”.

According to Sassouni (Sassouni, 1969)

Skeletal open bite positional deviations

- The four bony planes of the face are steep to each other
- The posterior vertical chain of muscles is arcuate, and the masseter muscle is posterior to the buccal teeth, thus creating a mesial component of forces responsible for the dental protrusion.
- The cranial base angle and the gonial angle are obtuse.

Dimensional Deviations

- The total posterior facial height (S-Go) tends to be half the size of the anterior total facial height (N- Me).
- The lower anterior facial height exceeds the upper anterior facial height.
- The ramus is short with an antegonial notch at its lower border.
- The mandibular symphysis is narrow antero posteriorly and long vertically.
- Maxillary base: Upward tipping of the forward end of the maxillary base and downward tipping of the posterior end of the maxillary base (anticlockwise).
- There is a lack of chin mental protuberance development.
- The palatal vault is high and narrow and anteriorly tipped-up palatal plane and divergent occlusal planes.
- Nasal apparatus are narrow.
- The cranium is sometimes dolichocephalic.
- Distal condylar inclination.
- Large interlabial gap and gummy smile present.

Etiology

Etiology of AOB is complex, multifactorial and largely unknown. AOB has skeletal and dental components and often the two occur together in the same individual (Cangialosi, 1984).

Causative factors include

- Habits,
- Hereditary factors
- Aberrant skeletal development
- Airway obstruction
- Stage of development
- Iatrogenic factors
- Neurological disturbances,
- Muscular dystrophy
- Disproportionately large tongue
- Temporal mandibular joint derangements and pathological factors.

Habits

Sucking Habit: Thumb and finger-sucking habits beyond 3.5 years of age. It is here that the severe open-bites, buccal cross-

bites, and marked maxillary protrusions are encountered. The AOB arises by a combination of interference with normal eruption of incisors and excessive eruption of posterior teeth. How much the teeth are displaced depends on duration, frequency and intensity of the sucking habit (Graber, 1989).

Tongue Posture: Regarding the tongue habits, the vertical position of a tooth is known to be determined by the equilibrium between forces that produce eruption and those that oppose it.⁸ Forward positioning of the tongue or a disproportionately large tongue and its resultant posture is believed to mechanically interfere with anterior teeth eruption thus causing and maintaining AOB.¹ The pressure from the tongue on the incisors if not equally countered by forces from the lips may cause outward displacement of those teeth thus accentuating AOB malocclusion (Proffit, 1978). Both *Proffit (Proffit, 1978)* and *Ngan and Fields (Ngan, 1991)* consider tongue thrust swallow as a result of displaced incisors and not the cause. They argue that tongue thrust swallowing has a too short a duration to have an impact on tooth position.

Airway Obstruction: In the airway obstruction cases, it is known that excessive amounts of adenoid tissue may obstruct the nasopharyngeal cavity and prevent proper naso-respiratory function. This may force an individual to breathe through the mouth. During mouth breathing, the mandible and the tongue are lowered, and the head is extended, if these postural changes are to be maintained, the vertical equilibrium will be disrupted causing over eruption of the posterior teeth (Subtelny, 1964).

Abnormal Skeletal Growth Pattern: Anterior open bite malocclusion can arise from abnormal skeletal growth pattern. *Bjork (Bjork, 1969)* has suggested the term mandibular growth rotation to explain changes in the vertical relationship of the arches. He suggested that the condyle is the primary growth center of the mandible and that the amount of vertical condylar growth has to equal vertical dentoalveolar growth or mandibular rotation will occur. This, in turn, affects overbite relationships.

Neurological disturbances and muscular dystrophies: Neurological disturbances and muscular dystrophies that lead to decrease in tonic muscle activity may allow the mandible to drop downward away from the rest of the facial skeleton. This subsequently disturbs the equilibrium of the posterior teeth resulting in AOB (Subtelny, 1964).

Stage of development: Incomplete eruption of incisors during early stage of individual's development (mixed dentition stage) has been associated with high prevalence of AOB malocclusion (Nanda, 2005).

Pathological Conditions: In Le forte 1 and condylar neck fractures cases the direction of displacement of the bony fragments leads to malocclusion (Wanjau, 2010). Bilateral condylar fractures may be followed by displacement of the ramus superiorly by the masticatory muscles. This subsequently result in premature contact of the posterior teeth and AOB deformity (Loukota, 2003).

Disproportionately Large Tongue: It is well accepted that tongue size and position affect skeletal and dental components. Macroglossia, or enlarged tongue, is thought to be an etiologic factor in open bite, bimaxillary protrusion, and dental arch spacing, and it might cause instability after orthodontic treatment. A partial glossectomy to reduce tongue size can be useful in treating these problems (Wolford, 1996).

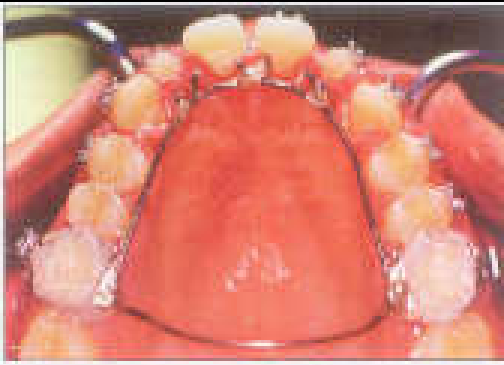


Figure 1. Habit breaking appliance with lingual spurs

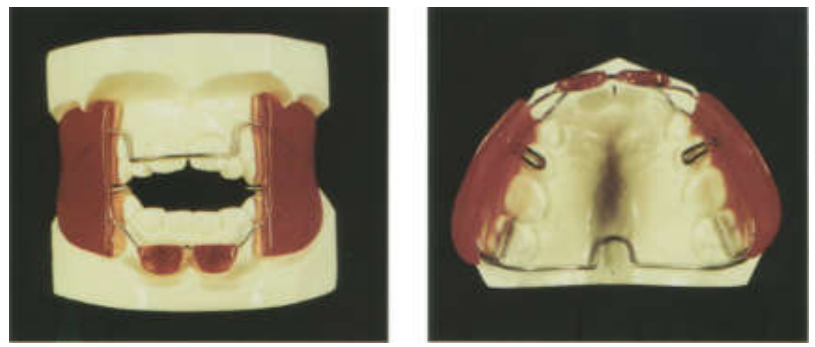


Figure 2. Showing Fränkel's function regulator 4

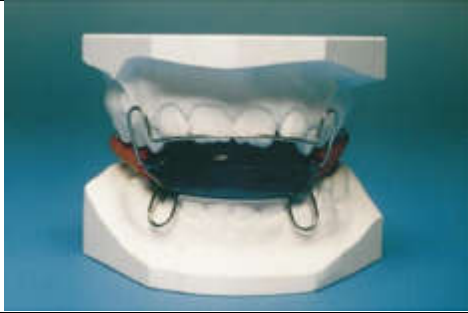

Figure 3. Shows the elastic activator.

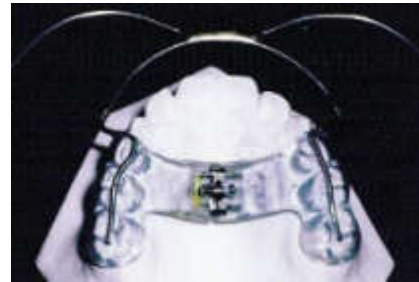

Figure 4. Showing Modified Thurow appliance with facebow for attachment high pull headgear

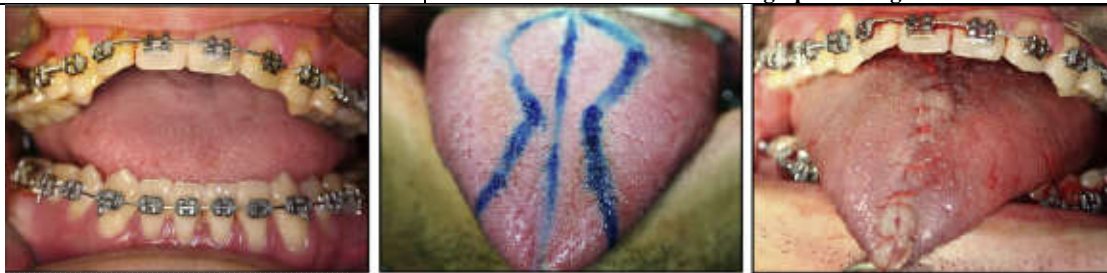

Figure 5. Showing Glossectomy procedure with Keyhole technique

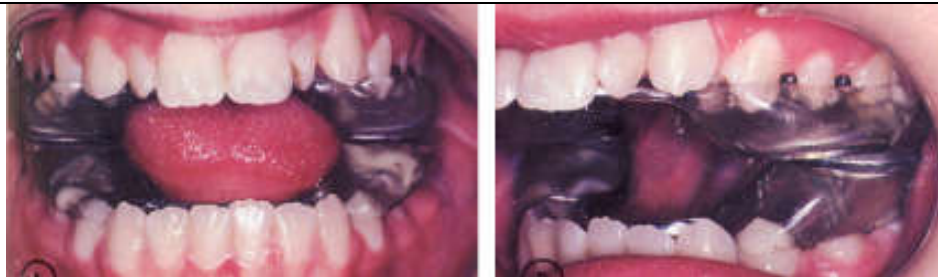

Figure 6. Showing Active Vertical Corrector (AVC)

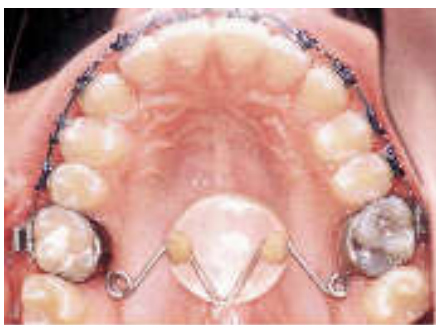

Figure 7: Vertical holding appliance having transpalatal arch with an acrylic pad

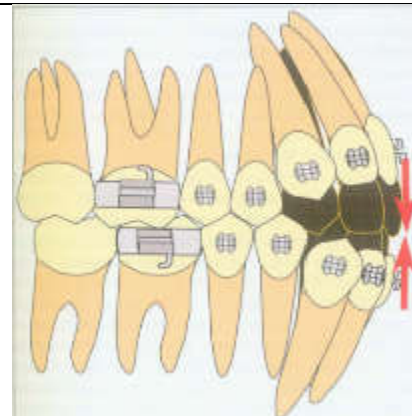


Figure 8: Showing force system of anterior vertical elastics (equal and opposite forces)

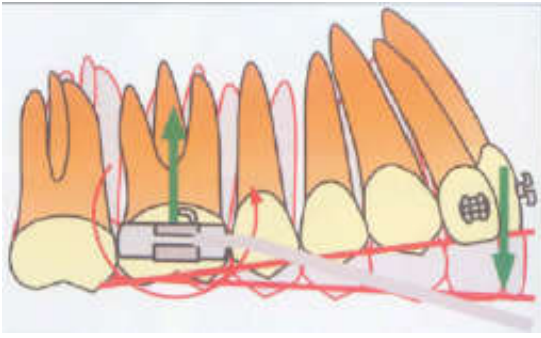


Figure 9. Showing Extrusion arch force system producing a one-couple force system with an anterior extrusive and a posterior intrusive force, the couple on the molar produces a tip forward moment

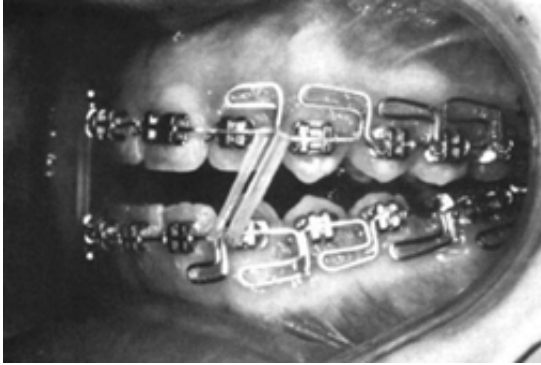

Figure 10. Showing correction of anterior open bite with Multiloop Edgewise Archwire

In conclusion, it is clear that several factors are associated with the etiology of AOB and that cases related to habits (especially the digit and tongue habits) are the most common.

Treatment: Treatment strategies should report the cause of malocclusion. During the clinical examination, environmental factors that contribute to a patient's malocclusion, such as thumb sucking or finger sucking, should be identified and then eradicated. According to the patient's age, the different approaches for proper treatment of anterior open bite can be separated.

Treatment of thumb sucking: Children should be encouraged by their parents to stop the sucking habit before the age of 4 years (Proffit, 2000). If a child sucks a thumb or finger during sleep, mechanically obstructing the hand with a sleeping gown may be helpful. If initial attempts are unsuccessful, an intraoral appliance like tongue crib that acts as a mechanical barrier and reminder can be helpful and it needs to be left in place for 3–6 months after the habit has ended (Villa, 1997).

Treatment of airway obstruction: Procedure that promote better breathing through the nose (turbinate surgery, adenoid and tonsil removal, allergy treatment) may help to re-establish normal growth patterns (Reichert, 2014). Because the direct relationship between anterior open bite and mouth-breathing as a result of chronic respiratory obstruction has not been proven, prolonged mouth breathing may not necessarily be the main etiological factor for malocclusion (Linder-Aronson, 1986).

Treatment of tongue thrusting: Patients with tongue thrusting can be treated effectively in a same manner as that used for patients who have digit sucking habit, although different appliances such as the habit appliance with lingual spurs (Figure 1) or cribs have been suggested. Myofunctional

appliances, are also effective in treating tongue thrusts. The types of functional appliances includes the Frankel regulator, bionator, activator, and twin blocks.

Functional regulator4 appliance (fr4): Rolf Fränkel believed that correction of the faulty postural activity of the orofacial musculature might help correct the associated skeletal deformity, so he used FR4 appliance (Figure 2) in conjunction with lip seal training to achieve over bite correction and elimination of the skeletal dysplasia (Frankel, 1980). A randomized clinical trial conducted by Erbay et al. (1995) reported that the growth direction of the mandible could be changed to a upward and forward direction by Fränkel 4 therapy.

Elastic activator: It is a modified activator (Figure 3) for treatment of open bite cases. The intermaxillary acrylic of the lateral occlusal zones is replaced by elastic rubber tubes. By stimulating orthopaedic gymnastics (chewing gum effect), the elastic activator intrudes upper and lower posterior teeth.

Headgear: Occipital and vertical pull headgears have an intrusive force on the maxillary molars. In addition to the intrusive component of force, occipital headgears also have a distal force. This force system is ideal in patients with Class II Hyper divergent growth pattern. To obtain a skeletal effect, it must be worn 12-14 hr/day with a force of 10-16 oz (400-450g) per side (Lentini-Oliveira, 2007).

Modified throw appliance: This modified appliance has an acrylic occlusal splint and an expansion screw, (Figure 4) which guides the vertical force against the posterior teeth and the alveolar process (Stuani, 2005). An expansion screw in the palate is incorporated to prevent and treat a posterior bilateral crossbite during the use of this appliance

Treatment of macroglossia: If macroglossia is diagnosed, surgical resection by Keyhole-shaped technique (Figure 5) may be performed to reduce the volume of the tongue. The open bite can then be corrected by retraction of the anterior teeth. Due to the morbidity of the procedure, with potential sequelae in taste sensation, and motor dysfunction, this approach is not often chosen (Wang, 2003).

Posterior Bite Blocks

Magnetic bite block appliance: The use of a magnetic appliance in the treatment of skeletal open bite malocclusion was first illustrated in the literature in 1986 by Dellinger.²³ His 'Active Vertical Corrector' (Figure 6) consists of two removable bite block appliances (maxillary and mandibular) containing four samarium cobalt magnets per arch (two on either side) which the author describes as an 'energized bite block'. The magnets produce a reciprocal repelling, intrusive force of 600–650g per side when placed in the oral cavity.

Masticatory muscle exercises: Muscle exercises generally consist of either lip seal training or some sort of chewing/clenching exercise. A minimum of 45 to 150 minutes per day for 12 to 30 months of exercise appears to be necessary to produce clinically significant morphological changes in the dentofacial complex (Parks, 2007).

Transpalatal arch: The vertical development of the maxillary molars can be prevented by harnessing the forces generated by

the muscles of the tongue on the palatal arch during swallowing. DeBerardiniset al.²⁵ retrospectively analyzed the vertical holding appliance, which is a transpalatal arch with an acrylic pad (Figure 7). On Comparing with control subjects, treatment patients with the appliance had eruption of the maxillary molars controlled by 0.41mm.

Correction of open bite by incisor extrusion:

Vertical elastics (Nanda, 2012)

Indication

- Complaint patients
- Patients with divergence of occlusal planes anteriorly.

Biomechanics: Vertical elastics from the lower incisors to the upper incisors results in a consistent force system of equal and opposite forces (Figure 8). Reduction of open bite occurs by extrusion of incisors. Poor control of the force magnitude and degrees in compliance are main inherent problems.

Extrusion arches

Indication

- Noncompliant patients who will not wear anterior vertical elastics
- When upper and lower occlusal planes that diverge anterior to the first premolars.
- When a constant extrusive force is desired in the anterior teeth with minimal posterior side effects

Biomechanics: (Figure 9)

Multiloop edgewise archwire (meaw): Kim, (1987) developed MEAW consists of a 0.016"x0.022" stainless wire which contains a series of loops with both a horizontal and vertical component. (Figure10)

Treatment in nongrowing patients

Extraction for open bite closure: Different types of extractions have been suggested to correct anterior open bite, including extracting the second molars, extracting the first molars, extracting the second premolars, and extracting the first premolars (Nanda, 2012).

- **Second molar extractions:** The extraction of second molars has been suggested as a practical option in patients who have an anterior open bite with contact solely on these teeth and divergent occlusal planes (wedge effect).
- **First molar extraction:** Typically the first molar extracted only if they are compromised by extensive decay. If the second molar have not erupted and if the only contact is between the first molar, extraction of first molar would eliminate the increased vertical height
- **Premolar extractions:** Extraction of second or first premolars are the most commonly considered alternatives for the treatment of anterior open bites associated with crowding and or overjet. In patients who has premolars extracted, extrusion of anterior segment rather than wedge effect aids in closing the open bite.

Temporary anchorage devices (tad): TAD provides a source anchorage for intrusion of molars to correct the vertical dimension without the need for compliance of patient. A major advantage of molar intrusion with TADs is the favourable skeletal changes that enhance a patient's dentofacialesthetics. The suggested magnitude of force for molar intrusion is about 50 to 200 g per tooth. For en mass intrusion of premolars and molars, a force of approximately 200 to 400 g has been suggested. Usual time for intrusion of maxillary molars is 5-7 months for a mean intrusion of 2mm to 4mm. Sugawara et al. reported mean intrusion of 1.7mm and 2.8mm for mandibular first and second molars, respectively, when mini- plates were used.²⁸ Molar intrusion can be accomplished with different types of TADs. The line of force for molar intrusion determines the number of mini-implants, buccal or palatal placement, direct anchorage or indirect anchorage, and anatomic location of TAD placement.

Orthognathic surgery: Non-growing severe skeletal open bites patients are often treated by combined orthodontic and surgical approach. Patients having maxillary excess, superior repositioning of the maxilla, via total or segmental maxillary osteotomies is indicated. Maxillary impaction allows forward and upward rotation of the mandible, therefore decreasing the lower face height and eliminating anterior open bite. Superior repositioning of the maxilla is one of the most stable orthognathic surgical procedures. In one study, three degree of forward autorotation of the mandible was achieved when the maxilla was impacted 1.3mm posteriorly and 3 mm anteriorly (Mojdehi *et al.*, 2001). In addition to Le Fort I osteotomy, mandibular surgery may be performed to correct any associated mandibular deformity. The timing of surgical intervention is critical in a young adolescent. In a consensus conference (Freihofer *et al.*, 1994) on the timing of facial osteotomies, the participants recommended that most of the surgical procedure be done after completion of growth. Early surgical intervention can be an exception to the rule for psychosocial reasons (Freihofer *et al.*, 1994), especially for patients with vertical dimension, but the patients and their parents must be informed that additional surgery may be necessary later.

Stability and retention: Elimination of habits, weak musculature, and respiratory obstruction might decrease the rate and severity of relapse. In a study by Janson et al. (2006) the long term stability of corrected open-bite was greater in patient treated with extraction than in patient who did not have extraction. Analysis of long term studies indicate that orthognathic surgery is an effective method for the management of anterior open-bite. Superior re-positioning of maxilla by one piece Le fort 1 osteotomy is considered one of the most stable procedure in hierarchy of stability. According to a meta-analysis (Greenlee, 2011), correction of open-bite by a surgery is prone to some amount of relapse, although the long term stability was greater than 75%, possible reason for post-operative relapse are pre-operative orthodontic treatment, type of surgery, type of surgical fixation, condylar positioning during bimaxillary surgery, growth after surgery, and finally the soft tissue adaptation. Positioners are routinely suggested during retention phase. The elasticity of positioners between the molars applies an intrusive force through daily chewing exercise. Myofunctional therapy and placement of a tongue crib may improve stability in patients, especially with an anterior tongue posture. According to Nanda, masticatory muscle exercise involving a chewing gum or soft bite wafer

during retention might add in retaining the obtained result (Nanda, 2012).

Summary

The etiology of anterior open bite malocclusions is multifactorial. It is important to distinguish between a dentoalveolar and skeletal open bite. Treatments to correct this malocclusion rely mainly on the vertical control and/or extrusion of the anterior segments in the growing patient. With the introduction of TAD, skeletofacial changes can also be obtained with molar intrusion in non-growing patients. In patients with severe long face morphology, if esthetic is the main concern of treatment, then surgical alternatives should be taken into consideration.

Although all these treatments provide the possibility of attaining satisfactory outcomes, long term stability remains the major challenge for the orthodontist.

REFERENCES

- Bjork, A. 1969. A prediction of mandibular growth rotation, *Amer. J. Orthodont.*, 55: 585.
- Cangialosi TJ. 1984. Skeletal morphologic features of anterior open bite. *American journal of orthodontics*. Jan 1;85(1):28-36.
- Cozza P., Mucedero M., Baccetti T., Franchi L. 2005. Early orthodontic treatment of skeletal open bite malocclusion: a systematic review. *Angle Orthod*. Sept;75(5):707-13.
- DeBerardinis M, Stretesky T, Sinha P, Nanda RS. 2000. Evaluation of the vertical holding appliance in treatment of high-angle patients. *American Journal of Orthodontics and Dentofacial Orthopedics*. Jun 1;117(6):700-5
- Dellinger EL. 1986. A clinical assessment of the active vertical corrector—a nonsurgical alternative for skeletal open bite treatment. *American Journal of Orthodontics*. May 1;89(5):428-36.
- Erbay E., Ugur T., Ülgen M. 1995. The effects of Frankel's function regulator (FR-4) therapy on the treatment of Angle Class I skeletal anterior open bite malocclusion. *American journal of orthodontics and dentofacialorthopedics*. Jul 1;108(1):9-21.
- Frankel R. Lip seal training in the treatment of skeletal open bite *Eur J Orthod* 1980;2(4):219-28.
- Freihofer HP, Björk G, Jönsson E, Kuijpers-Jagtman AM. 1994. Timing of facial osteotomies: A consensus conference. *Oral surgery, oral medicine, oral pathology*. Oct 1;78(4):432-6.
- Graber TM. 1959. Thumb-and finger-sucking. *American Journal of Orthodontics*. Apr 1;45(4):258-64.
- Greenlee GM, Huang GJ, Chen SS, H, Chen J, Koepsell T, Hujoel P. 2011. Stability of treatment for anterior open bite malocclusion: A meta-analysis. *Am J Orthod Dentofacial Orthop.*, 139(2):154-69.
- Janson G, Valarelli FP, Beltrão RT, de Freitas MR, Henriques JF. 2006. Stability of anterior open-bite extraction and nonextraction treatment in the permanent dentition. *American journal of orthodontics and dentofacialorthopedics*. Jun 1;129(6):768-74.
- Kim YH. 1987. Anterior openbite and its treatment with multiloop edgewise archwire. *The angle orthodontist*. Oct;57(4):290-321.
- Lentini-Oliveira D., Carvalho FR., Qingsong Y., Junjie L., Saconato H., Machado MA., Prado LB, Prado GF. 2007. Orthodontic and orthopaedic treatment for anterior open bite in children. *Cochrane Database Syst Rev.*, Apr 18;2:CD005515.
- Linder-Aronson S., Woodside DG., Lundströ A. 1986. Mandibular growth direction following adenoidectomy. *American Journal of Orthodontics*. Apr 1;89(4):273-84.
- Loukota, R. A. and McCann, P. J. 2003. Condylar Neck Fractures. *Maxillofacial Trauma and Esthetic Facial Reconstruction*. 1st ed. Philadelphia: Elsevierscience, 281 - 297.
- Mojdehi M, Buschang PH, English JD, Wolford LM. 2001. Postsurgical growth changes in the mandible of adolescents with vertical maxillary excess growth pattern. *American Journal of Orthodontics and Dentofacial Orthopedics*. Feb 1;119(2):106-16.
- Nanda R. 2005. Biomechanics and esthetic strategies in clinical orthodontics. *Elsevier Health Sciences*; Apr 12.
- Nanda R. 2012. Esthetics and Biomechanics in Orthodontics-E-Book. Elsevier Health Sciences; May 7.
- Ngan, P. and Fields, H. W. 1997. Open bite: a review of etiology and management. *Pediatr. Dent.*, 19: 91 - 98.
- Parks LR, Buschang PH, Alexander RA, Dechow P, Rossouw PE. 2007. Masticatory exercise as an adjunctive treatment for hyperdivergent patients. *The Angle Orthodontist*. May;77(3):457-62
- Proffit WR., Fields HW., Sarver DM. 2000. The etiology of orthodontic problems. *Contemporary Orthodontic*. 3ed. St. Louis: Mosby.13-44.
- Proffit, W. R. Equilibrium theory revisited: factors influencing position of the teeth. *Angle Orthod*1978;48: 175 - 186.
- Reichert I, Figel P, Winchester L. 2014. Orthodontic treatment of anterior open bite: a review article—is surgery always necessary?. *Oral and maxillofacial surgery*. Sep 1;18(3):271-7.
- Sassouni V. 1969. A classification of skeletal facial types. *Amer J Orthod.*, 55:109-23.
- Stuani MB, Stuani AS, Stuani AS. 2005. Modified Thurow appliance: a clinical alternative for correcting skeletal open bite. *American journal of orthodontics and dentofacialorthopedics*. Jul 1;128(1):118-25.
- Subtelny JD., Sakuda M. 1964. Open-bite: diagnosis and treatment. *Am J Orthod.*, 50:337-58.
- Sugawara J, Baik UB, Umemori M, Takahashi I, Nagasaka H, Kawamura H, et al., 2002. Treatment and posttreatment dentoalveolar changes following intrusion of mandibular molars with application of a skeletal anchorage system (SAS) for open bite correction. *Int J Adult Orthod Orthognath Surg.*,17:243-53.
- Villa NL., Cisneros GJ. 1997. Changes in the dentition secondary to palatal crib therapy in digit-suckers: a preliminary study. *Pediatric dentistry*.19(5):323-6.
- Wang J, Goodger NM, Pogrel MA. 2003. The role of tongue reduction. *Oral Surgery, Oral Medicine, Oral Pathology, Oral Radiology, and Endodontology*. Mar 1;95(3):269-73.
- Wanjau J., Sethusa MP. 2010. Etiology and pathogenesis of anterior open bite: a review. *East African medical journal.*, 87(11).
- Wolford LM, Cottrell DA. 1996. Diagnosis of macroglossia and indications for reduction glossectomy. *American journal of orthodontics and dentofacialorthopedics*. Aug 31;110(2):170-7.
- Worms FW., Meskin LH., Isaacson RJ. 1971. Open-bite. *American journal of orthodontics*. Jun 1;59(6):589-95.