



ISSN: 0975-833X

Available online at <http://www.journalcra.com>

International Journal of Current Research
Vol. 12, Issue, 03, pp.10876-10878, March, 2020

DOI: <https://doi.org/10.24941/ijcr.38316.03.2020>

INTERNATIONAL JOURNAL
OF CURRENT RESEARCH

RESEARCH ARTICLE

A RARE CASE OF ANTERIOR ABDOMINAL WALL SARCOMA

^{1,*}Dr. Mohit Biswas, ²Dr. Arjun Agarwal, ³Dr. Sharad Seth, ⁴Dr. Cheena Garg and
⁵Shubham Biswas

¹Post graduate student, Department of General Surgery, Rohilkhand medical college and hospital, Bareilly, U.P

²Assistant Professor, Department of Surgical Oncology, Rohilkhand medical college and hospital, Bareilly, U.P

³Professor and Head, Department of General Surgery, Rohilkhand medical college and hospital, Bareilly, U.P

⁴Assistant Professor, Department of Pathology, Rohilkhand medical college and hospital, Bareilly, U.P

⁵UG student (MBBS), Gulbarga institute of medical sciences, Kalaburagi, Karnataka

ARTICLE INFO

Article History:

Received 24th December, 2019

Received in revised form

10th January, 2020

Accepted 28th February, 2020

Published online 30th March, 2020

Key Words:

Abdominal Wall Sarcoma,
Soft tissue Sarcoma,
Undifferentiated tumor.

ABSTRACT

Background: Soft-tissue sarcomas are a varied group of rare mesenchymal malignancies that can arise at any location in the body and affect all age groups. oft-tissue sarcomas arising from the abdominal wall mostly appear as palpable mass, abdominal wall deformity, or pain that is more clinically apparent. **Case report:** This case corresponds to a 44 years old female patient with ulcer over anterior abdominal wall extending up to the perineum since 1 year which gradually increased in size since 6 months. CT scan of the pelvis showed a large ulcerated soft density mass lesion in the abdomino-pelvic-perineal and inguinal region on right side measuring 23cm x 17cm x 15cm in size. The microscopic features from the biopsy showed epitheloid tumor cells with high N: C ratio, myxoid changes and final impression of Undifferentiated tumor. Outcome: The patient was initially kept on conservative treatment for pain and was advised for IHC markers to plan for further management but the patient refused for the same and did not follow up lately after discharge. **Discussion:** Abdomen and pelvis soft tissue sarcomas constitute 25-30% of all soft tissue sarcomas, with equal incidence in men and women. Although surgery remains the principal therapy for soft-tissue sarcomas, some tumors are not amenable to surgical resection because of the location and extent of the tumor or the presence of distant metastatic disease, or due to comorbid condition. Prognosis depends on location, on malignancy grade, histological subtype, size and quality of the operative resection.

Copyright © 2020, Mohit Biswas et al. This is an open access article distributed under the Creative Commons Attribution License, which permits unrestricted use, distribution, and reproduction in any medium, provided the original work is properly cited.

Citation: Dr. Mohit Biswas, Dr. Arjun Agarwal, Dr. Sharad Seth, Dr. Cheena Garg and Shubham Biswas. 2020. "A rare case of anterior abdominal wall sarcoma", International Journal of Current Research, 12, (03), 10876-10878.

INTRODUCTION

Soft-tissue sarcomas are a varied group of rare mesenchymal malignancies that can arise at any location in the body and affect all age groups. They are most common in the extremities, trunk wall, retro peritoneum, and head and neck. In the adults, soft-tissue sarcomas arising in the abdomen and pelvis are large masses at the time of diagnosis because they are usually clinically silent or cause mild symptoms until they invade or compress vital organs. In contrast, soft-tissue sarcomas arising from the abdominal wall come to attention earlier in the course of disease because they appear as palpable mass, abdominal wall deformity, or pain that is more clinically apparent.

*Corresponding author: Dr. Mohit Biswas,

Post graduate student, Department of General Surgery, Rohilkhand medical college and hospital, Bareilly, U.P.

The World Health Organization (WHO) divides sarcomas into two broad categories: sarcomas of soft tissue and sarcomas of bone (Fletcher, 2013). They account for less than 1% of malignant tumors. Liposarcoma, leiomyosarcoma, and gastrointestinal stromal tumor (GIST) are the most common intra-abdominal primary sarcomas. Any soft-tissue sarcoma can arise in the abdominal wall. The typical scenario is the discovery of a large abdominal or pelvic mass in a patient who is imaged for abdominal fullness or pain. The differential diagnosis will depend primarily on the anatomic location. Soft-tissue sarcomas arising in the abdomen and pelvis may occur in all anatomic compartments, the retroperitoneum, peritoneal cavity, and abdominal wall. However, knowledge of the imaging and pathologic features of soft-tissue sarcomas is important in the differential diagnosis. Because soft-tissue sarcomas are rare and can be difficult to treat and manage, an accurate initial diagnosis is essential for these patients. The classification and pathologic features of soft tissue sarcomas, the anatomic locations where they occur, and their cross-

sectional imaging features helps the radiologist establish the diagnosis or differential diagnosis so that patients with soft-tissue sarcomas can receive optimal treatment and management.

CASE REPORT

A 44 years old female patient presented to surgery OPD with ulcer over anterior abdominal wall extending up to the perineum since 1 year which gradually increased in size since 6 months. The patient had no history of previous abdominal surgery or any abdominal trauma. On examination, there was a large ulcer proliferative lesion extending from lower abdominal wall up to the perineum (Fig.1).

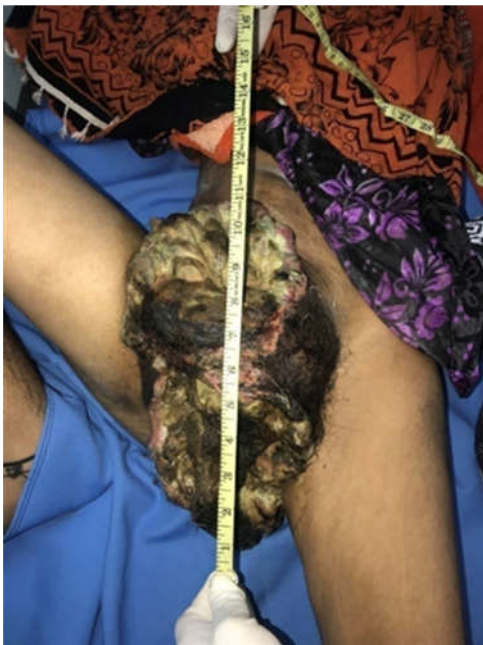


Figure 1. A large ulceroproliferative lesion extending from lower abdominal wall up to the perineum

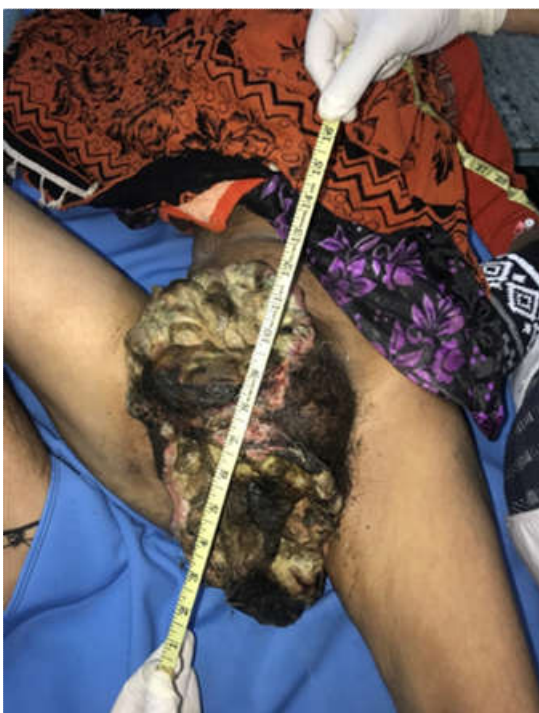

Figure 2. Irregular mass lesion with size of 13cm x 17cm x 15cm with hard surface and irregular borders

The mass lesion was irregular in shape with size of 13cm x 17cm x 15cm with hard surface and irregular borders (Fig.2). CT scan of the pelvis showed a large ulcerated soft density mass lesion noted in the abdomino-pelvic-perineal and inguinal region on right side measuring 23cm x 17cm x 15cm in size. The lesion involved right side lower anterior abdominal wall and shows intra abdominal extension in the pelvic region and perineal extension inferiorly. In the perineal region it involved vulva. The lesion crossed the midline and projects into the subcutaneous soft tissue on the left side. The lesion abutted the right sided Iliopsoas and Adductor muscles. The lesion also abutted the right sided femoral neurovascular bundle. The Uterus, Urinary bladder, upper 2/3rd of Vagina, Rectum and Anal canal can be visualized separately from the lesion. There was no sinister bony lesion and no abnormally enlarged pelvic lymph nodes noted. Biopsy from the lesion was taken of a soft irregular tissue piece of 1.6cm x 1cm x 1cm, outer surface of which was grey brown with areas of hemorrhage and the cut section was myxoid. The microscopic features showed sheets of epithelioid tumor cells having high N:C ratio, irregular nuclear membrane. Vesicular chromatin, prominent nucleoli and moderate amount of cytoplasm 10-12 mitotic figures seen per 10 high power fields. The tumor cells are separated by fibrous septa, myxoid change seen. Areas of necrosis and hemorrhage seen with inflammatory cell infiltrate. Blood vessels present in between tumor cells show infiltration of inflammatory cells. Thus the impression of the biopsy came out to be Undifferentiated tumor. The patient was advised for IHC markers but she refused.

DISCUSSION

Sarcomas are a heterogeneous group of rare and malignant neoplastic conditions with greater prevalence in adult male individuals (Williams, 2014). The WHO classification is the accepted standardization of nomenclature and classification for soft-tissue sarcomas (Anaya, 2008). The names of the sarcomas are derived from the cell type they resemble histologically and immunohistochemically. The purpose of classification is to create a framework for treatment and management of patients with soft-tissue sarcomas that is based on tumor biology. However, the biologic behavior of the majority of soft-tissue sarcomas cannot be predicted by tissue type alone. Tumor grading and staging strongly correlate with prognosis. Tumor grade is an estimate of the degree of malignancy. The grading system set forth by the French Federation of Cancer Centers is the most widely used (Lahat, 2008). Histologic tumor grade is determined by a scoring system that assesses tumor differentiation, mitotic count, and tumor necrosis. Soft tissue sarcomas correspond to 1% of malignant tumors in adults (Wilmar, 2008), and occurrence on the abdominal wall is considered rare as they correspond to 0.1% of malignant tumors (Fletcher, 2013). This group of neoplasms has its origin in mesenchymal cells of various sites: adipocytes, muscles, blood vessels, cartilage, nerves and bones (Fletcher, 2013). The destruction and recurrence of the tumor depends on the histological type, degree of mitoses, and immunohistochemical analysis is important to define the source of the tumor and prognostic for the patients (Anaya, 2008). They have a high incidence of local recurrence (25%) and have a propensity for distant metastases, accounting for a substantial mortality rate of 50% (Brennan, 1999). Less than 5% of sarcomas appear as primary abdominal wall tumors. Soft tissue sarcomas of the abdomen and pelvis include a broad spectrum of histological subtypes with both low and high-

grade tumors. Sarcomas in the abdomen are often grouped according to location: Retroperitoneal, Intra-abdominal, Gynecological, Abdominal wall. In 2015, two persons were diagnosed with soft tissue sarcomas in the abdomen and pelvis, both were men. Abdomen and pelvis soft tissue sarcomas constitute 25-30% of all soft tissue sarcomas. Retroperitoneal sarcomas amount to about 15% of all soft tissue sarcomas, while intra-abdominal sarcomas account for 10-15%. They occur in all age groups and involve men and women equally. Gynecological sarcomas may occur in women of all ages and comprise about 5% of all uterine cancer. Among these, leiomyosarcoma amounts to about 60%, while endometrial stromal sarcoma and adenosarcoma, comprise 20% and 6%, respectively. Soft tissue tumors of the abdominal wall, though clinically similar, have many distinct histologic subtypes. For optimal treatment planning and outcome, consideration of the type of primary tumor is crucial. Some tumor variants are known for their aggressive biologic behavior. Included among these are soft tissue sarcomas (STS), desmoid tumors, and dermatofibrosarcoma protuberans (DFSP). There are many different histological types of soft tissue sarcoma. The most common are: Liposarcoma, Gastrointestinal stromal tumor (GIST), Leiomyosarcoma. In most cases, the cause is unknown. Several risk factors have been identified that increase the likelihood of developing a soft tissue sarcoma. Risk factors, external radiation therapy are the most well-established risk factor. Patients treated with radiation therapy for cancers of the breast, cervix, ovary, testes, retina, or lymphatic system have a much higher chance of developing a soft tissue sarcoma than the general population. Another risk factor for soft tissue sarcomas is exposure to certain chemicals in the workplace, including: vinyl chloride, arsenic, herbicides such as phenoxyacetic acids, wood preservatives that contain chlorophenols, A genetic disposition for the development of soft tissue sarcoma has been shown for several inherited diseases:

Li-Fraumeni syndrome (associated with alterations in the p53 tumor suppressor gene), von Recklinghausen disease (also called neurofibromatosis type 1 and associated with alterations in the NF1 gene), hereditary leiomyomatosis and renal cell cancer syndrome (with alterations in the FH gene), hereditary retinoblastoma (with alterations in the RB1 gene), Patients with these disorders are all at risk of developing soft tissue sarcomas. Patients with soft-tissue sarcomas should be managed by a multidisciplinary team of surgeons, radiologists, pathologists, radiation oncologists, and medical oncologists with expertise and experience in soft-tissue sarcomas. Although surgery remains the principal therapy for soft-tissue sarcomas, some tumors are not amenable to surgical resection because of the location and extent of the tumor or the presence of distant metastatic disease, or because the patient is not a surgical candidate due to comorbid conditions. The optimal resection is an R0 resection that leaves no residual microscopic disease. The resection is deemed R1 when there is residual microscopic disease and R2 when there is residual gross disease (Aufforth, 2015). Surgical resection with negative margins remains the standard treatment for patients with localized abdominal sarcomas, including retroperitoneal, intra-abdominal, abdominal wall and gynecological sarcomas.

The goal and requisite for cure is complete surgical resection with microscopic tumor-free margins in the first attempt. All radiological images must be assessed carefully to plan the extent of the surgery. As complete resection is the goal, adequate margins around the tumor must be defined. When necessary, surrounding organs must be assessed for en bloc resection. The size of the tumor, pattern of growth, and location close to vital organs and structures at the time of diagnosis often renders the surgical resection a complicated procedure. Radiation Therapy At the discretion of the Multidisciplinary Soft Tissue Sarcoma group or as part of clinical trials, patients were treated with adjuvant radiation therapy based on prognostic factors predicting an increased risk of local recurrence. Chemotherapy is administered to a limited degree for abdominal sarcomas, but the benefit has not been clearly documented yet. Intra-operative radiation therapy (IORT) may lead to delayed relapse of the disease, but a prolongation of survival has not been shown. Varying degrees of side effects are seen after surgery, chemotherapy, and radiation therapy. Supportive care may also be provided to reduce side effects and improve the patient's quality of life during and after treatment. Prognosis depends on location, malignancy grade, histological subtype, size and quality of the operative resection.

Conclusion

Abdominal wall sarcoma is a rare presentation of soft issue tumors and needs aggressive resection to prevent local recurrence. Reconstruction of abdominal wall requires adequate surgical approach and a long follow up of patients in order to identify local recurrence or metastasis.

REFERENCES

- Anaya DA., Lev DC., Pollock RE. 2008. The Role of Surgical Margin Status in Retroperitoneal Sarcoma. *J Surg Oncol.*, 98:607-610.
- Aufforth RD., Baker JJ., Kim, HJ. 2015. Soft tissue sarcoma. In: Chu QD, Gibbs JF., Zibari GB, editors., eds. surgical oncology: a practical and comprehensive approach. New York, NY: Springer, 605–626
- Brennan MF. 1999. Staging of soft tissue sarcomas. *Ann Surg Oncol.*, 68- 9.
- Fletcher CDM, Bridge JH, Hogendoorn PCW, Mertens F. 2013. editors. , eds. WHO classification of tumours of soft tissue and bone. 4th ed. Lyon, France: IARC, 10–11
- Lahat G., Anaya DA., Wang X. *et al.*, 2008. Resectable Well-Differentiated versus Dedifferentiated Liposarcomas: Two Different Diseases Possibly Requiring Different Treatment Approaches. *Ann Surg Oncol.*, 15 (6): 1585-1593.
- Williams KJ., Hayes AJ. 2014. A guide to oncological management of soft tissue tumours of the abdominal wall. *Hernia* 18: 91-97.
- Wilmar JS., Manoel, Silveira Júnior BJQ., Abreu LP., Abreu Neto DCB. *et al.*, 2008. Sarcomas de alto grau: estudo retrospectivo de 131 casos. *Rev Col Bras Cir.*, 35: 83-87.