



## SUBCUTANEOUS EMPHYSEMA AND PNEUMOMEDIASTINUM IN A POSTTRAUMATIC PATIENT: A CASE REPORT

Muhammad Sule Baba<sup>1,\*</sup>, Ma'aji Sadiyu Mohammed<sup>1</sup>, Sa'idu Sule Ahmed<sup>1</sup>, Shamaki Amina Muhammad Bello<sup>1</sup> and Usman Aminu Umar<sup>2</sup>

<sup>1</sup>Department of Radiology, Usmanu Danfodiyo University, Sokoto, Nigeria

<sup>2</sup>Department of Radiology, Gombe state University, Gombe, Nigeria

### ARTICLE INFO

#### Article History:

Received 20<sup>th</sup> September, 2020

Received in revised form

27<sup>th</sup> October, 2020

Accepted 15<sup>th</sup> November, 2020

Published online 30<sup>th</sup> December, 2020

#### Key Words:

Mediastinum,

Soft tissue, Trauma, Lungs.

### ABSTRACT

Subcutaneous emphysema is defined as the presence of free air in the subcutaneous tissues, and has numerous causes including blunt and penetrating trauma, soft tissue infection and surgical instrumentation. This is a forty-five year old house-wife referred for an emergency plain chest radiograph from a rural health care unit on account of chest trauma following a road traffic accident. The plain chest radiograph showed multiple rib fractures bilaterally, fractured right clavicle, lucencies within the mediastinum, lateral chest wall bilaterally, scapula region and neck regions bilaterally. Features of lung contusion more marked on the right upper zone were also demonstrated. We report the radiographic features of subcutaneous emphysema and pneumomediastinum which are often encountered following penetrating and blunt chest trauma most especially following road traffic accident in our environment.

Copyright © 2020. Muhammad Sule Baba et al. This is an open access article distributed under the Creative Commons Attribution License, which permits unrestricted use, distribution, and reproduction in any medium, provided the original work is properly cited.

Citation: Muhammad Sule Baba, Ma'aji Sadiyu Mohammed, Sa'idu Sule Ahmed, Shamaki Amina Muhammad Bello, Usman Aminu Umar. "Subcutaneous emphysema and pneumomediastinum in a posttraumatic patient: A case report", 2020. *International Journal of Current Research*, 12, (12), 15411-15413.

## INTRODUCTION

Subcutaneous emphysema happens when air gets access into the tissues under the skin and in the soft tissues usually in the chest wall or neck but can also occur in other parts of the body<sup>1,2</sup>. Subcutaneous emphysema (SE) is a clinical condition that usually is associated with mild symptoms but occasionally may be severe and life threatening<sup>1</sup>. Subcutaneous emphysema and pneumomediastinum (PM) are rather uncommon clinical entities that usually arise from gas leaking from the lungs or other luminal organs<sup>3</sup>. Subcutaneous emphysema have varying etiologies, among which are blunt or penetrating trauma, pneumothorax barotrauma, infection, malignancy, complication of surgical procedures and idiopathic (spontaneous)<sup>1,4</sup>.

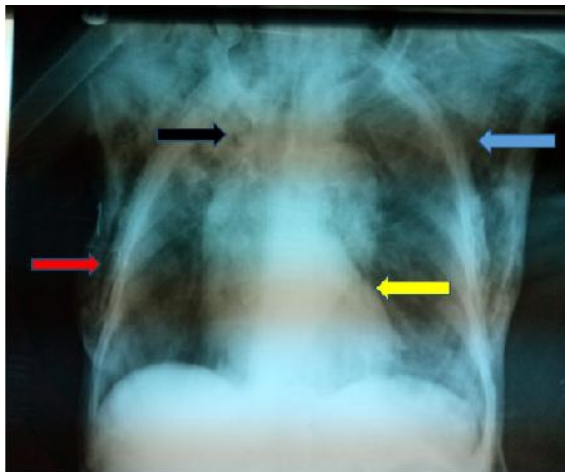\*Corresponding author: Muhammad Sule Baba,  
Department of Radiology, Usmanu Danfodiyo University, Sokoto,  
Nigeria.

Chest trauma is regarded as a major cause of SE, this can cause entrance of air in to the skin of the chest wall from the neck or lung<sup>1,5</sup>. Subcutaneous emphysema is often known to be associated with underlying pneumothorax and rarely airway injury<sup>6,7</sup>. Subcutaneous emphysema and PM are usually due to spontaneous alveolar wall rupture or occasionally of disruption of the upper airways or gastrointestinal tract and are related to the presence of air within the subcutaneous tissue or mediastinal cavity respectively<sup>3,8-10</sup>. Pneumomediastinum occurs when there is the presence of air in the mediastinum, it has also been described as mediastinal emphysema and could either be spontaneous or secondary pneumomediastinum<sup>11-14</sup>. In pneumomediastinum, about 70% of cases do have concurrent subcutaneous emphysema<sup>11, 15-16</sup>. Aghajanzadeh et al<sup>1</sup>, classified the severity of SE in to five grades which are: 1; Affecting the base of the neck, 2; the entire neck region, 3; the subpectoralis region, 4; chest wall and the entire neck region and 5; Chest wall, neck, orbit, scalp, abdominal wall, upper limbs and scrotum. Pneumomediastinum and SE are often diagnosed by plain chest radiography and occasionally non-contrast computed tomography which happens to be more sensitive especially with lower amount of accumulated gas<sup>3,17</sup>.

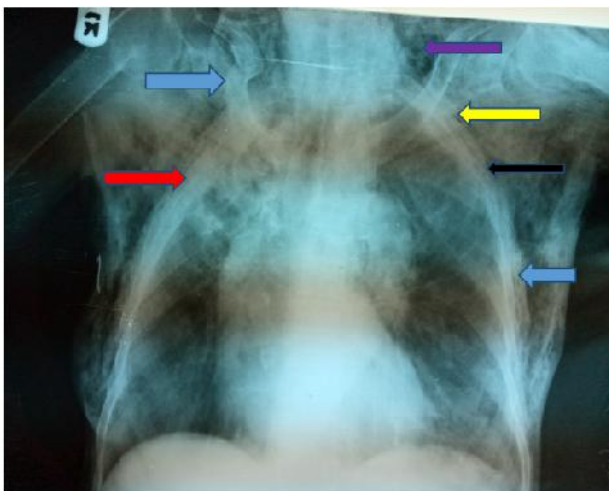
Management of SE often presents a dilemma, beginning with identification of the cause, various approaches have been done which include the use of subcutaneous incisions, needles, drains or cervical mediastinotomy<sup>1, 2, 18</sup>.

## CASE REPORT

A forty-five year old house-wife was referred for an emergency plain chest radiograph on account of sudden onset restlessness, chest pain and discomfort, rapid and difficult respiratory effort following a road traffic accident. A middle aged women in respiratory distress, not pale, conscious and alert but in painful distress, had swollen neck, lateral chest wall, anterior chest wall, and fullness of the right supraclavicular region with severe chest tenderness. The patient had a supine chest radiograph that showed multiple and bilateral rib fractures (Figure 2), fractured right clavicle (Figure 2), lucencies tracking along the heart and great vessels (Figure 1), lucencies in the lateral chest wall and in the scapular region (figure1) and neck regions bilaterally (Figure 2). There is associated lung contusion bilaterally more marked on the right upper zone (Figure 1).



**Figure 1** Plain supine chest radiograph showing lucencies in the soft tissues of lateral chest wall (right red arrow), scapular region (left blue arrow) and tracking along the margins of the heart (left yellow arrow). Right lung contusion also noted (right black arrow)



**Figure 2.** Plain supine chest radiograph showing fractured right clavicle (right blue arrow), fractured ribs bilaterally (right red arrow, left yellow, black and blue arrows) and track of lucencies along the neck (left purple arrow)

No penetrating injury was noted. A diagnosis of extensive subcutaneous emphysema and pneumomediastinum following a blunt chest trauma on account of road traffic accident was made. The patient and relatives were advised to request for a referral from the health care attendant at the referring health facility to a tertiary institution for a better management. The patient was reported (by a relative) to have passed away at the peripheral health facility before been referred for better management at a tertiary health institution.

## DISCUSSION

Subcutaneous emphysema (SE) is a clinical condition that usually is associated with mild symptoms but occasionally may be severe and life threatening<sup>1</sup>, the index case presented with severe symptoms conforming to this literature. Subcutaneous emphysema have varying etiologies, among which are blunt or penetrating trauma, pneumothorax barotrauma, infection, malignancy, complication of surgical procedures and idiopathic(spontaneous)<sup>1,4</sup>. The index case had blunt trauma following a road traffic accident (RTA) thereby conforming to these literatures. Aghajanzadeh et al<sup>1</sup>, classified the severity of SE in to five grades, the index case is most probably belongs to grade 4 which defines the presence of air in the chest wall and the entire neck region, thereby conforming to this literature. Pneumomediastinum occurs when there is the presence of air in the mediastinum, it has also been described as mediastinal emphysema and could either be spontaneous or secondary pneumomediastinum in its etiology.<sup>11-14</sup>

The index case also had presence of air in the mediastinum seen tracking along the heart and great vessels and it is classified as secondary pneumomediastinum following blunt chest trauma on account of RTA. Pneumomediastinum and SE are often diagnosed by plain chest radiography and occasionally non-contrast computed tomography which happens to be more sensitive especially with lower amount of accumulated gas<sup>3,17</sup>. The index case was diagnosed by plain radiograph conforming to these literatures. Computed tomography was however not done in this case. Management of SE often presents a dilemma, beginning with identification of the cause, various approaches have been done which include the use of subcutaneous incisions, needles, drains or cervical mediastinotomy<sup>1, 2, 18</sup>. The index case however had no any form of intervention because she died before such was instituted.

## Conclusion

Subcutaneous emphysema could be life threatening and often accompanied by pneumomediastinum with trauma as the common cause. Plain radiograph of the chest when done immediately can establish a diagnosis enabling prompt institution of management to save lives of these patients.

## REFERENCES

1. Aghajanzadeh M, Dehnadi A, Ebrahim H, Karkan MF, Jahromi SK, Maafi AA et al., 2015. Classification and Management of Subcutaneous Emphysema: A 10-Year Experience. *Indian J Surg.*, 77:S673-S677.

2. Rojas M, Rojas P, Toro C, Pinto D, Cifuentes C, Henriquez et al., 2009. Subcutaneous emphysema after ultrasonic treatment: a case report. *Int J Odontostomatol.* 3:67-70
3. Storz MA, Heymann EP, Exadaktylos AK. 2017. Diffuse Subcutaneous Emphysema and Pneumomediastinum Secondary to a Minor Blunt Chest Trauma. *Case Reports in Emergency Medicine. Hindawi.*, 2017:1-4.
4. Beck P, Heitman S, Mody C. 2002. Simple construction of a subcutaneous catheter for treatment of severe subcutaneous emphysema. *Chest.* 121:647-649.
5. DeGowin R, Brown D. 2004. DeGowin's diagnostic examination. McGraw-Hill Medical, New York. pp 388-552
6. Olmstead D, Gelfand G, Anderson I, Kortbeek JB. 2018. A case report of acute airway compromise due to subcutaneous emphysema. *Case Reports in Medicine.*, 2018:1-5.
7. Maunder RJ, Pierson DJ, Hudson LE. 1984. Subcutaneous and mediastinal emphysema: pathology, diagnosis and management. *Archives of Internal Medicine.* 144:1447-1453.
8. Banki F, Estrera AL, Harrison RG. 2013. Pneumomediastinum: etiology and a guide to diagnosis and treatment. *AM J Surg.*, 206:1001-1006.
9. Maunder RJ, Pierson DJ, Hudson LD. 1984. Subcutaneous and mediastinal emphysema: pathophysiology, diagnosis, and management. *Archives of Internal Medicine.* 144:1447-1453.
10. Gray JM, Hanson GC. 1966. Mediastinal emphysema: etiology, diagnosis and treatment. *Thorax.* 21:325-332.
11. Kouritas VK, Papagiannopoulos K, Lazaridis G, Baka S, Mpoukovinas I, Karavasilis V. et al. 2015. Pneumomediastinum. *J Thorac Dis.*, 7:S44-S49.
12. Kobashi Y, Okimoto N, Matsushima T. Comparative study of mediastinal emphysema as determined by etiology. *Intern Med.* 2002;41:277-282
13. Sahni S, Verma S, Grullon J. 2013. Spontaneous pneumomediastinum: time for consensus. *N Am J Med Sci.*, 5:460-464.
14. Macia I, Moya J, Ramos R. 2007. Spontaneous pneumomediastinum: 41 cases. *Eur J Cardiothorac Surg.*, 31:1110-1114.
15. Caceras M, Ali SZ, Braud R. 2008. Spontaneous pneumomediastinum: a comparative study and review of the literature. *Ann Thorac Surg.*, 86:962-966.
16. Perna V, Vila E, Guelbenzu JJ. 2010. Pneumomediastinum: is this really a benign entity?. When it can be considered spontaneous? Our experience in 47 adult patients. *Eur J Cardiothorac surg.*, 37:573-575.
17. Fosi S, Giuricin V, Girardi V. 2014. Subcutaneous emphysema, pneumomediastinum, pneumoretroperitoneum and pneumoscrotum: unusual complications of acute perforated diverticulitis. *Case Reports in Radiology.*, 1-5.
18. Herlan DB, Lanrenew R, Ferson P. 1992. Massive spontaneous subcutaneous emphysema. Acute management with infraclavicular blow holes. 102:503-505.

\*\*\*\*\*