



ISSN: 0975-833X

Available online at <http://www.journalera.com>

International Journal of Current Research
Vol. 12, Issue, 11, pp.14569-14570, November, 2020

DOI: <https://doi.org/10.24941/ijcr.40124.11.2020>

INTERNATIONAL JOURNAL
OF CURRENT RESEARCH

RESEARCH ARTICLE

TELANGIECTATIC OSTEOSARCOMA OF PARIETAL BONE: A RARE CASE REPORT AND REVIEW OF LITERATURE

¹Dr. Sunita Singh, ^{2,*}Dr. Neelam, ³Dr. Rajnish Kalra, ⁴Dr. Rachana and ⁵Dr. Anjali Ahlawat

^{1,3}MD, Senior Professor, Department of Pathology, PGIMS, Rohtak

²Senior Resident, Department of Pathology, PGIMS, Rohtak

^{4,5}MBBS, Junior Resident, Department of Pathology, PGIMS, Rohtak

ARTICLE INFO

Article History:

Received 10th August, 2020

Received in revised form

17th September, 2020

Accepted 30th October, 2020

Published online 30th November, 2020

ABSTRACT

Telangiectatic osteosarcoma (TO) is a rare variant of osteosarcoma. It most commonly involves the long bones and has specific diagnostic features. The primary TO of skull is extremely rare. We present a case of primary telangiectatic osteosarcoma of the parietal bone and its clinicopathological features, imaging and treatment outcome in a 63 year old male.

Key Words:

Sacroiliac Joint, Articular Space Width, CT scan, Morphometric Analysis, Anatomical Variation.

Copyright © 2020, Sunita Singh et al. This is an open access article distributed under the Creative Commons Attribution License, which permits unrestricted use, distribution, and reproduction in any medium, provided the original work is properly cited.

Citation: Dr. Sunita Singh, Dr. Neelam, Dr. Rajnish Kalra, Dr. Rachana and Dr. Anjali Ahlawat. 2020. "Telangiectatic Osteosarcoma of parietal bone: A rare case report and review of literature", *International Journal of Current Research*, 12, (11), 14569-14570.

INTRODUCTION

Telangiectatic osteosarcoma (TO) is a rare variant of osteosarcoma comprising 3-10 % of all osteosarcomas. It usually involves the long bones. TO of cranial bones is extremely rare accounting for 1.5% of telangiectatic osteosarcomas (Sangle, 2012). We report a case of TO of the parietal bone, its clinical features, radiological and pathological findings and treatment protocol.

CASE REPORT

A 63 year old male presented with complaints of swelling over the right parietal region for last 4 months. The swelling was not associated with pain. On local examination, the swelling was 5x5cm in size, non-mobile and stony hard. No focal neurological deficit was noticed. CECT head showed a large destructive soft tissue attenuating lesion on Right parietal bone with large epidural component indenting the underlying Right parietal cortex (Figure-1) PET scan revealed hypermetabolic heterogeneously contrast enhancing large lytic destructive lesion in the right parietal bone (Figure-2) The tumor was excised completely along with part of dura.

Grossly, the tumor was highly vascular, cystic and densely attached to the dura. Sections examined showed large telangiectatic spaces filled with blood. The septae between the spaces were filled with atypical cells showing high pleomorphism and atypical mitosis. Lacy osteoid formation was also noted directly from the tumour cells (Figure-3). The diagnosis of telangiectatic osteogenic sarcoma was rendered. The patient underwent chemotherapy. The patient was doing well after 5 months of surgery.

DISCUSSION

Osteosarcoma is the most common malignant bone tumor. It usually presents in childhood and adolescence and mostly involves metaphyseal region of long bones. Head and neck osteosarcoma accounts for 0.5 % to 8.5% of all osteosarcomas with location mostly in mandible and maxilla in about 80% of the cases. Extragnathic osteosarcoma is extremely uncommon.² TO is rare subtype comprising 3-10% of osteosarcomas. It has been reported most commonly in long bones and rarely in ribs, pelvis, scapula and cranial bones (Sangle et al., 2012; Patibandla et al., 2011). TO exhibits distinctive radiological, gross and histopathological features. The hallmark of TO is expansile lytic lesion without sclerosis. Most common differential to be ruled out is aneurysmal bone cyst as it has a similar radiological appearance.

*Corresponding author: Dr. Neelam,
Senior Resident, Department of Pathology, PGIMS, Rohtak.

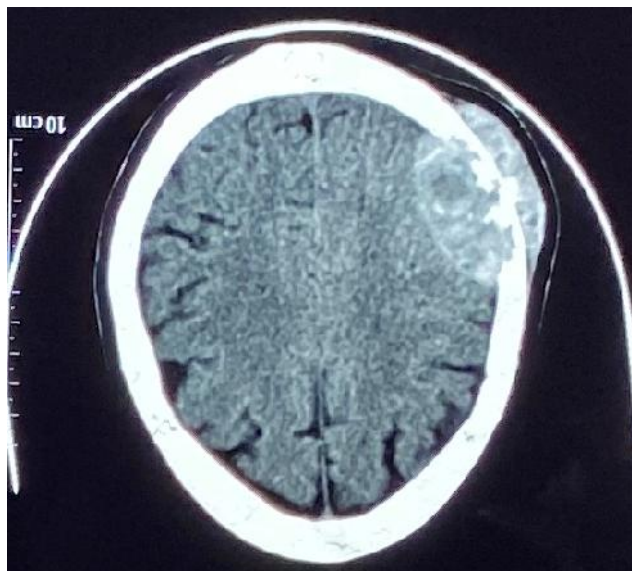


Figure 1. CECT image showing a large lytic lesion with minimal sclerosis over the parietal bone

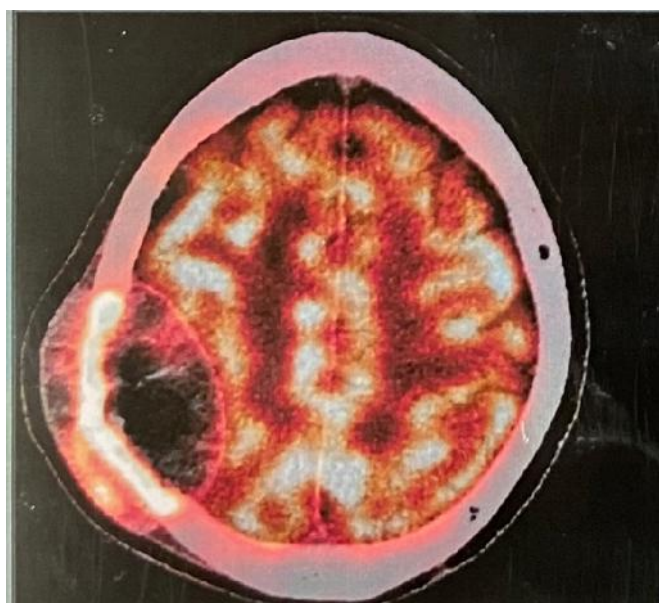


Figure 2. PET scan showing a hypermetabolic destructive lytic lesion over the parietal bone

The other differentials are giant cell tumour, angiosarcoma and metastasis. Hence, histopathological examination is a must for confirming the diagnosis. On CECT and MRI, TO should be considered when it shows a lytic lesion with fluid-fluid levels.¹ Matsuno et al proposed the following histopathological and radiological criteria for the diagnosis of TO – 1) Predominantly lytic bone mass with minimal sclerosis, 2) Grossly cystic mass with no or minimal solid or sclerotic component, 3) Histological features comprising of bone forming tumour with notable blood filled spaces separated by septae lined by, and /or containing malignant tumor cells with prominent nuclear atypia and limited osteoid deposition (Matsuno, 1976). The treatment modalities include complete surgical excision with attempts to get a clear margin. Chemotherapy and radiotherapy is required if the complete removal of the tumour is doubtful (Naik, 2014). Local recurrence is the most common cause of death whereas pulmonary metastasis is more common in osteosarcoma of the long bones (Whitehead, 1998).

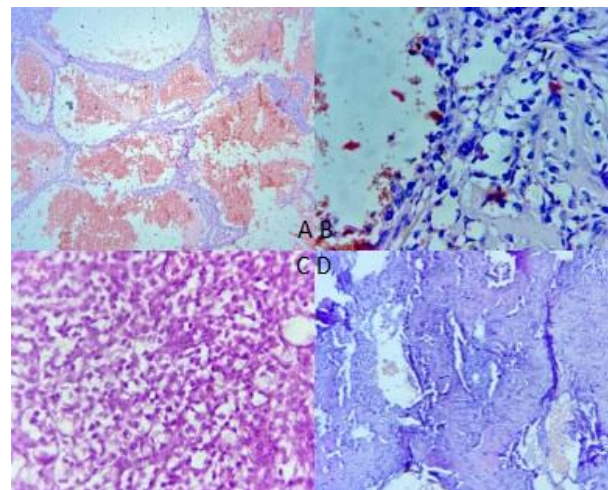


Figure 3 – A- Low power view of the tumour showing blood filled cystic spaces with cellular tumour cells in the septae surrounding these spaces B- The tumour cells are pleomorphic with hyperchromatic nuclei C – Cellular tumour with atypical mitosis D- Osteoid formation by the tumour cells in few areas identified

Hence, long term follow up is mandatory. The 5-year survival and overall survival is similar to those for patients with other OS subtypes. The absence of local disease progression and use of three or more chemotherapeutic agents active against osteosarcoma were correlated with improved outcome (Weiss, 2007). To conclude, TO of the skull bones is extremely rare and should be considered in the differentials of lytic lesion. Histological examination is must for definitive diagnosis. The treatment is aimed at complete excision of the tumour with free margins. Chemotherapy and radiotherapy may be considered if margins are doubtful or positive. Local recurrence is most commonly associated with poor survival hence long term follow up is mandatory.

Conflicts of Interest: None

Funding: None

Key Words

-) Telangiectatic osteosarcoma
-) Skull
-) Rare Variant,
-) Parietal Bone

REFERENCES

- Matsuno T, Unni KK, McLeod RA, Dahlin DC. 1976. Telangiectatic osteogenic sarcoma. *Cancer.*, 38(6):2538-47
- Naik LK, Shetty P, Teerthanath S, Jagadeesh HM. Telangiectatic osteosarcoma affecting the mandible. *J Oral Maxillofac Pathol.*2014Sep;18(Suppl 1):S143-6
- Patibandla MR, Uppin SG, Thotakura AK, Panigrahi MK, Challa S. 2011. Primary telangiectatic osteosarcoma of occipital bone: a case report and review of literature. *Neurol India.* - Feb;59(1):117-9
- Sangle NA, Layfield LJ. 2012. Telangiectatic osteosarcoma. *Arch Pathol Lab Med.* May;136(5):572-6
- Weiss A, Khoury JD, Hoffer FA, Wu J, Billups CA, Heck RK, et al. 2007. Telangiectatic osteosarcoma: the St.Jude Children Research Hospital's experience. *Cancer.* Apr15;109(8):1627-37
- Whitehead RE, Melhem ER, Kasznica J, Eustace S. 1998. Telangiectatic osteosarcoma of the skull base. *AJNR Am J Neuroradiol.*, 19(4):754-7