



ISSN: 0975-833X

Available online at <http://www.journalcra.com>

International Journal of Current Research
Vol. 12, Issue, 12, pp.15202-15209, December, 2020

DOI: <https://doi.org/10.24941/ijcr.40444.12.2020>

INTERNATIONAL JOURNAL
OF CURRENT RESEARCH

RESEARCH ARTICLE

A SHORT TERM OUTCOME OF LAPAROSCOPIC HAND SEWN ROUX-EN-Y GASTROJEJUNOSTOMY IN GASTRIC OUTLET OBSTRUCTION FROM A DEVELOPING COUNTRY- AN OBSERVATIONAL STUDY

¹Dr. Mushtaq Chalkoo, ²Dr. Aabid Rasool Bhat, ³Dr. Imtiyaz ahmad Ganie, ⁴Dr. Tajamul samad and ⁵Dr. Mohammed Anyees Khanday

¹Professor Laparo-endoscopic surgeon Government Medical College Srinagar

^{2,3,5}PG Scholar Government Medical College Srinagar

⁴Post Graduate Scholar, Government Medical College, Srinagar

ARTICLE INFO

Article History:

Received 01st August, 2020
Received in revised form
03rd October, 2020
Accepted 04th November, 2020
Published online 30th December, 2020

Key Words:

Laparoscopy,
Stomach,
Tumors, Obstruction

ABSTRACT

Back Ground: Carcinoma stomach is one of the commonest malignancies seen in our Kashmiri population, due to excessive consumption of salt and pepper. It is considered as captain of the men of death. Over the period of time, different surgical modalities and their modifications have been devised by different surgeons, all across the globe. Thanks to Kitano who performed first laparoscopic Gastrectomy in 1994 and changed the scenario in the surgical management of carcinoma stomach. One of the presentations of gastric tumors is Gastric outlet obstruction which presents with biochemical and anatomicosurgical syndrome in these patients. We became interested to study the surgical outcome of laparoscopic hand sewn Roux En Y Gastrojejunostomy anastomosis in gastric outlet obstruction. The aims of the study were to assess the feasibility of the procedure and evaluate patients for Afferent Loop Syndrome post operatively. The other aims studied being time taken for anastomosis, total hospital stay, return of bowel sounds and post-operative complications. The conclusion of the study was Laparoscopic Roux En Y Gastrojejunostomy is effective in achieving quality of life and the chances of afferent loop syndrome are least with it.

Copyright © 2020, Mushtaq Chalkoo et al. This is an open access article distributed under the Creative Commons Attribution License, which permits unrestricted use, distribution, and reproduction in any medium, provided the original work is properly cited.

Citation: Dr. Mushtaq Chalkoo, Dr. Aabid Rasool Bhat, Dr. Imtiyaz ahmad Ganie, Dr. Tajamul samad and Dr. Mohammed Anyees Khanday. 2020. "A short term outcome of laparoscopic hand sewn roux-en-y gastrojejunostomy in gastric outlet obstruction from a developing country- an observational study", *International Journal of Current Research*, 12, (12), 15202-15209.

INTRODUCTION

Gastric Outlet Obstruction is a term used to describe a condition where there is an inability of gastric contents to go beyond the proximal duodenum. Gastric outlet obstruction (GOO) is a misnomer expression as numerous cases include duodenal or extra luminal disease too. The obstruction may be partial or complete^{1,2,3}. Apart from the mechanical impediment of the flow of gastric contents; there are other concerns in patients with GOO, such as malnutrition and electrolyte imbalance⁴. The major cause of GOO was peptic ulcer disease before the advent of proton pump inhibitors and H2 blockers. The discovery of *Helicobacter pylori* and developing an effective treatment for the same has resulted in fewer cases of (PUD) presenting with GOO (<5%); however in the modern era, the major cause is known to be distal gastric malignancy, especially in the developed world⁵.

The prevalence of *H. Pylori* has been reported to be high with about 80% of the population being affected⁶ and the prevalence of peptic ulcer and gastric carcinoma are 8/lakh and 3/ lakh respectively^{7,8}. The Causes of gastric outlet obstruction can be Gastric or Extra Gastric in origin. Among the various gastric causes, Chronic peptic Ulcer, Gastric Adenocarcinoma, Gastrointestinal Tumors, Gastric Lymphoma, Tuberculosis, and Amyloidosis complete the list. Periapillary carcinoma, hepatobiliary carcinoma, pancreatic carcinoma, colon carcinoma and Neuroendocrine carcinoma are extra gastric in origin, causing Gastric Outlet Obstruction. Malignant gastric outlet obstruction (GOO) is a presentation of advanced malignancies in the upper GIT most commonly pancreatic and gastric malignancies, lymphomas, ampullary carcinomas, biliary tract cancers and metastasis^{9,10,11}. Associated symptoms, including nausea, vomiting, reflux, malnutrition, dehydration and abdominal distention, reduce patient quality of life (QOL), and patients with Malignant GOO often present with a poor condition and performance status (PS)¹². Furthermore, palliative treatment is important and required for patients with unresectable primary malignancy or metastatic lesions.

*Corresponding author: Dr. Mushtaq Chalkoo,
Professor Laparo-endoscopic surgeon Government Medical College Srinagar.

Despite a decrease in the incidence of gastric cancer over previous decades, gastric cancer remains the fourth most common malignant disease and the second main cause of cancer – related death worldwide¹³. To date, the curative resection ratio for newly diagnosed gastric cancer is approximately 50% and 20% to 30% of patients with gastric cancer present with stage IV disease^{14,15}. Malignant GOO is a common condition among locally advanced gastric cancer patients and can lead to significant morbidity, including nausea, vomiting, abdominal pain, dehydration, malnutrition and weight loss. Not surprisingly, these clinical symptoms have a negative impact on quality of life (QOL)¹⁶. To avoid the disastrous consequences of malignant GOO, appropriate treatment is indispensable, which enables not only an amelioration of the patient's (QOL) but also the commencement of chemotherapy, including essential oral agents, such as S1 or capecitabine¹⁷. These treatments are included in the 1st-line regimen for unresectable gastric cancer recommended in the Japanese gastric cancer treatment guidelines¹⁸.

Patients who are candidates for balloon dilation are likely to present with recurrent GOO. Published series using this technique report success rates of over 76% after multiple dilations¹⁹, though the rate of failure and recurrent obstruction is higher in patients treated with balloon dilatation who have not also been treated for H pylori infection²⁰. Patients who are negative for H pylori do not respond favorably to balloon dilatation and should be considered for surgical treatment early in the process²¹. More than 75% of patients presenting with GOO eventually require surgical intervention²². Surgical intervention usually provides definitive treatment of GOO, but it may result in its own comorbid consequences. Operative management should offer relief of obstruction and correction of acid problems.

In gastric outlet obstruction, bypass surgery (Gastrojejunostomy) can be performed by both open and laparoscopic technique. Gastrojejunostomy is a surgical procedure in which an anastomosis is created between stomach and proximal loop of jejunum. This is usually done for the purpose of draining contents of stomach. Percutaneous Gastrojejunostomy may be performed, in which a tube is placed through the abdominal wall into the stomach and then through the duodenum into the jejunum. The first successful Gastroenterostomy was carried out by Bilioth in 1881. It was performed in a patient with a stomach following partial gastrectomy²³. Later that year while operating on a case of pyloric carcinoma Wolfer noted extension of growth into the pancreas because gastrectomy was not possible, he went on to perform the 1st successful palliative Gastrojejunostomy²⁴. When Bilioth attempted the same procedure his patient succumbed to symptoms and post mortem findings were suggestive of what is today known as afferent loop syndrome. To avoid this complication the technique of the Roux En Y anastomosis was introduced by Wolfer in 1883 and later popularized by Cesar Roux of Lausanne in 1887²⁴.

AIMS AND OBJECTIVES

▪ **Surgical outcome of laparoscopic intracorporeal Roux En Y Gastrojejunostomy suture anastomosis in gastric outlet obstruction**

Study was prospective in nature and aimed at:

- A) To assess the feasibility of the procedure and evaluate patients for Afferent Loop Syndrome post operatively
B) The other aims are:

-) Time for making anastomosis
-) Total hospital stay
-) Return of bowel sounds
-) Post operative complications

MATERIALS AND METHODS

The Study was prospective, observational and hospital based. Study was conducted in the Department of General Surgery, GMC Srinagar. A minimum of 31 patients were selected. After doing the diagnostic laparoscopy the MNT staging was done, the resectability of tumour was assessed. The patients with unresectable tumours or advanced stage tumours underwent laparoscopic gastrojejunostomy by Roux En Y procedure.

INCLUSIONAL CRITERIA

-) Age more than 20 years
-) Both sexes
-) Patients with Gastric outlet obstruction due to malignant conditions of stomach

Exclusional criteria

-) All those who refused to give consent for surgery after explaining the consequences and outcomes of surgery.
-) Patients in whom after doing diagnostic laparoscopy the growth was resectable and needed open laparotomy for definitive surgery.

Procedure

-) After creating pneumoperitoneum using verres needle, a 10mm port is introduced 3.5cm below and to the right of umbilicus to be used as an optical port.
-) Two working ports are created by placing one 5mm/12mm trocar, 5cm away from the optical port on the right side 2cms below subcostal margin in the right midclavicular line and the other 5mm in right midclavicular line 5cms from the optical port.
-) The surgeon stands on right side of patient using those two ports as working ports.
-) After doing initial diagnostic laparoscopy and assessing the resectability of the tumor, the Duodenojejunal junction is identified and the jejunum transected 25cm distal to DJ.
-) The distal limb is brought up as a roux limb and anastomosed with the stomach.
-) The proximal jejunal segment is then anastomosed with the roux limb 40cm from the gastrojejunal anastomosis.

PRE OPERATIVE PREPARATIONS

-) Thorough evaluation as per the protocol.
-) Proper building up of patients.
-) Patients were kept fasting for 24 hours before surgery.

-) Patients were put on Ryle’s tube and stomach was prepared by stomach washes.
-) Preanaesthetic medication was given on the night before surgery.
-) Part preparation was done in the morning on the day of surgery.
-) I.V. antibiotics were given to each patient.
-) Informed and written consent was taken prior to performance of each procedure

RESULTS

This Prospective study was carried out in the department of general Surgery at Government Medical College Srinagar J&K India. A total of 31 patients were included in the study (Laparoscopic Roux En Y hand sewn anastomosis).The results and observations made are as under. Laparoscopic Roux En Y hand sewn anastomosis: comprised of 31 Patients (Table 1) between the age of 53 to 85 years. Mean age is 67.7 years. Maximum no of Patients were in the age range of 60 to 79 years.

Table 1. Age Distribution of study patients

Age(Years)	No of patients	Percentage
50-59	6	19.36
60-69	12	38.71
70-79	10	32.26
80 and >Above	3	9.68
Mean Age		67.7

Laparoscopic Roux EnY hand sewn anastomosis comprised of 31 patients. The number of males was 21 comprising of 67.7% and 10 females comprising of 32.3% (Table 2) Male/Female ratio was 2.1:1.

Table 2. Showing Gender Distribution

Gender	No	Percentage
Male	21	67.7
Female	10	32.3
Ratio		2.1:1

Laparoscopic Roux En Y hand sewn anastomosis The mean time for making anastomosis was 42.7 minutes. The anastomosis time taken ranges from 30 to 60 minutes as shown in Table 3.

Table 3. Time for making Anastomosis among patients

Time (min.)	Number of patients	Percentage
30-40	10	25.81
40-50	18	45.16
50-60	3	29.03
Mean		42.7 Minutes

Laparoscopic Roux En Y hand sewn Anastomosis. The mean post operative hospital stay was 4.3 days. The majority of patients having hospital stay of 4 days as shown in Table 4

Table 4. Total Hospital Stay in days

Hospital Stay (Days)	No.	Percentage
3	8	25.81
4	10	32.26
5	9	29.03
6	3	9.68
7	1	3.23
Total	31	Average 4.32 Days

Laparoscopic Roux En Y hand sewn anastomosis. The mean appearance of bowel sounds was 2.8 days with the maximum falling in the range of 3 days as shown in Table 5.

Table 5 Return of Bowel Sounds among patients

Bowel Sounds (days)	No. of patients	Percentage
1	0	0
2	10	32.26
3	16	51.61
4	5	16.13
Total No. of Patients	31	Mean 2.8 Days

Laparoscopic Roux-En-Y hand sewn Anastomosis. The mean time of resumption of orals was 3.6 days. Orals were started on days ranging from 3 to 5 days as shown in Table 6

Table 6. Showing Resumption of Orals

Resumption of Orals	No	Percentage
3 Days	16	51.61
4 Days	11	35.48
5 Days	4	12.91
	31	Mean 3.6 Days

Laparoscopic Roux En Y Gastro jejunostomy. In the study it was found intra operative anastomotic site haemorrhage to be 9.7 percent, total 3 cases out of 31 patients. No other post operative complications were found as shown in Table 7

Table 7. Postoperative/Intraoperative Complications

Complications	Number	Percentage
Bleeding	3	9.7
Anastomotic Leak	0	0
Fistula Formation	0	0
Intra- Abdominal Abscess	0	0

DISCUSSION

Earlier open Gastrojejunostomy used to be the only method to relieve Gastric outlet obstruction owing to the introduction of endoscopic stenting and laparoscopic surgery, lesser and lesser invasive approaches are now more commonly being used with the advent of laparoscopic and minimal access techniques, different modalities are in use for the treatment of Gastric outlet obstruction from advanced malignancies. Now a days diagnostic laparoscopy is a standard technique followed in all gastrointestinal malignancies for staging the disease and plan its treatment whether palliative or curative.

It provides a bunch of information about the extent of tumour, biopsy of tumour, MNT staging of tumour, analysis of malignant ascites if present, lymph nodal status and implants whether peritoneal or abdominal to the tune of 7mm. In our study our aims and objectives are conclusive and defined. We routinely followed laparoscopy as a modality for diagnosis and even treatment. As earlier a study was conducted in our institution, where around 40 patients diagnosed as Gastric outlet obstruction underwent conventional laparoscopic gastro jejunostomy²⁵. It was seen that a fair number of patients in their follow up complained of alkaline reflux and a few were labeled as having Afferent Loop syndrome which affected their quality of life. Keeping in view the advantage of Roux En Y Gastrojejunostomy over conventional Gastrojejunostomy with regard to the decrease of incidence of Afferent Loop Syndrome. It was decided to do a laparoscopic Roux En Y Gastrojejunostomy in a patient

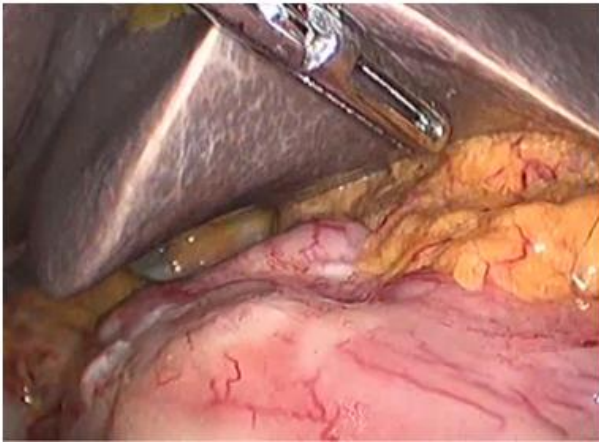


Fig-1 Diagnostic Laparoscopy (Distal Stomach Growth Causing Goo)

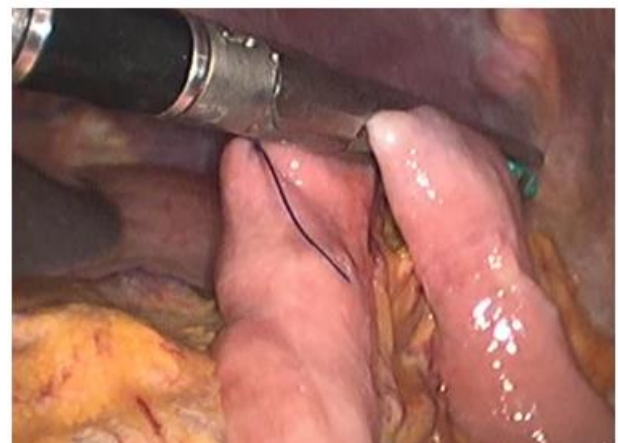


Fig 2 Transection Of Jejunum 25cm Distal To Dj

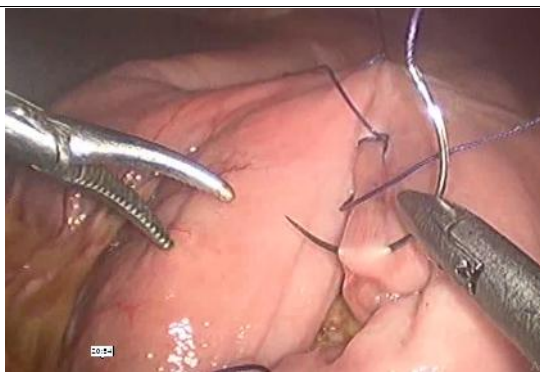

Fig 3 . 4th Layer of anastomosis in progress

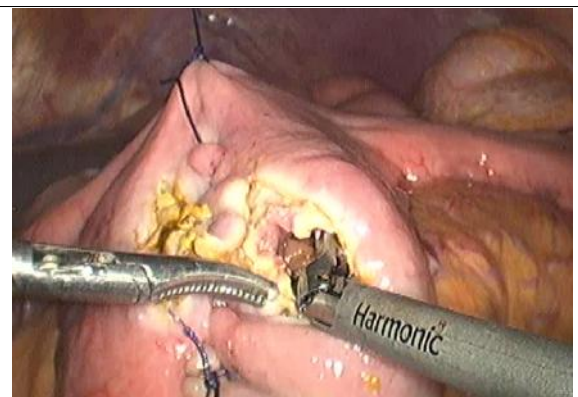

Fig 4. Jejunostomy of Both Limbs

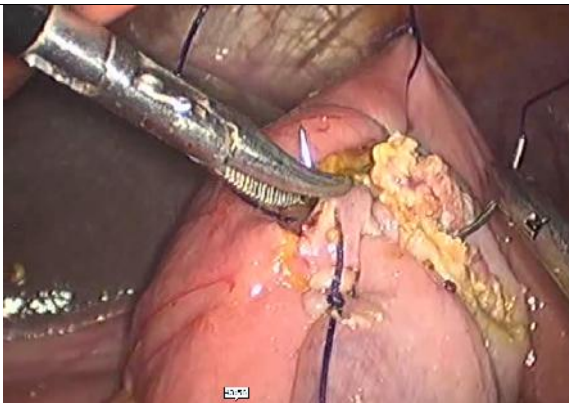


Fig 5. 2nd Layer of Anastomosis In Progress

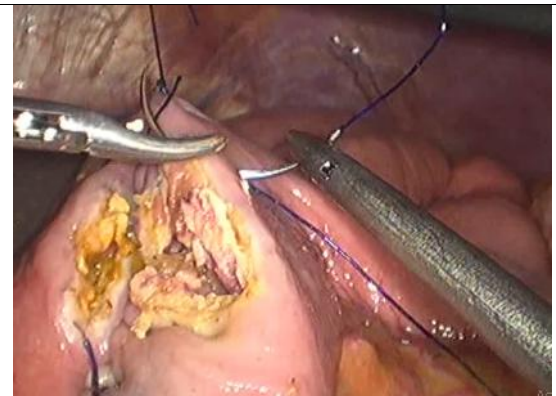

FIG 6. 3rd Layer of Anastomosis In Progress

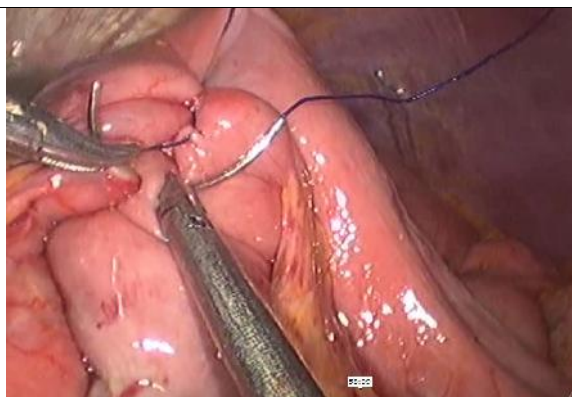


Fig 7. 1ST Layer of Anastomosis In Progress

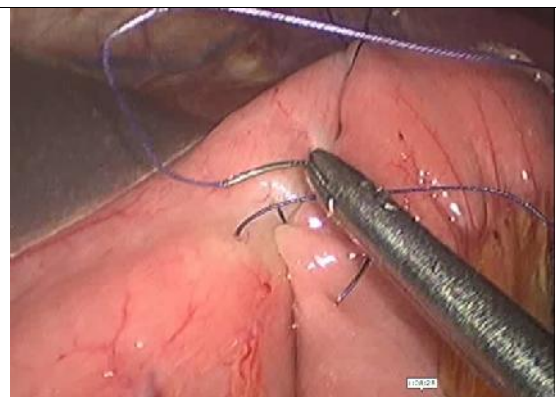

Fig 8. Anchoring Suture Between Stomach And Roux Limb

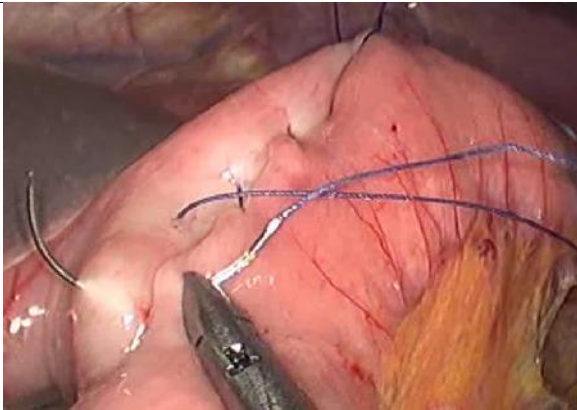


Fig 9. 4th Layer Of Anastomosis Between Stomach And Jejunum (Roux Limb)

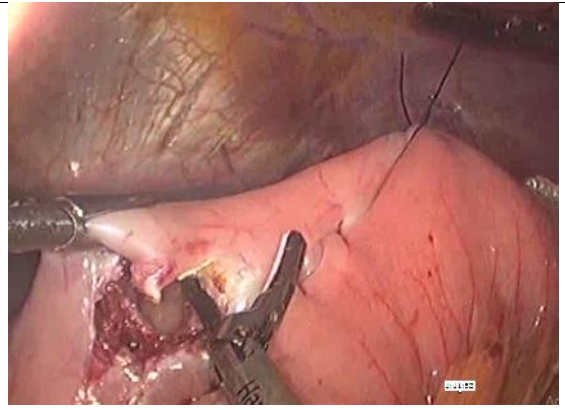


Fig 10. Gastrostomy And Jejunostomy

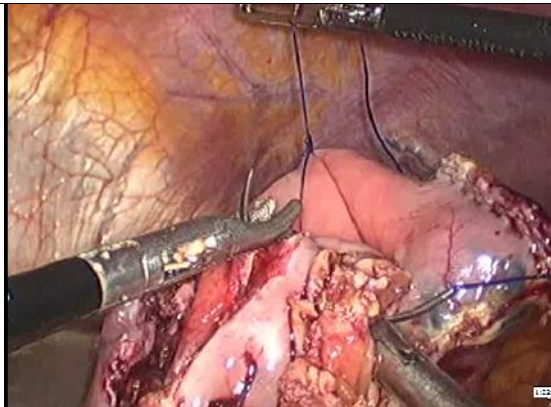


Fig 11. 2nd Layer Of Anastomosis In Progress

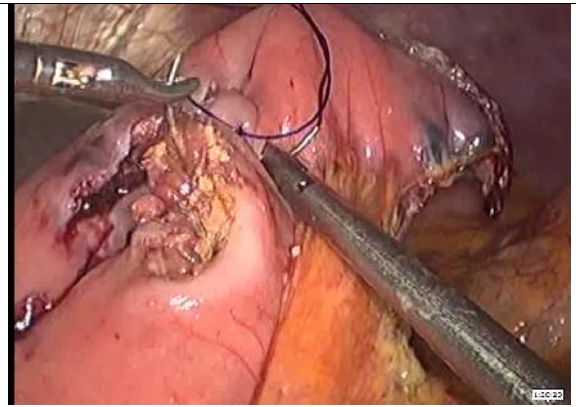


Fig 12. 3rd Layer Of Anastomosis In Progress

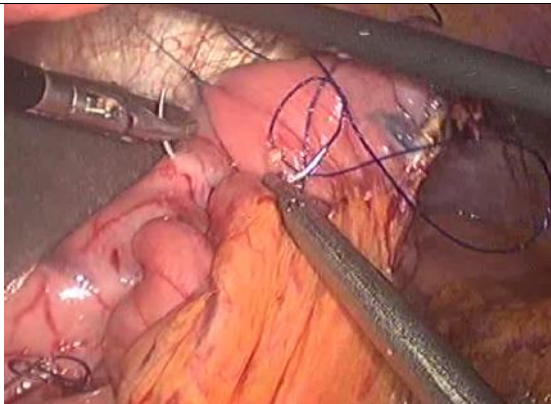


Fig 13. 1st Layer Of Anastomosis In Progress

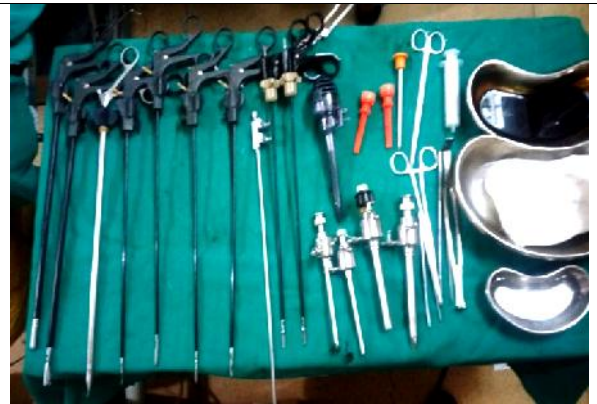

Fig 14. Instruments used in lap. Hand sewn roux en y anastomosis

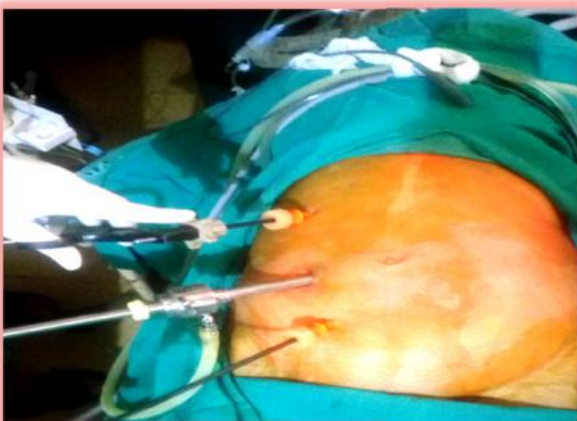

Fig 15. Port Positions

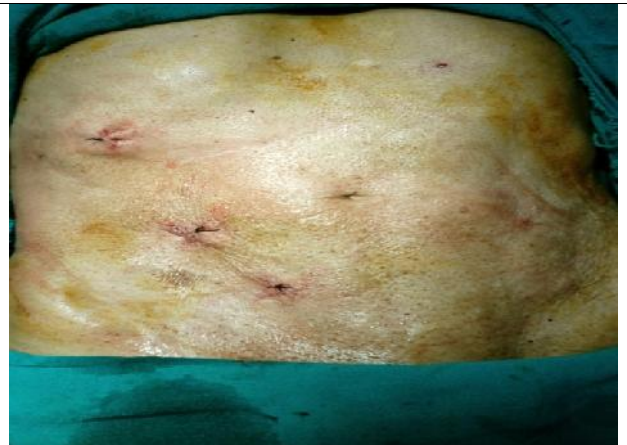


Fig 16. Post Operative Picture

with Gastric outlet obstruction, and this study was taken up in our institute for the first time as an original research thesis work. Usually, Roux En Y anastomosis is done as a part of metabolic and bariatric procedures to treat obesity and its comorbidities especially Diabetes mellitus. Roux En Y Gastric Bypass is a standard technique in this behalf. Roux En Y anastomosis has an advantage of avoiding afferent loop and its complications. We took up the study as a pilot project and applied the same technique of Roux En Y Gastrojejunostomy in patients who came to us with malignant Gastric outlet obstruction and observed the results of this technique. In this study we reviewed our institutes' experience of laparoscopic Roux En Y Gastrojejunostomy as a treatment modality for Gastric outlet obstruction.

Our study (Laparoscopic Roux En Y Gastro Jejunostomy) comprised of 31 patients (Table No. 1) between the age of 53 and 85 years (Average of 67.7 years). Most of the patients were in the age range of 60 to 79 years of age. Study done by Sukumar²⁶ showed the majority of study population was between the age group of 40 and 80 years, with the maximum number of patients falling in the group of 51 to 60 years. Study done by Linda P *et al*²⁷ showed the total of 28 patients with average age of 68 years (range 25 to 99). Study done by Su Hyun Seo *et al*²⁸, the mean age of patient was 60.4 years of age. In our study majority of our patients were males. The study sample showed 21 males and 10 females. Ratio of male / female was 2.1:1. In a study done by Hyasinta Jaka *et al*²⁹ the male female ratio was 3.2:1 for the malignant Gastric outlet obstruction. In a study done by Sukumar *et al*²⁶ the majority of study population were males with a male female ratio of 3.2:1. The finding was concurrent with studies which suggested males are more commonly affected with Gastric outlet obstruction and outnumbered females. In our study the average time taken for creating an anastomosis was 42.7 minutes (Table 3). In a study done by Su Hyun Seo *et al*²⁹ time taken for creating an anastomosis by hand sewn method in Bilroth 2 was 15.2 minutes (Average). In our study time taken was more contrary to Bilroth 2 due to hand sewn Roux En Y anastomosis.

In our study the mean post operative hospital stay was 4.32 days (Table No. 4). In a study done by Su Hyun Seo *et al*²⁹, the mean post operative hospital stay was 7.4 days. In a study done by Linda P *et al*²⁷, the mean length of hospital stay was found 8 days. In a study done by Al Rashdey M, Dadibhai M³⁰ laparoscopic surgery was associated with significantly shorter duration as compared to open procedure and the hospital stay was 3 vs 15. In a study done by Jeurnink *et al*³¹ performed a systematic review of published series on Gastrojejunostomy between 1996 and 2006. Of the 297 cases of Gastrojejunostomy. 226 had open GJ and their average length of stay ranged from 8.5 days to 25 days. In our study the mean time of appearance of bowel sounds were 2.8 days (Table No. 5). In a study by Linda P *et al*²⁸ the mean time of appearance of bowel sounds were found to be 3 days. In a study done by Su Hyun Seo *et al*²⁹ the mean time of appearance of bowel sounds were 2.4 days.

In our study mean time of resumption of orals was 3.6 days (Table No.6). In a study done by Tanaka T, Sudak K, Satoh S³² the mean time of resumption of orals was 3 days. In a study done by Alamet *et al*³³ and Kazanjian *et al* the median time of resumption to solid food after laparoscopic Gastro Jejunostomy was 4 days. As we understand the

complications are part of any surgery performed. But in our study complication rate was on a lesser ebb than mentioned in the literature. Among the various complications of laparoscopic Roux En Y Gastro Jejunostomy we found intraoperative anastomotic site hemorrhage to the tune of 9.7% in 3 cases among 31 patients. In a study done by Radrigo Gonzalez³⁴ out of 108 patients with 87 patients had hand sewn anastomosis and 21 had stapled one. Anastomosis related hemorrhage was Hand sewn 2 and Stapled 1.

In our study we did not find any leakage of anastomosis, intra-abdominal abscess or fistula formation as shown in Table No. 7. It is important to mention that we observed contrast results as regarded with complications of procedure mentioned in various literatures. In a study by Frank P Bendewald³⁵ the anastomotic leakage was found 1.1 percent in laparoscopic hand sewn anastomosis and 1 percent in laparoscopic stapled anastomosis. While in the study done by Hira Hara N³⁶, Matsubara T neither anastomotic leakage nor anastomotic stricture was observed. The contrast results as regards with complication of the procedure mentioned in the literature were possibly because the single surgeon performed the procedure and the patients were properly optimized with a special reference to a clinical built, Haemoglobin level, plasma proteins and preparation of stomach and small bowel.

Afferent loop syndrome is an uncommon mechanical complication that can occur after various Gastro intestinal procedures involving anastomosis of stomach or esophagus to the jejunum. Classically described with Bilroth 2 Gastro jejunostomy, other common procedures such as Roux En Y Gastrojejunostomy, Roux En Y esophagojejunostomy, Whipples procedure and RYGB are also associated with Afferent loop Syndrome. Following a Billroth 2 reconstruction the afferent loop is comprised of the gastric/duodenal stump, duodenum, and short segment of jejunum proximal to Gastrojejunostomy. Following a RYGB the bilio pancreatic limb remains connected to the remnant stomach and is anastomosed distally via jejunojunction. The afferent limb transfers bile pancreatic and proximal intestinal secretions distally towards the anastomosis. The efferent loop receives and transfers the ingested food and liquids.

Afferent loop syndrome is defined by distal obstruction causing distention of the afferent limb secondary to the accumulation of bile, pancreatic fluid and proximal small bowel secretions. In our study the patients on follow up were asked for symptoms which would suggest Afferent loop syndrome. It was found symptoms were not purely attributable to the syndrome complex, thereby it would be difficult to comment on the percentage of patients who truly presented with Afferent loop syndrome. However as per the study done by Takata K, Anan A, Umeda K, Sakisaka S *et al*³⁷ incidence of afferent loop syndrome was as low as 0.2 percent in laparoscopic Roux En Y Gastrojejunostomy contrary to 1 percent in Bilroth 2 reconstruction, same results were observed in the study done by M Aoki, M Saka, S Morita, T. Fukagawa *et al*³⁸.

Conclusion

) Laparoscopic Roux En Y Gastrojejunostomy is effective in achieving weight loss and quality of life

J Chances of developing Afferent Loop Syndrome are least in Roux En Y reconstruction.

REFERENCES

- Samad A, Whanzana TW, Shoukat I. Gastric outlet obstruction: Change in etiology. *Pak J Surg* 2007; 23: 29-32.
- Johnson CD. Gastric outlet obstruction malignant until proved otherwise. *Am J Gastroenterol* 1995; 90: 17-40.
- Tendler DA. Malignant gastric outlet obstruction: Bridging another divide. *Am J Gastroenterol* 2002; 97: 4-6.
- Lans HS, Stein IF Jr, Meyer KA. Electrolyte abnormalities in pyloric obstruction resulting from peptic ulcer or gastric carcinoma. *Ann Surg* 1952; 135: 441-53.
- Shone DN, Nikoomanesh P, Smith Meek MM, Bender JS. Malignancy is the most common cause of gastric outlet obstruction in the era of H2 blockers. *Am J Gastroenterol* 1995; 90: 1769-70
- Lunet N, Barros H. Helicobacter Pylori infection and gastric cancer: Facing the enigmas. *Int J Cancer* 2003; 106:953-60
- Khuroo MS, Zargar SA, Mahajan R, Bandsy MA,. High incidence of oesophageal and gastric cancer in Kashmir in a population with special personal and dietary habits. *Gut* 1992; 33:11-5
- Pavithran K, Doval DC, Panday KK,. Gastric cancer in india. *Gastric cancer* 2002;240-3
- Del piano M, Ballare M, Montino F, Todesco A, Orsello M, Magnani C, Garello E. Endoscopy or surgery for malignant GI outlet obstruction? *GastrointestEndosc.* 2005; 61: 421-426.
- Pinto Pabon IT, Diaz LP, Ruiz De Adana JC, Lopez Herrero J. Gastric and duodenal stents: follow-up and complications. *CardiovascInterventRadiol.* 2001; 24:147-153.
- Park KB, Do YS, Kang WK, Choo SW, Han YH, Suh SW, Lee SJ, Park KS, Choo IW. Malignant obstruction of gastric outlet and duodenum: Palliation with flexible covered metallic stents. *Radiology.* 2001; 219: 679-683.
- Lopera JE, Brazzini A, Gonzales A, Castaneda-Zuniga WR. Gastroduodenal stent placement: current status. *Radiographics.* 2004; 24: 1561-1773.
- Carcas LP. Gastric cancer review. *J Carcinog* 2014; 13: 14.
- Kokkola A, Sipponen P, Arkkila P, Danielson H, PU Olakkainen P. Does the eradication of Helicobacter pylori delay the diagnosis of Gastric cancer? *Scand J Gastroenterol.* 2008; 43: 1456-1460.
- Legman RL, Davix MP, LeGrand SB, Walsh D. Common symptoms in advanced cancer. *SurgClin North Am.* 2005; 85: 237-255.
- Adler DG, Baron TH. Endoscopic palliation of malignant gastric outlet obstruction using self-expanding metal stents: experience in 36 patients. *Am J Gastroenterol.* 2002; 78.
- Pasini F, Fraccon AP, DE Manzoni G. The role of chemotherapy in metastatic gastric cancer. *Anticancer Res.* 2011; 31: 3543-3554.
- Japanese Gastric Cancer Association. Japanese gastric cancer treatment guidelines 2010(ver.3) Gastric cancer. 2011; 14: 113-123.
- Lam YH, Lau JY, Fung TM, ,et al . Endoscopic balloon dilation for benign gastric outlet obstruction with or without Helicobacter Pylori infection . *Gastrointest Endosc.*2004 Aug ; 60(20):229-33
- Taskin V, Gurer I, Ozyilkan E, Sare M, Hilmioglu F. Effect of Helicobacter pylori eradication on peptic ulcer disease complicated with outlet obstruction. *Helicobacter* 2000 Mar; 5(1):38-40
- Gouma DJ, van Geenen R, van Gulik T, de Wit LT, Obertop H. Surgical palliative treatment in bilio-pancreatic malignancy. *Ann Oncol.*1999 Suppl 4:269-72
- Doberneck RC, Berndt GA. Delayed gastric emptying after palliative Gastrojejunostomy for carcinoma of pancreas. *Arch Surg* 1987 July;122(7):827-9
- Billroth T. OffenenschreibenanHerrn Dr. Wittelshofer. *Wien Med Wochenschr.* 1881; 31: 162-5.
- Robinson JO. The history of gastric surgery. *Postgrad Med J.* 1960 Dec; 36: 706-13.
- Mushtaq C, et al. A Short Term Outcome of Laparoscopic Hand Sewn and Stapled Gastrojejunostomy in Gastric Outlet Obstruction - An Observational Study. *Int J Surg Surgical Tech* 2018, 2(2): 000118.
- Siu kumar, ChirukandathRavindran, Ramachandra Venkateshwara. Demographic and etiological patterns of gastric outlet obstruction inKerela , South India. *North American Journal of Medical Science* 2015 Sept; 7(9): 403
- Linda P, Zhang, ParissaTabarizian, Sccott Nguyen, Dana Telem,and Celia Divino. LaparoscopicGastrojejunostomyfor the treatment of gastric outlet obstruction. *Journal of the Society of Laparoendoscopic Surgeons / Society of Laparoendoscopic Surgeons* 2011 April; 15(2): 169-73
- Su Hyun Seo, Ki Han Kim, Min Chan Kim. Hong Jo Choi,, and GhapJoong Jung. Comparitive study of Hand- Sutured versus Circular Stapled. *Korea J Gastric Cancer* 2012; 12(2) :120-125
- HyasintaJaka, Mabula D Mchembe, Peter F Rambau and Phillipo L Chalya. Gastric Outlet Obstruction at Bugando Medical Center in Northwestern Tanzania:a prospective review of 184 cases. *BMC Surgery* 2013; 13:41
- Al- Rashedy M, Dadibhai M, Shareif A, khandelwal MI, Ballester P, Abid G, McCloy RF,Ammoni BJ, Laparoscopic gastric bypass for gastric outlet obstruction is associated with smoother, faster recovery and shorter hospital stay compared with open surgery. *J Hepatobiliary Pancreat Surg.* 2005; 12: 474-478
- Jeurnink SM, van Eijck CH, Steyerberg EW, Kuipers EJ, Siersema PD. Stent versus Gastrojejunostomy for the palliation of gastric outlet obstruction.: a systematic review . *BMC Gastroenterol.*2007 Jun; 7 :18
- Tanaka T, Suda K, Satoh S, Kawamura Y, Inaba K, Isshida Y. Effectiveness of laparoscopic stomach portioning Gastrojejunostomy for patients with gastric outlet obstruction caused by advanced gastric cancer: *UyamaSurgEndosc.* 2017 Jan; (1):359-367-367
- Alam TA, Baines M, Parker MC. The management of gastric outlet obstruction secondary to in operable cancer. *SurgEndosc* 2003 Feb ; 17(2):320-3
- Rodrigo Gonzalez et al. Gastrojejunostomy During Laparoscopic Gastric Bypass- Analyses of 3 Techniques. *Archives of Surgery* 2003; Vol .138

35. Frank P. Bendewald , Jennifer N. Choi, Lorie S. Blythe , Don J, Selzer John H. Ditslear, Samer S. Mattar. Comparison of hand –sewn, linear stapled and circular stapled Gastrojejunostomy in laparoscopic RAOUX - EN- Y Gastric bypass. Journal Obesity Surgery Nov 2011; Vol 21
36. Hirahara N, Matsubara T, Hyakudomi R, Hari Y, Fujii, Tajima Y, J LaparoendoscAdvSurg Laparoscopic Roux en Y Technique A 2014 March ; 24(3): 177-82. Doi 10.1089/lap.2013. Epub 2014 Feb 20
37. TakataK,Anan A, Umeda K, Sakisaka S. Magnetic resonance cholangiopancreatography for afferent loop syndrome. Clin Case Rep. 2019 March; 7(3):591-592.[PMC free article];[PMC 6406143. PubMed:30899506]
38. Aoki M, Saka M, Morita S, Fukagawa T, Katai H. Afferent loop obstruction after distal gastrectomy with Roux en y reconstruction World J Surg 2010; 34:2389-92
