



CASE REPORT: RESIN BONDED FIXED PARTIAL DENTURE- AN INNOVATIVE ESTHETIC AND FUNCTIONAL REHABILITATION OF MAXILLARY ANTERIOR TEETH

¹Dr. Shikha Jaiswal, ²Dr. Sachin Gupta, ³Dr. Vineeta Nikhil and ^{4,*}Dr. Somya Panwar

^{1,2}Professor, Department of Conservative Dentistry & Endodontics, Subharti Dental College and Hospital, Meerut

³Professor and Head of Department, Department of Conservative Dentistry & Endodontics Subharti Dental College and Hospital, Meerut

⁴Post-graduate student, Department of Conservative Dentistry & Endodontics, Subharti Dental College and Hospital, Meerut

ARTICLE INFO

Article History:

Received 15th January, 2021

Received in revised form

19th February, 2021

Accepted 20th March, 2021

Published online 30th April, 2021

Key Words:

Resin bonded prosthesis, Natural tooth pontic, Fibre-reinforced composite, Ribbond

ABSTRACT

Loss of tooth in the anterior region is a deeply traumatic experience for a patient and requires an immediate aesthetic replacement. Resin bonded prostheses are an innovative alternative to traditional treatment providing an immediate cost effective alternative for direct tooth replacement with excellent aesthetics. This case report highlights the use of patient's own tooth as pontic and presents an immediate conservative restorative solution which leaves open other treatment options for the future.

Copyright © 2021. Shikha Jaiswal et al. This is an open access article distributed under the Creative Commons Attribution License, which permits unrestricted use, distribution, and reproduction in any medium, provided the original work is properly cited.

Citation: Dr. Shikha Jaiswal, Dr. Sachin Gupta, Dr. Vineeta Nikhil and Dr.Somya Panwar. "Case Report: Resin Bonded fixed partial denture- an innovative esthetic and functional rehabilitation of maxillary anterior teeth", 2021. International Journal of Current Research, 13, (04, xxxv-xxxx).

INTRODUCTION

Loss of tooth in the anterior region is a deeply traumatic experience for a patient because of the compromised aesthetics and it therefore requires an immediate aesthetic replacement.¹ This replacement can be temporary, semi-permanent and permanent in nature, a course of treatment is decided upon by the patient and the dentist based on what the patient desires depending on various clinical and economic factors.² Final restoration could vary from removable prosthesis to tooth supported fixed prosthesis or the implant supported prosthesis but sometimes definitive treatment may require short fibre reinforced composite.^{3,5}

or long term temporizations to restore the patients aesthetic while stabilizing the compromised arch functionally.^{2,3} This temporization can be achieved with the help of a resin bonded fixed partial prosthesis with the use of natural tooth pontic and these resin bonded prostheses are an innovative alternative to traditional treatment providing an immediate, direct tooth replacement with excellent aesthetics (similar shape, size and color of pontic) and function and are called as Resin Bonded Fixed Partial Dentures (RBFDPs) which use stronger composite materials like bondable polyethylene fibres.^{5,6} First introduced into dentistry in 1970s for periodontal splinting, RBFDPs can be prepared by minimal preparation of natural abutments; thereby preserving the natural tooth structure (with reduction of pulpal morbidity).^{7,8} It is well-suited for patients who require an extraction in an aesthetic area and desire an immediate replacement of a tooth with hopeless prognosis and are not candidates for implant

*Corresponding author: Dr. Somya Panwar,
Post-graduate student, Department of Conservative Dentistry & Endodontics, Subharti Dental College and Hospital, Meerut.

therapy.⁴ This case report highlights the use of patient's own tooth as pontic and presents an immediate conservative restorative solution with no additional laboratory procedure.

Case report

A 24 year old male patient reported to the Department of Conservative Dentistry and Endodontics, Subharti Dental College and Hospital with chief complaint of mobile upper front tooth. Past dental history revealed trauma one month back. Clinically, the patient presented with grade II mobility with respect to 21. Radiograph revealed horizontal root fracture in the cervical third of the root [Figure 1(a),(b)]. After clinical and radiographic evaluation, it was decided to extract 21 due to poor prognosis. Replacement options for the resulting edentulous space were discussed with the patient. Due to time constraints and patient's financial condition, it was planned to use the crown of same extracted tooth as a replacement prosthesis. The patient was duly informed about possible limitations and outcome of the procedure and an informed consent was taken. Extraction of 21 was performed under local anaesthesia with all aseptic measures and avoiding any traumatic tear of the marginal gingiva and interdental papilla. On recall after 2 weeks, an uneventful healing of soft tissues was confirmed [Figure 1(c)] after which impressions followed by diagnostic casts were made for both maxillary and mandibular arches.

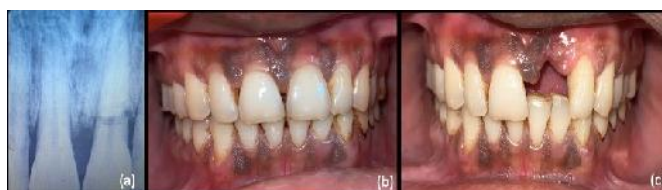

Figure 1

(a) Pre-operative intra-oral periapical radiograph showing horizontal root fracture in the coronal third in relation to tooth 21. (b) Pre-operative intra-oral image (c) Image showing healed extraction socket

The extracted tooth was cleaned of debris using scalers and root amputation was done using straight fissure diamond points [Figure 2(a), (b)]. Following pulp removal, the coronal portion of pulp chamber was cleaned with 3% NaOCl and the pulp chamber was sealed at the site of amputation with a micro-filled hybrid composite (FILTEK Z 250, 3M ESPE) [Figure 2(c)] and designed into an ovate pontic shape using composite resin.

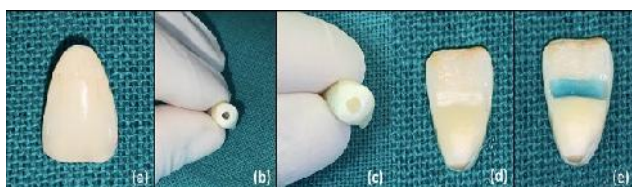


Figure 2.

(a) Image showing the pontic after root amputation
(b) Image showing retro-grade access cavity preparation for removal of coronal pulp
(c) Image showing the pulp chamber sealed with composite
(d) Image showing transverse groove formation on the pontic
(e) Acid etching of the groove prepared

Prepared pontic was first tried on the cast and then intra-orally for proper positioning and tightness of proximal contacts. The pontic was then adjusted mesially and distally for achieving passive contacts. Class III cavities with palatal extension were prepared on the mesial surface of 11 and 22 to aid in retention and stabilization with Ribbond (Ribbond Inc., Seattle WA). The required length of Ribbond fibre was measured using dental floss between the adjacent teeth 11 and 22 on the cast. Two pieces of adjusted length of Ribbond fibre (Ribbond Inc., Seattle WA) were cut and soaked in dentin bonding agent and kept away from light.

A transverse groove was made on the pontic surface at the same level as that of the class III cavities on the adjacent teeth [Figure 2(d)]. Conservative class III cavities on 11 and 22 along with the transverse groove on the pontic tooth 21 were etched with 37% phosphoric acid (Scotchbond Etchant; 3M ESPE, St. Paul, MN, USA) [Figure 2(e)]. Thereafter, the teeth surfaces were rinsed with water and air-dried followed by application of bonding agent (Adper_Single Bond 2; 3M ESPE) which was light-cured for 20 seconds using Woodpecker curing light (Guilin Woodpecker Instrument cp., Ltd). The tooth pontic was then carried into the desired position and stabilized. A thin layer of flowable composite resin was applied to the palatal surface of the pontic and the adjacent teeth, the Ribbond fibre was then pressed into the resin with the aid of a composite hand instrument to ensure its close adaptation on to the pontic as well as the adjacent tooth surfaces. The assembly was light-cured from palatal and labial directions. Excess bulk of resin was removed from palatal and embrasure areas and esthetic contouring & polishing of the conservative bridge was done [Figure 3]. The patient was informed about the importance of proper hygiene and a regular follow up. A six months follow up showed an intact and functional bridge [Figure 4 (a), (b), (c)].

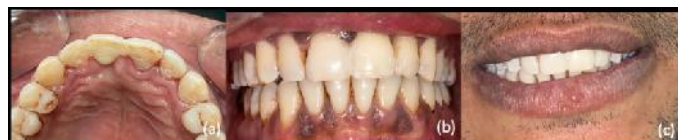

Figure 3.

(a) Image showing palatal view of the resin bonded fixed partial denture b. Post-operative view of the patient, c. After 6 months follow up

DISCUSSION

Immediate replacement of lost anterior teeth becomes imperative not only for the restoration of aesthetics and function but also for the prevention of social trauma. In the present case, replacement of a single tooth with natural tooth pontic using bondable reinforcement ribbon was preferred to immediately restore the aesthetics of patient because this chair side technique does not require laboratory procedures and provides a natural and esthetic option for immediate replacement of extracted tooth. Natural tooth pontic could be a suitable alternative in such clinical scenario as it is a simple and low-cost treatment option for the replacement of a tooth using its own crown portion.⁴ The natural tooth used as a pontic provides the advantages of being the right size, proper color and shape as well as provides positive patient reinforcement.^{5,6} Another major advantage of retaining the patient's natural crown is that the patient can better tolerate the

effect of tooth loss psychologically.⁴ The development of adhesive systems has allowed treatment options with minimally invasive preparations.⁸ Bonding of the pontic to adjacent teeth is important for the success of conservative bridges.³ This can be achieved by use of Fibre-reinforced composites (FRCs) which are structurally made up of two components: the fibers and the resin matrix. The resin matrix serves as carrier, protector and load-splicing medium around the fibers.⁶ Ribbond (Ribbond, Seattle, WA, USA) is made from an ultrahigh modulus, ultrahigh molecular weight polyethylene fiber that is woven into a porous ribbon. The manufacturers of Ribbond advise a double thickness of the fiber for bridges, this creates a structural laminate of composite resin and Ribbond which doubles the fracture strength of the composite resin.¹ Therefore in the present case, double thickness of Ribbond was used as a base for the natural tooth pontic. It is suspected that this double thickness creates a beam effect that increases the tensile strength to a point where it was equal to or greater than the sum of its components, extending the longevity of the restoration.⁴ A 5-year clinical follow-up pilot study showed a functional survival rate of glass-FRC 93% and an overall survival rate of 75%.⁸ Quirynen *et al.* conducted a long term prospective study using natural teeth and acrylic resin teeth as pontics following loss of lower anterior teeth due to periodontal breakdown have reported a favorable long term results.⁹ Similarly, Kumar *et al.* concluded that natural tooth pontic promising treatment option in immediate esthetic rehabilitation and demonstrated favourable results after one year follow up.¹⁰

CONCLUSION

Natural tooth pontic can provide a simple, economical and conservative treatment option for restoring a single anterior tooth using the patient's own extracted tooth and it serves as an excellent functional, aesthetic provisional restoration adopting a minimally invasive restorative solution which leaves open other treatment options for the future.

REFERENCES

1. Arteaga S, Meiers JC. Single-tooth replacement with a chairside prefabricated fiber-reinforced resin composite bridge: a case study. *Gen Dent* 2004;52:517-9.
2. Higginbottom F, Belser U, Jones JD, Keith SE. Prosthetic management of implants in the esthetic zone. *Int J Oral Maxillofac Implants* 2004;19:62-72.
3. Ulusoy AT, Cehreli ZC. Provisional use of a natural tooth crown following failure of replantation: A case report. *Dent Traumatol.* 2008;24:96-9.
4. Gupta S, Nikhil V, Jaiswal S, Verma M. Conservative Bridge With Natural Tooth Pontic: A Case Report. *Int J of Clinical Dental Science* 2011;2(2):58-64.
5. Kretschmar JL. The natural tooth pontic: A temporary solution for a difficult esthetic situation. *J Am Dent Assoc.* 2001;132:1552-3.
6. Strassler HE, LoPresti J, Schere W, Rudo D. Clinical evaluation of a woven polyethylene ribbon used for splinting. *Esthetic Dentistry Update* 1995;6:80-4.
7. Strassler HE, Serio FG. Stabilization of the natural dentition in periodontal cases using adhesive restorative materials. *Periodontal insights.* 1997;31:4-10.
8. Vallittu, P. Survival rates of resin-bonded, glass fiber composite fixed partial dentures with a mean follow-up of 42 months: a pilot study. *J Pros Dent.* 2004;91:241-6.
9. Quirynen M, Mongardini C, Lambrechts P, Geyseler CD, Labella R, Vanherle G, *et al.* A long term evaluation of composite bonded natural/resin teeth as replacement of lower incisors with terminal periodontitis. *J Periodontol.* 1999;70:205-12.
10. Kumar P, Nujella S, Gopal S, Roy K. Immediate Esthetic Rehabilitation of Periodontally Compromised Anterior Tooth Using Natural Tooth as Pontic. *Case Reports in Dentistry*, vol. 2016, Article ID 8130352
