



ISSN: 0975-833X

Available online at <http://www.journalcra.com>

International Journal of Current Research
Vol. 14, Issue, 08, pp.22157-22161, August, 2022
DOI: <https://doi.org/10.24941/ijcr.43937.08.2022>

INTERNATIONAL JOURNAL
OF CURRENT RESEARCH

REVIEW ARTICLE

TYPES OF ENDODONTIC EMERGENCIES AND THEIR TREATMENT PLAN: A SYSTEMIC REVIEW ARTICLE

1,*Aakriti Chadha, 2Ria Treesa Raju, 3Nitya Jha and 4Aditi Khairmode

¹Intern, Genesis Institute of Dental Sciences and Research, Ferozepur, Punjab, ²Dentist, JSS Dental College and Hospital, Mysore, Karnataka, ³Associate Dentist, NSVK Sri Venkateshwara Dental College and Hospital, Bengaluru, ⁴Clinical associate, Government Dental College and Hospital, Mumbai

ARTICLE INFO

Article History:

Received 19th May, 2022
Received in revised form
15th June, 2022
Accepted 24th July, 2022
Published online 30th August, 2022

ABSTRACT

Dentists often come across patients who come to the clinic with the requirement of urgent treatment, and therefore the dentist must always be well equipped with knowledge and skills to be able to treat their patients in such emergency situations. In this review article, we will discuss some of the ways by which such situations can be handled.

Key words:

Endodontic Emergencies, Cracked Tooth Syndrome, Avulsion, Endodontic Flareup, Fractured Tooth, Endodontic Pain, Medication, Root Canal, Failed Treatment, Emergencies, Antibiotics.

*Corresponding Author:

Aakriti Chadha

Copyright©2022, Aakriti Chadha et al. This is an open access article distributed under the Creative Commons Attribution License, which permits unrestricted use, distribution, and reproduction in any medium, provided the original work is properly cited.

Citation: Aakriti Chadha, Ria Treesa Raju, Nitya Jha and Aditi Khairmode. 2022. "Types of endodontic emergencies and their treatment plan: A systemic review article". International Journal of Current Research, 14, (08), 22157-22161.

INTRODUCTION

An endodontic emergency is defined as a condition wherein the patient rushes to the dental clinic for the treatment of an irresistible type of pain that may begin before the actual treatment starts or may be in between the appointments. Emergencies may involve pain and can also involve swelling and other signs of infection. Some of the most common endodontic emergencies are cracked tooth syndrome, tooth avulsion, fractured tooth, endodontic flareup and pain. Determining the cause of pain and treatment planning is a crucial step in the management of an endodontic emergency. The purpose of this article is to enumerate some of the dental emergencies and throw light on their treatment procedures.

CRACKED TOOTH SYNDROME: Cracked tooth syndrome is an incomplete fracture of a vital posterior tooth which involves dentine and possibly the dental pulp' and may also be called as "split tooth syndrome" (1). Often the fracture line follows a mesiodistal direction however, in lower molars, the crack may run buccolingually (2). Biting forces of high intensity usually generate very high occlusal forces which may predispose the tooth to a crack (3). The type of pain is sharp and short and occurs as a result of the fluid movements in the

dental tubules when the fractured fragments separate during chewing movements. The gap created between the fractured fragments may give access to bacteria into the pulp and results in pulpal inflammation. Therefore, a dull ache associated with the hypersensitivity to cold and, occasionally, hot stimuli can be seen associated with the tooth that has a crack (1).

DIAGNOSIS: Early diagnosis is important in case of crack tooth syndrome to avoid any complex condition. In these cases, patients usually give a history of pain when the bite is released on a particular tooth which later on may become sensitive to cold, sweet or hot (3). Dyes like methylene blue is used to identify the cracks, bitewing radiographs are recommended because the fracture may not be visible on a periapical film (2). Tooth Slothscan be appropriate for locating the crack. Visual inspection is done to identify the position and extent of the fracture (4). Wear facets can be seen on the occlusal tooth surfaces during the time of diagnosis (5).

MANAGEMENT: The definitive treatment plan will depend on position of the crack, amount tooth structure remaining, type of restoration (6). Stability of the crack can be increased by preserving maximum of the coronal structure.

Cracked portion of small size without pulp involvement, requires normal restoration. However, a larger portion of tooth crack involving pulp, may require special treatment for stabilization like an orthodontic stainless-steel band. Occlusal adjustment can lead to immediate relief of symptom (7). Although neither dentin nor enamel can be permanently reunited and eventually the crack in the tooth may lead to separation. Managing cracked tooth can be done as follows:

- **Adhesives:** Amalgam, bonded resin composite restorations are known to be good adhesives that have been shown to strengthen a tooth after cavity preparation, however, they can't provide a lifelong solution if the cusps are subject to continual forces in that case, fatigue failure of the bond will be progressive with time (4).
- **Dental amalgam, composite resin and glass-ionomer cements** are most commonly used to restore the strength of the tooth (8).
- **To avoid pain, simvastatin is used as an intracanal medicament** to seal the tooth crack because it can stimulate dentin formation. Antioxidant, and wound/bone healing properties explains healing and rapid relief of pain after application of the material inside the canal (9).
- **Immobilisation:** Immobilisation or splinting of the affected tooth, so as to prevent the independent movement of the fractured portions upon occlusal loading helps to prevent further progression of the fracture plane (10).

ENDODONTIC FLAREUP: A flare-up is defined as the occurrence of severe pain and swelling following an endodontic treatment appointment, requiring an unscheduled visit and active treatment and incident rates of these cases are very high. If the periradicular tissue is damaged during the manipulation of the root canal, then an acute inflammatory response, called a flare-up, begins and cause pain and swelling (11). It may occur in patients with conditions like periapical abscess, acute apical periodontitis, preoperative pain and swelling. *F. nucleatum*, *Prevotella* species, and *Porphyromonas* species are some of the species isolated from flare-up cases (12). Post endodontic pain most often occurs during the first 24 to 48 hours after the initiation of the endodontic treatment and may be due to biological or non-biological reasons (13).

Diagnosis: The initial step in the treatment is to understand the biological process resulting in pain, which can be done by making the correct diagnosis. Evaluating the nature of pain i.e. odontogenic or non-odontogenic, pulpal or periradicular, inflamed or infected. Evaluation of the condition of pulp whether it is vital or non-vital and involvement of periradicular tissue is also important. Subjective clinical tests like thermal, electrical, percussion, are also done (14). Sometimes procedures like incorrect determination of working length, straightening of curved root canals, over-extension and overpreparation may also be diagnosed as the cause (15) and even selective growth of certain bacterial species inside the root canal as a result of ecologic changes during endodontic therapy may prove to be the cause (16).

MANAGEMENT: For prevention of an endodontic flareup, asepsis is an important factor to be considered. Endodontic treatment should always be carried out in aseptic conditions which can be done by using rubber dams. Treatment procedures like pulpectomy, trephination, incision and drainage, occlusion reduction, anxiety and stress management may help in treating flareups. (17) The use of NSAIDs before the beginning of the operation or immediately after the operation also spares the patient from such kinds of pain. Steroidal anti-inflammatory drugs are effective in reducing pain intensity in the first 24 h after a primary root canal treatment. The efficacy of these drugs is potentially influenced by the type and dose of the drug (18) The use of preoperative medicines such as: Ibuprofen, dexamethasone, diclofenac sodium, piroxicam, deflazacort, ketrolac or prednisolone, especially in cases with symptomatic irreversible pulpitis may prove to be beneficial. Ibuprofen (600 mg) alone and ibuprofen (600 mg) combined with acetaminophen (1000 mg) are significantly more effective in post-operative endodontic pain control and may be, therefore, recommended as a first-choice treatment in the

first hours following nonsurgical endodontic treatment. In addition, ketoprofen (50 mg) as well as naproxen (500 mg) might be even more effective than ibuprofen (600 mg) alone 6 h post-operatively. The preferred chemical-mechanical procedure should be to ensure that the amount of debris extrusion in the periradicular area should be minimum, and ensuring the debridement of the totality of the root canal system. It is also advisable to make use of apex locator and radiology is essential for precisising the working length WL, these may help to enhance the irrigation efficacy (19). The proper use of disinfectants like sodium hypochlorite can maximize the success of the procedure because its not only keeps the canal space disinfected, but also dissolves tissue remnants in the canal space.

FRACTURED TOOTH: Complete crown fractures which involve enamel, dentin and pulp occurs in 0.9-18% of all the dental injuries and accounts for majority of dental trauma in the permanent dentition, while crown-root fractures which involve enamel, dentin, cementum and represent only 0.3-5% (20,21). The crown-root fractures may be complicated or uncomplicated based on pulpal involvement. Around 85% of the fractures are in an oblique direction with the fracture line running from labial to lingual aspects.

DIAGNOSIS: To diagnose a tooth fracture, multiple radiographs are taken from various angles which helps to provide a clear image, generally, parallel periapical radiograph, occlusal radiograph and tube are done. Cone beam computed tomography is very useful in identification of fracture (22). These help to demonstrate fracture line which may be oriented obliquely in the apical- and middle-third of the root and is more horizontally oriented in the cervical third.

MANAGEMENT: The first thing that should be done after a tooth fractures is seek advise of a dentist over the phone and follow the instructions given by the dentist. If the tooth is vital at the time of fracture, we should plan aesthetic restoration during growth development period, however, in case of non-vital tooth pulp therapy becomes the preferred treatment plan. In class 1 fracture (where the fracture only involves the enamel), treatment is usually not the most critical part, however, in case of small chip of enamel, the edges are smoothed and then fluoride application is done on the fractured portion to provide strength to the surface. In case of a class 2 tooth fracture (where the fracture involves both enamel and dentin), the tooth requires restoration with materials like GIC and Calcium hydroxide and after the restoration, the patient is put on follow ups. In class 3 fracture of the tooth (where fracture involves the pulp) the treatment plan usually becomes pulpectomy with ZOE or vitapex. Extraction may be required when the underlying developing tooth may pose a risk of damage from the periapical pathology.

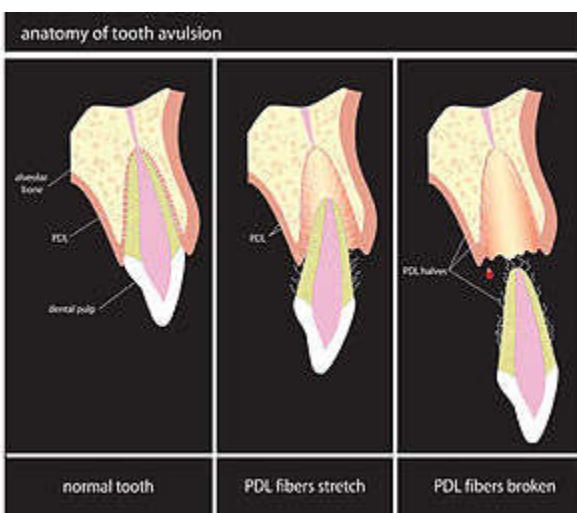
Various treatment modalities that can be used for managing fractured tooth are : Pulp capping (placing a dressing onto pulp exposure), partial pulpotomy, full pulpotomy (in which the entire coronal pulp to the level of root canal is removed) and even pulpectomy. The treatment has a higher success rate provided the pulp is healthy, a tight microbial seal and if proper pulp dressing with calcium hydroxide is provided. Treatment options comprising of pulp capping, partial pulpotomy, or pulpectomy are preferred, if the pulp is vital. If the pulp becomes necrotic, a routine root canal treatment is the preferred treatment of choice (21).

- In cases of tooth with open apices, they were provided with definitive pulp management. Efforts should be made to preserve vital pulp tissue wherever possible if no evidence of pulpal pathology is there.
- The use of dental adhesive systems which are capable of re-attaching a fractured fragment are utilized. Reattachment of fragments is a conservative procedure that can preserve aesthetics, restore masticatory function (23).
- It is advisable to splint after repositioning a tooth to maintain its original position and prevent displacement and further injury to the periodontal ligament during the healing stage. Long-term rigid splinting, between 2 and 6 weeks, is believed to increase

the severity and frequency of the occurrence of external root resorption (21).

- Alternative treatment modalities of crown–root fractures are fragment reattachment, composite resin restoration and full crown coverage (24).

AVULSION: “Avulsion” is the term used to describe a situation in which a tooth has been removed from its socket as a result of severe trauma. Tooth avulsion is considered as one of the most detrimental traumatic dental injuries among children, that corresponds to the complete displacement of the tooth out of the alveolar bone socket (25,26). It represents about 16% of all traumatic dentoalveolar injuries and has highest incidence in the 7-11-year-old age group (27). It is a condition due to which the patient has to rush to the dental office. Since the periodontal ligament (PDL) fibers, the neurovascular bundle at the root apex, the cement layer of the tooth, alveolar bone, and the gingiva are all damaged, it makes the treatment of an avulsed tooth difficult (28). Immediate and appropriate management by replantation is important for long term prognosis but if handled incorrectly replantation of avulsed tooth will lead to tooth resorption or ankyloses and result in poor prognosis.



<https://upload.wikimedia.org/wikipedia/commons/thumb/7/76/Avulsion.jpg/300px-Avulsion.jpg>

DIAGNOSIS: Clinical and radiographic findings reveal if the tooth is absent from the alveolar socket, or if the tooth has been replanted. If the tooth was not found at the scene of the injury, radiographs should be obtained to exclude the possibility of dental intrusion (29).

STORAGE MEDIA: Before the actual treatment begins, the avulsed tooth can be placed in the storage media like. Various storage media are : HBSS, cow milk, contact lens solution, ORS, soy milk, propolis, coconut water, egg white, caseinphosphopeptide, via span, Gatorade, dentosafe.

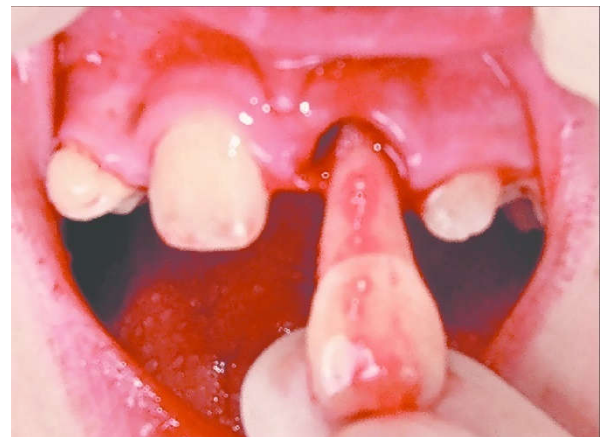
- A balanced salt and saliva may also be used.
- Tooth is placed in the medium within 15-20 min, periodontal ligament cells can remain vital for 2 hours in saliva obtained from the patient, and 6 h in fresh milk. Water is a harmful storage medium as it enters the cells down an osmotic gradient and causes lysis and cell death (30).
- A pH-balanced, cell reconstituting medium such as Hanks Balanced Salt Solution (HBSS) can replenish the cells if the dry storage time is below 30 minutes. This allows storage of an avulsed tooth for up to 24 h if replantation has to be delayed because of other more severe injuries.

MANAGEMENT OF AVULSION: Some of the things to keep in mind while performing the treatment of an avulsed tooth are:

- Earlier, endodontic treatment used to be performed extra orally before the process of replantation. Nowadays, it is recommended

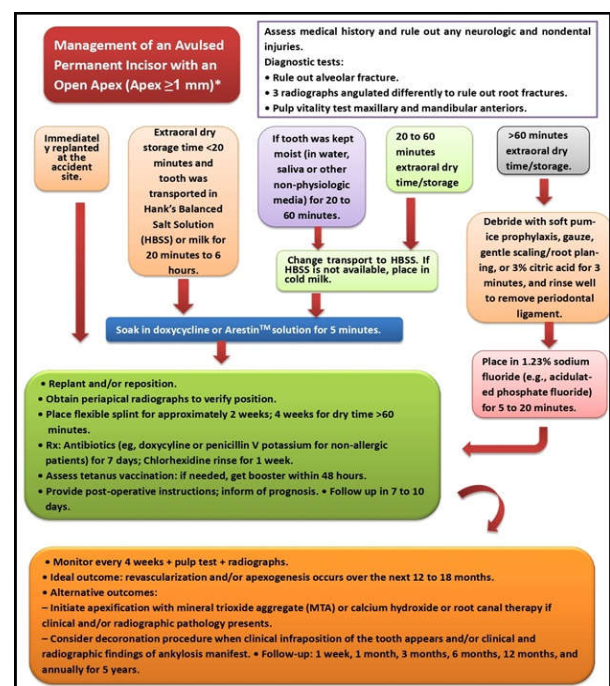
that endodontic treatment should be performed intraorally to minimize the extraoral time or to reduce risk factors (26).

- Firstly, the debris on the tooth is removed by washing the tooth with cold water for less than 10 seconds and avoid using water as a storage medium.
- Prescribing systemic antibiotics after replantation of a tooth, is considered a good option as infection will reduce the chance of reattachment of the periodontal ligament and revascularization of the pulp, and increase root resorption (30).
- Immediate replantation has the ability to maintain the alveolar form, function, and PDL cell viability. Treatment with 2% APF provides resistance to inflammatory and replacement root resorption because fluoride acts directly on dentin, cementum, and enamel converting the hydroxyapatite into fluorapatites (31).
- The replanted teeth should be root canal treated to remove the necrosed pulp tissues. Calcium hydroxide helps in reducing inflammatory resorption, counteracting the endotoxins, and alters the dentin making it less susceptible to dentinoclastic action.



<https://www.researchgate.net/publication/283184047/figure/fig3/AS:411429439066114@1475103830459/Replantation-of-avulsed-tooth-21.png>

- Semi-rigid splint is used for stability of replanted tooth and thereby aiding in healing and avoiding ankylosis, ideally splinting should be for two weeks depending on the root maturation and length.
- Reimplanted avulsed teeth must be under continuous follow-ups at time intervals of two weeks, four weeks, six months, one year, and then every year later for at least five year.



Source: https://www.guident.net/uploads/article-images/image_1592748515985.jpg

PAIN: Orofacial pain and swelling are one of the most common reasons for visiting a dentist(32). Endodontic pain is the result of an inflammatory process, which is mostly related to microbial irritation but which can also be associated to mechanical or chemical factors.

Chemical mediators such as arachidonic acid metabolites, cytokines, chemokines, kinins, serotonin, and neuropeptides are produced during the inflammatory process. These inflammatory mediators activate or sensitive nociceptors terminating in the pulp, the periodontal ligament or periradicular bone, induce sprouting of nociceptors (leading to increased receptivity to stimuli), and evoke edema and increased tissue pressure by increasing vascular permeability in these tissues (33).

DIAGNOSIS: A thorough review of the medical and dental histories, including a detailed description of the chief complaint, is an essential initial step in the diagnostic process. Radiographic examination must include more than a single periapical image.

A slight change of a radiograph's angulation may enable a clinician to visualize unexpected caries, periodontal defects, or additional roots that were not apparent on a single radiograph. CBCT provides 3D radiographic images, using a full field of view or limited field of view, of an area from different perspectives. For example, a clinician pondering whether or not a lesion extends through the labial and palatal cortical plates of bone can now determine that answer definitively using CBCT imaging (34).

MANAGEMENT: Endodontic pain management includes all aspects of treatment:

- a. Preoperative pain control which includes correct diagnosis and anxiety reduction: Pre-treatment with either ibuprofen (800mg) or flurbiprofen (100mg) have been proved to be effective for management of post-treatment pain and by blocking the activation of unmyelinated C nociceptors, which helps in providing anaesthetic as well as analgesic effect by decreasing the potential for central sensitization.
- b. Intraoperative pain control is done with effective local anaesthetic agents and operative techniques, The long-acting local anaesthetics can provide a duration of analgesia up to 8–10 h following block injections, and may reduce pain report even 48 h later.
- c. Postoperative pain management can involve a variety of pharmacologic agents (35). Both pharmacological and nonpharmacological approaches can be followed. Nonpharmacological approach such as acupuncture (which is the stimulation of particular points on the skin with needles) has been suggested to reduce anxiety during treatment to alleviate postoperative pain after tooth extraction. It helps produce the feeling of a sensation of numbness and fullness. The effects of acupuncture include increased pain threshold, sedation, homeostatic or regulatory effect, immune enhancement, psychological effect, and motor recovery (36). Pharmacological approach includes use of pharmacological drugs like nonnarcotic analgesics and opioids like, ibuprofen, paracetamol, and aspirin. Sutherland and Matthews in an experiment showed that pre-emptive NSAIDs in conjunction with pulpectomy, provided a significant benefit in eliminating endodontic pain. Pain reduction can be achieved using an intraosseous injection of slow-releasing methylprednisolone in teeth with irreversible pulpitis. Endodontic pain can simply be managed by eliminating the source as completely as possible along with judicious use of local anaesthetics, nonopioid and opioid analgesics (37). Treatment procedures like pulpotomy and pulpectomy are effective treatments for reducing postoperative pain regardless of whether any analgesics are prescribed. The effective debridement of the infected root canal system, along with incision for drainage and occlusal reduction, provides predictable pain reduction strategies in endodontic emergency patients.

CONCLUSION

Patients must report to the dentists at the earliest and get their treatment done in order to avoid any future complication. An endodontic emergency is dreadful for both the patients and the dentist so even the dentists must be fully prepared for any situation of this kind.

REFERENCES

1. Nguyen, V. and Palmer, G., 2009. A review of the diagnosis and management of the cracked tooth. *Dental Update*, 36(6), pp.338-349.
2. TÜRP, J.C. and Gobetti, J.P., 1996. The cracked tooth syndrome: an elusive diagnosis. *The Journal of the American Dental Association*, 127(10), pp.1502-1507.
3. BDS, C.K.H., 1998. Cracked tooth syndrome—incidence, clinical findings and treatment. *Australian dental journal*, 43(4), pp.217-222.
4. Kahler, W., 2008. The cracked tooth conundrum: terminology, classification, diagnosis, and management. *American journal of dentistry*, 21(5), p.275.
5. Hasan, S., Singh, K. and Salati, N., 2015. Cracked tooth syndrome: overview of literature. *International Journal of Applied and Basic Medical Research*, 5(3), p.164.
6. Gill, T., Pollard, A.J., Baker, J. and Tredwin, C., 2021. Cracked Tooth Syndrome: Assessment, Prognosis and Predictable Management Strategies.
7. Lynch, C.D. and McConnell, R.J., 2002. The cracked tooth syndrome. *Journal-Canadian Dental Association*, 68(8), pp.470-475.
8. Hasan, S., Singh, K. and Salati, N., 2015. Cracked tooth syndrome: overview of literature. *International Journal of Applied and Basic Medical Research*, 5(3), p.164.
9. Fawzy, M., Alhadainy, H.A., Salah-Uddin, M. and Abdulrab, S., 2020. Management of cracked tooth using simvastatin as intracanal medicament. *Clinical Case Reports*, 8(12), pp.3049-3052.
10. Banerji, S., Mehta, S.B. and Millar, B.J., 2017. The management of cracked tooth syndrome in dental practice. *British dental journal*, 222(9), pp.659-666.
11. Sipavičiūtė, E. and Manelienė, R., 2014. Pain and flare-up after endodontic treatment procedures. *Stomatologija*, 16(1), pp.25-30.
12. Jayakodi, H., Kailasam, S., Kumaravadevel, K., Thangavelu, B. and Mathew, S., 2012. Clinical and pharmacological management of endodontic flare-up. *Journal of pharmacy & bioallied sciences*, 4(Suppl 2), p.S294.
13. Khatri, S., Parvez, S., Agarwal, M.K., Goyal, D., Binawra, K.K., Jain, A. and Deepak, G., Comparative Evaluation of Effect of Resinbased, Calcium Hydroxide-Based and Bioceramic-Based Root Canal Sealers on Postoperative Pain. *List of Articles Pages No.*
14. Rosenberg, P.A., 2002. Clinical strategies for managing endodontic pain. *Endodontic Topics*, 3(1), pp.78-92.
15. Singh, H., 2016. Endodontic Flare ups: The Bacteriological Aspect. *of*, 2, p.2.
16. Sana, R., Khattak, Y., Alam, F. and Khan, M.Z., 2016. Factors Associated with Endodontic Flare-Ups. *Journal of Gandhara Medical and Dental Science*, 2(2), pp.14-20.
17. Di Spirito, F., Scelza, G., Fornara, R., Giordano, F., Rosa, D. and Amato, A., 2022. April. Post-operative endodontic pain management: An overview of systematic reviews on post-operatively administered oral medications and integrated evidence-based clinical recommendations. In *Healthcare* (Vol. 10, No. 5, p. 760). MDPI.
18. Bassam, S., El-Ahmar, R., Salloum, S. and Ayoub, S., 2021. Endodontic postoperative flare-up: An update. *The Saudi Dental Journal*, 33(7), pp.386-394.
19. Olsburgh, S., Jacoby, T. and Krejci, I., 2002. Crown fractures in the permanent dentition: pulp and restorative considerations. *Dental Traumatology*, 18(3), pp.103-115.

20. Özer, S.Y., Uysal, İ. and Bahşi, E., 2011. Surgical extrusion of a complete crown fractured tooth: a case report. *International Dental Research*, 1(2), pp.70-74.
21. Łagocka, R., Marek, E., Trusewicz, M., Bendyk-Szeffer, M. and Mazurek-Mochol, M., 2021. An oblique crown-root fracture of the mesial root of molar with vital pulp—a case study. *Pomeranian Journal of Life Sciences*, 67(4).
22. Martos, J., Pinto, K.V., Miguelis, T.M. and Xavier, C.B., 2017. Management of an uncomplicated crown fracture by reattaching the fractured fragment—Case report. *Dental Traumatology*, 33(6), pp.485-489.
23. Turgut, M.D., Gönül, N. and Altay, N., 2004. Multiple complicated crown–root fracture of a permanent incisor. *Dental Traumatology*, 20(5), pp.288-292.
24. Daneshvar, S.H. and Khaef, M., 2022. The Effect of Using an Educational Poster on Mothers' Knowledge of Emergency Management of Dental Avulsion. *Dentistry 3000*, 10(1).
25. El Kharroubi, S., Drouri, S., Doumari, B., Dhoum, S. and El Merini, H., 2022. Management of 3 Avulsed Permanent Teeth: Case Report of a 3-Year Follow-up. *Case Reports in Dentistry*, 2022.
26. Bahammam, L.A., 2018. Knowledge and attitude of emergency physician about the emergency management of tooth avulsion. *BMC oral health*, 18(1), pp.1-9.
27. Karayilmaz, H., Kirzioglu, Z. and Gungor, O.E., 2013. Aetiology, treatment patterns and long-term outcomes of tooth avulsion in children and adolescents. *Pakistan journal of medical sciences*, 29(2), p.464.
28. Sharma, A., Mandlik, J. and Varghese, R., 2016. An overview of etiology of endodontic flare-ups. *Indian Journal of Conservative and Endodontics*, 1(3), pp.76-80.
29. Dewhurst, S.N., Mason, C. and Roberts, G.J., 1998. Emergency treatment of orodental injuries: a review. *British Journal of Oral and Maxillofacial Surgery*, 36(3), pp.165-175.
30. Parthasarathy, R., Srinivasan, S., Vikram, C., Thanikachalam, Y. and Ramachandran, A., 2022. An Interdisciplinary Management of Avulsed Maxillary Incisors: A Case Report. *Cureus*, 14(4).
31. Tampi, M.P., Pilcher, L., Urquhart, O., Kennedy, E., O'Brien, K.K., Lockhart, P.B., Abt, E., Aminoshariae, A., Durkin, M.J., Fouad, A.F. and Gopal, P., 2019. Antibiotics for the urgent management of symptomatic irreversible pulpitis, symptomatic apical periodontitis, and localized acute apical abscess: systematic review and meta-analysis—a report of the American Dental Association. *The Journal of the American Dental Association*, 150(12), pp.e179-e216.
32. Fouad, A.F., 2002. Are antibiotics effective for endodontic pain? An evidence-based review. *Endodontic Topics*, 3(1), pp.52-66.
33. Rosenberg, P.A., 2014. Endodontic pain. *Endodontic topics*, 30(1), pp.75-98.
34. Keiser, K. and Hargreaves, K.M., 2002. Building effective strategies for the management of endodontic pain. *Endodontic topics*, 3(1), pp.93-105.
35. Murugesan, H., Venkatappan, S., Renganathan, S.K., Narasimhan, S. and Sekar, M., 2017. Comparison of acupuncture with ibuprofen for pain management in patients with symptomatic irreversible pulpitis: A randomized double-blind clinical trial. *Journal of acupuncture and meridian studies*, 10(6), pp.396-401.
36. Mickel, A.K., Wright, A.P., Chogle, S., Jones, J.J., Kantorovich, I. and Curd, F., 2006. An analysis of current analgesic preferences for endodontic pain management. *Journal of endodontics*, 32(12), pp.1146-1154.
