



ISSN: 0975-833X

Available online at <http://www.journalcra.com>

International Journal of Current Research
Vol. 15, Issue, 01, pp.23354-23355, January, 2023
DOI: <https://doi.org/10.24941/ijcr.44635.01.2023>

INTERNATIONAL JOURNAL
OF CURRENT RESEARCH

RESEARCH ARTICLE

A GHOST KERATIN PEARL – AN INTERESTING FINDING!

¹Dr. Noopur Kulkarni, ²Dr. Roshini Vinod, ³Dr. Atul Deshpande, ⁴Dr. Sujit Londhe and ⁵Dr. Shailesh Gawande

^{1,2,5}MDS Oral Pathology PhD Pursuing, Ass Prof, PDUDC Solapur, India

³MDS Oral Pathology, PDUDC Solapur, India

⁴Consultant Dentist, Private practitioner, Pune, India

ARTICLE INFO

Article History:

Received 16th October, 2022
Received in revised form
10th November, 2022
Accepted 19th December, 2022
Published online 30th January, 2023

Key words:

Keratin pearl, Keratinisation,
Squamous Cell Carcinoma.

*Corresponding Author:

Dr. Noopur Kulkarni

Copyright©2023, Noopur Kulkarni et al. This is an open access article distributed under the Creative Commons Attribution License, which permits unrestricted use, distribution, and reproduction in any medium, provided the original work is properly cited.

Citation: Dr. Noopur Kulkarni, Dr. Roshini Vinod, Dr. Atul Deshpande, Dr. Sujit Londhe and Dr. Shailesh Gawande. 2023. "A ghost keratin pearl – An interesting finding!". International Journal of Current Research, 15, (01), 23354-23355.

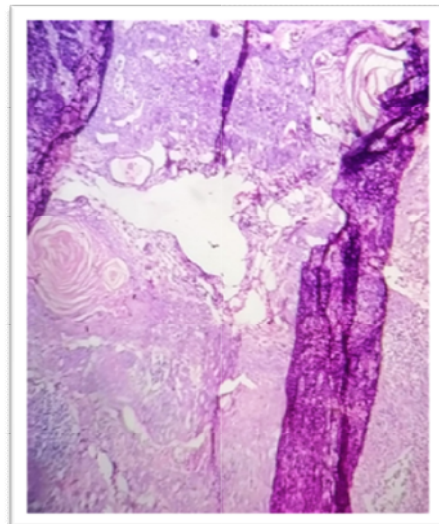
ABSTRACT

Oral squamous cell carcinoma is the most common malignant epithelial neoplasm hitting the oral cavity. A variety of genomic factors are responsible for this. Early diagnosis is the key to deal with this deadly disease. This dental image is an interesting finding of presence of a ghost keratin pearl in the H & E section of OSCC

INTRODUCTION

Keratins are diverse proteins. Subsequently it was realized that it is actually a mixture of keratins, keratin filament associated protein & other enzyme proteins. The process of maturation of keratinocytes follows keratinisation. A benign keratin pearl is surrounded by dyskeratosis. As the ultimate fate of a squamous cell is formation of keratin, the phenomenon of these cells laying down keratin in a concentric manner appear as a keratin pearl, that symbolize malignancy. A well differentiated SCC has a pale glossy cytoplasm with more squamous eddies or keratin pearls. A ghost cell is an enlarged eosinophilic epithelial cell with eosinophilic cytoplasm, but without nucleus. Pathological ghost cell formation could be a result of aberrant keratinization or coagulative necrosis. The given H & E stained field shows a histological section of a well differentiated oral squamous cell carcinoma which has all the classic features of an oral squamous cell carcinoma which is an indicative of a malignancy. The breach in the integrity of the intact epithelium is evident, along with all the dysplastic features. In the connective tissue is the presence of a mature & a very large sized keratin pearl which is huge in size & hence

the name ghost keratin pearl. It is centrally placed in the connective tissue. Adjacent to it are other keratin pearls & they are also large in size. The overall features are suggestive of a well differentiated oral squamous cell carcinoma



This is a low power view of the Histopathological section of an Oral squamous cell carcinoma . The central portion depicts a giant keratin pearl, which is surrounded by a dysplastic stroma.

2)Histological variants of SCC of skin .Aug 2001

3)Malignant epithelial tumors of skin . Pathobiology of human disease 2014

4)Ghost cells –Wikipedia

REFERENCES

1)Pathophysiology of keratinization . Priya Nimish *et al*
JOMFP 2018 Jan-Apr 2018
