



ISSN: 0975-833X

Available online at <http://www.journalcra.com>

*International Journal of Current Research*  
Vol. 15, Issue, 05, pp.24766-24768, May, 2023  
DOI: <https://doi.org/10.24941/ijcr.45408.05.2023>

INTERNATIONAL JOURNAL  
OF CURRENT RESEARCH

## RESEARCH ARTICLE

# TUBERCULOUS OTITIS MEDIA WITH AURAL POLYP – AN UNUSUAL PRESENTATION OF EXTRAPULMONARY TUBERCULOSIS

<sup>1</sup>Dr. Priya Badkar, <sup>2</sup>Dr. Garima Sinha, <sup>3,\*</sup>Dr. Avinash Kumar, <sup>4</sup>Dr. Ramesh Kumar Yalla and <sup>5</sup>Anubhav Chauhan

<sup>1</sup>Consultant, Department of ENT, Sai hospital Palacole, West Godavari, Andhra Pradesh; <sup>2</sup> Assistant, Professor, Dept. of Anaesthesia and Critical Care, Santosh Medical College and Hospital Ghaziabad, U.P.; <sup>3</sup> Assistant, Professor, Dept. of E.N.T., Noida International Institute of Medical Sciences (NIIMS), NIU, Greater Noida, U.P. <sup>4</sup>Dept of Obstetrics and Gynaecology, Dr Aravinds IVF Fertility Centre, Tiruppur, Tamil Nadu; <sup>5</sup>Third Year, year Medical Student, Noida International Institute of Medical Sciences (NIIMS), NIU, Greater Noida, U.P

### ARTICLE INFO

#### Article History:

Received 05<sup>th</sup> February, 2023  
Received in revised form  
14<sup>th</sup> March, 2023  
Accepted 29<sup>th</sup> April, 2023  
Published online 30<sup>th</sup> May, 2023

#### Key words:

Tuberculous Otitis Media,  
Aural Polyp, Painless Ear Discharge.

#### \*Corresponding Author:

Dr. Avinash Kumar

Copyright©2023, Priya Badkar et al. This is an open access article distributed under the Creative Commons Attribution License, which permits unrestricted use, distribution, and reproduction in any medium, provided the original work is properly cited.

Citation: Dr. Priya Badkar, Dr. Garima Sinha, Dr. Avinash Kumar, Dr. Ramesh Kumar Yalla and Anubhav Chauhan. 2023. "Tuberculous otitis media with aural polyp – an unusual presentation of extrapulmonary tuberculosis". *International Journal of Current Research*, 15, (05), 24766-24768.

### ABSTRACT

Tubercular otitis media with aural polyp is a rare entity, a rare manifestation of extra pulmonary tuberculosis. Also it is diagnosed late because its signs and symptoms are no different from the more common non tubercular otitis media conditions. We present a 14 year old female who came with complaints of ear discharge and hearing loss in the left ear since 6 months. She was initially managed conservatively in the lines of management of chronic suppurative otitis media. Then she was posted for mastoidectomy and only when the discharge, secretions and aural polyp was sent for histopathological analysis, was the diagnosis of Tuberculous otitis media made.

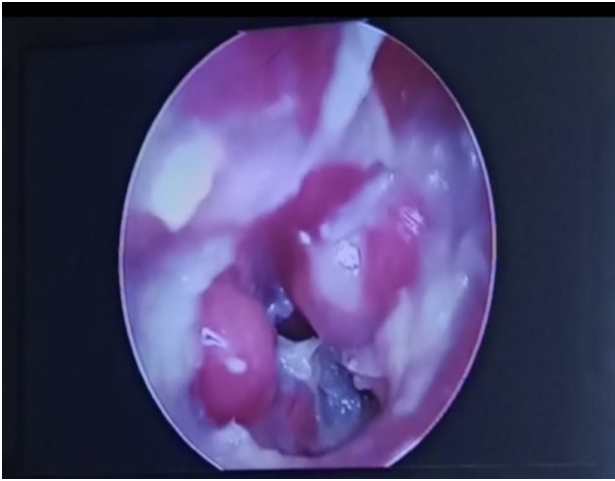
## INTRODUCTION

Tuberculous otitis media is underdiagnosed because of its rarity and similar signs and symptoms of other middle ear infectious conditions in particular, chronic suppurative otitis media. Incidence of tuberculous otitis media have been reported as 0.04 %<sup>1</sup>. The classical symptoms of painless otorrhoea, multiple perforations of tympanic membrane and facial nerve palsy are mostly not seen<sup>2</sup>. Since patients presenting with ear discharge are mostly managed with topical ear drops and systemic antibiotics and tests of TB are not done routinely, TB otitis media are mostly diagnosed postoperatively. We are reporting a case of TB otitis media which was also diagnosed postoperatively. TB otitis media should always be kept in mind when dealing with cases of ear discharge refractory to antibiotics.

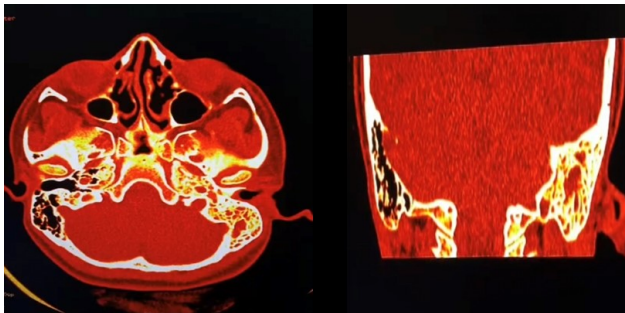
Early diagnosis of Tb otitis media will avoid complications like permanent hearing loss and facial nerve palsy<sup>3</sup>.

## CASE REPORT

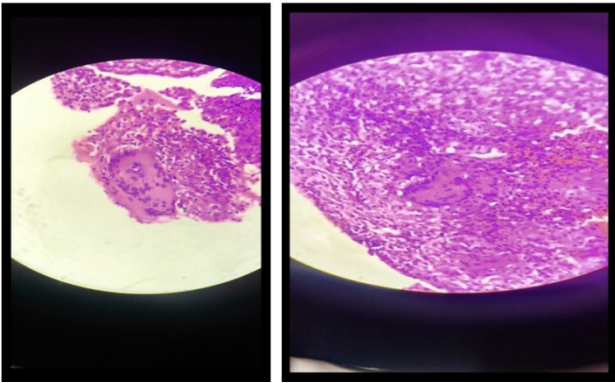
A 14 Year old female student presented to the opd with symptoms of ear discharge and hearing loss in left ear since 6 months. The ear discharge in left ear was sudden in onset, gradually progressive, non foul smelling, mucopurulent and profuse. It was not blood tinged and not associated with pain. The hearing loss was present only in left ear, insidious in onset and gradually progressive. It was not associated with tinnitus and vertigo. However patient complained of aural fullness and occasional otalgia. There was no history of fever, chronic cough, weight loss, night sweating or any contact with individuals having infectious or contagious disease.



**Figure 1. Perforated tympanic membrane with aural polyp**



**Figure 2. Left sided otomastoiditis showing opacification of middle ear cleft**



**Figure 3, 4. Epithelioid granulomas with langhans multinucleate giant cells , caseous necrosis**

There was no history of any comorbidities or any history of surgery in the past. On examination of left ear no Tragal tenderness was elicited. External auditory canal was full of discharge. On examination under microscope and suction clearance, two aural polyps were seen in the external auditory canal. Both were painless swellings, can be probed all around and it bled on touch. Congested tympanic membrane with a subtotal perforation was seen and middle ear was full of slough and granulation tissue. Pure tone audiometry revealed moderate conductive hearing loss. HRCT scan was done which showed features of left otomastoiditis. There was opacification of left mastoid air cells, mastoid antrum, entire middle ear cavity extending to external auditory canal. No bony erosions were present and ossicular chain seemed intact. Patient was initially managed with topical ear drops and oral antibiotics for 3 weeks, but there was no

improvement. Hence patient was posted for left modified radical mastoidectomy. Secretions, granulations, debris and aural polyp removed from the middle ear cleft were sent for histopathology. On Histopathology chronic inflammatory cells, a number of epithelioid cells, Langhans giant cells were identified. Areas of caseous necrosis surrounded by histiocyte could be seen. Patient was advised Mantoux test which showed 18 mm induration. A diagnosis of TB otitis media was hence made. Hence patient was started on 6 month course of 4 drug ATT comprising of Isoniazid, Pyrazinamide, Rifampin and Ethambutol and was monitored regularly on follow ups. Patient now is symptom free and doing well.

## DISCUSSION

Tuberculous otitis media is a rare condition and in endemic areas, it is more commonly seen in children than adults. It accounts for 84% of cases in less than 15 years<sup>5</sup>. Areas where TB is endemic, Tb otitis media should always be a differential when facing patients with ear discharge. Aspiration of mucus through Eustachian tube and blood borne dissemination from other TB foci are two theories implicated in the pathogenesis of TB otitis media<sup>6</sup>. The classical triad of painless otorrhoea, multiple perforations of tympanic membrane and facial nerve palsy is missing in most cases probably due to patients immunity. Patients normally present with ear discharge, which can be purulent because of secondary infection. Occasional otalgia, aural fullness and hearing loss are other complaints. Hearing loss is seen in 90 % of cases which can be conductive, sensorineural or mixed. Since the diagnosis is delayed in tuberculous otitis media because of its rarity, patients can at times present with complications like facial nerve palsy.

Examination finding usually shows granulation tissue on tympanic membrane, thickened and perforated tympanic membrane. Perforations can be solitary or multiple and occurs in areas of granulations. Pale white granulation tissue in middle ear, slough and necrosis of ossicles can also be present. Granulations can be present in entire middle ear cleft involving the aditus, antrum and middle ear. Differential diagnosis of patients coming with chronic otorrhoea includes cholesteatoma, tuberculosis, syphilis, sarcoidosis, histoplasmosis and wegeners granulomatosis<sup>7</sup>. High resolution C T scan of the temporal bone is commonly used in the evaluation of TB otitis media. However differentiating the bone and soft tissue changes as seen in TB otitis media and other causes of otitis media is never that easy. Ossicular destruction, sclerosis of the mastoid cortex and opacification of the middle ear and mastoid are common radiographic findings in both. A more common simple and inexpensive diagnostic procedure for suspected TB otitis media is Tuberculin skin test or Mantoux test. A positive induration of 15 mm is highly suggestive of TB infection. Chest radiography, CT thorax, microbiological diagnosis by culture, microscopy or PCR are other modalities of diagnosing Tubercular infection but you need a high level of suspicion for that. Histopathological examination of specimen is advocated as confirmatory test for specimen obtained from extrapulmonary sites<sup>8</sup>. The role of surgical treatment in TB otitis media is controversial. Mastoidectomy advocated for the purpose of eradicating the disease cannot completely cause resolution of the granuloma and otorrhoea, hence empirical regimen of four ATT for 6 months, in conjunction is essential.

ATT improves prognosis in most of the patients<sup>7</sup>. For complete cure drug therapy should be taken for atleast 6 months

## CONCLUSION

Tuberculosis should be suspected in all cases of chronic otitis media which is not responsive to conventional treatment of topical ear drops and oral antibiotics. Histopathological examination and AFB staining of tissue excised during mastoidectomy forms the basis of diagnosis in most cases. Hence any case of otitis media that comes with recurrence following surgical intervention should be properly investigated for tuberculosis especially in endemic areas.

## REFERENCES

1. Windle-Taylor PC, Bailey CM. Tuberculous otitis media: A series of 22 patients. *Laryngoscope*, 1980;90:1039-44.
2. Skolnik PR, Nadol JB, Jr, Baker AS. Tuberculosis of the middle ear: Review of the literature with an instructive case report. *Rev Infect Dis* 1986;8:403-10.
3. Jeanes AL, Friedmann I. Tuberculosis of the middle ear. *Tubercle* 1960;41 :109-16.
4. Palva T, Palva A, Karja J. Tuberculous otitis media. *J Laryngol Otol* 1973;87 :253-61.
5. Plester D, Pusalkar A, Steinbach E. Middle ear tuberculosis. *J Laryngol Otol* 1980;94:1415-21.
6. Singh B. Role of surgery in tuberculous mastoiditis. *J Laryngol Otol* 1991;105:907-15.
7. Wallner LJ. 1953. Tuberculous otitis media, *Laryngoscope* 63: 1058-77.
8. Cart M' HW. 1925. Tuberculous disease of the middle ear. *J Laryngol Otol.*, 40:456-66.

\*\*\*\*\*