



RESEARCH ARTICLE

ENDOMETRIOSIS: A PAINFUL AND A DEEPLY INFILTRATIVE DISEASE INVADING THE URINARY BLADDER, UTERUS AND THE ABDOMINAL WALL: A CASE REPORT

¹Ojas Vijayanand Potdar and ²Vidya Patil

¹Assistant Professor in Urology, Grant Medical College and J.J. Group of Hospitals, Mumbai; ²Consultant Obstetrics and Gynecologist, Laparoscopic Surgeon and Infertility Specialist, Arya Women's Care Hospital, Kandivali West, Mumbai

ARTICLE INFO

Article History:

Received 14th September, 2024
Received in revised form
27th October, 2024
Accepted 20th November, 2024
Published online 30th December, 2024

Key Words:

Endometriosis,
Bladder,
Abdominal Wall.

*Corresponding author:

Ojas Vijayanand Potdar

ABSTRACT

Introduction: Urological endometriosis is rare and accounts for approximately 1% of women with endometriosis. The pathophysiology of bladder endometriosis may be divided into two different causes, namely primary and secondary. The primary form occurs spontaneously and manifests in a form of a generalized pelvic disease whereas the secondary form is thought to be iatrogenic and typically occurs after pelvic surgery such as Cesarean section or hysterectomy. **Case presentation:** A middle-aged woman with complaints of cyclical episodes of lower abdominal pain associated with menstrual periods over 8 months. The complaints started after one month post lower segment caesarean section. The patient was further evaluated using MRI of the abdomen and pelvis which revealed endometriotic scar extending from the abdominal wall as a linear tract and then extending towards the uterus and also involving the dome of the bladder. The patient then underwent diagnostic Hysteroscopy with Dilatation and curettage along with Diagnostic Cystoscopy with transurethral resection biopsy of the mass. Histopathological examination revealed evidence of endometriosis. Patient underwent Exploratory Laparotomy with Hysterectomy with Bilateral Salpingectomy with partial cystectomy with abdominal wall resection to remove the entire endometriotic tissue along with Abdominal wall reconstruction using Prolene mesh for abdominal wall closure. Postoperative course involved a wound gape without infection of the underlying mesh which was managed with regular dressing followed by secondary suturing of the wound. Patient has been on regular follow up for the last one year with no recurrence of complaints. **Conclusion:** Bladder endometriosis can often mimic pelvic malignancy resulting in radical surgeries. They can be a rare complication of a previous Cesarean section. More data is needed to determine the relationship of Cesarean scar niche in bladder endometriosis.

Copyright©2024, Ojas Vijayanand Potdar and Vidya Patil. This is an open access article distributed under the Creative Commons Attribution License, which permits unrestricted use, distribution, and reproduction in any medium, provided the original work is properly cited.

Citation: Ojas Vijayanand Potdar and Vidya Patil. 2024. "Endometriosis: A painful and a deeply infiltrative disease invading the urinary bladder, Uterus and the Abdominal wall: A case report". *International Journal of Current Research*, 16, (12), 30896-30897.

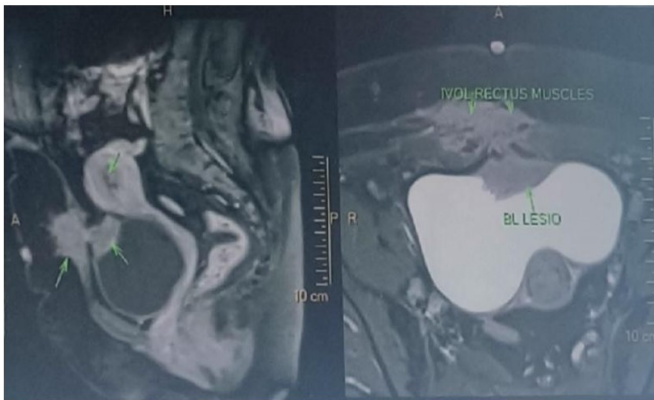
INTRODUCTION

Urological endometriosis is rare and accounts for approximately 1% of women with endometriosis. The pathophysiology of bladder endometriosis may be divided into two different causes, namely primary and secondary. The primary form occurs spontaneously and manifests in a form of a generalized pelvic disease whereas the secondary form is thought to be iatrogenic and typically occurs after pelvic surgery such as Cesarean section or hysterectomy.

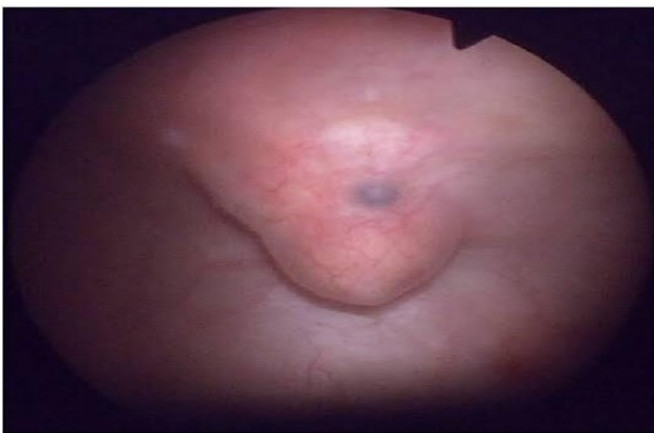Case presentation: A middle-aged woman with complaints of cyclical episodes of lower abdominal pain associated with menstrual periods over 8 months. The complaints started after one month post lower segment caesarean section. The patient was further evaluated using MRI of the abdomen and pelvis which revealed endometriotic scar extending from the abdominal wall as a linear tract and then extending towards the uterus and also involving the dome of the bladder (Picture -1).

Picture 1 MRI image showing the linear tract of endometriosis extending from the abdominal wall to involve the dome of the urinary bladder and then upto the uterus: The patient then underwent diagnostic Hysteroscopy with Dilatation and curettage along with Diagnostic Cystoscopy with transurethral resection biopsy of the mass (Picture -2).

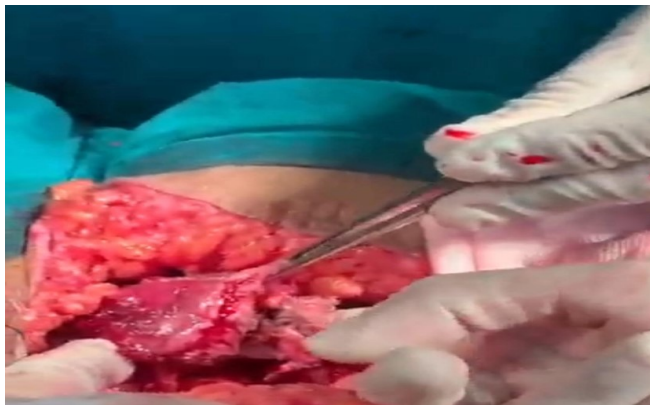
Histopathological examination revealed evidence of endometriosis. Patient underwent Exploratory Laparotomy with Hysterectomy with Bilateral Salpingectomy with partial cystectomy with abdominal wall resection to remove the entire endometriotic tissue along with Abdominal wall reconstruction using Prolene mesh for abdominal wall closure. Postoperative course involved a wound gape without infection of the underlying mesh which was managed with regular dressing followed by secondary suturing of the wound.



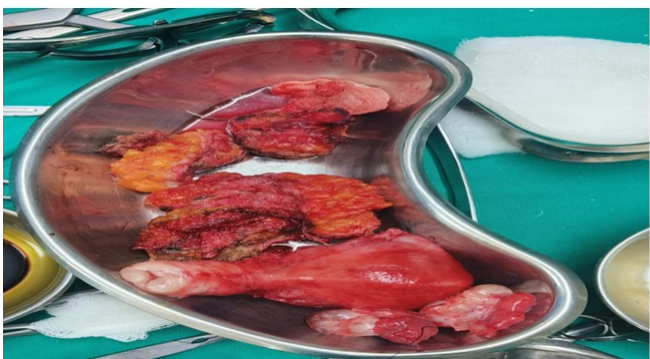Picture 1. MRI image showing the linear tract of endometriosis extending from the abdominal wall to involve the dome of the urinary bladder and then upto the uterus



Picture 2. Cystoscopy image showing the endometrial mass extension to the dome of the urinary bladder



Picture 3. Intraoperative clinical picture showing the involvement of the dome of the urinary bladder wall with endometriosis



Picture-4- Clinical picture of the resected specimen

Patient has been on regular follow up for the last one year with no recurrence of complaints.

DISCUSSION

Endometriosis is endometrial tissue located outside of the uterus.¹ Although many women are asymptomatic, it is estimated to affect up to 15% of premenopausal women.² Presenting signs and symptoms include dysmenorrhea, back pain, pelvic pain, lower abdominal pain, dyspareunia, irregular bleeding, and infertility. The severity of symptoms and extent of the disease have no direct correlation.³ Endometriosis implants can occur in a variety of locations, the most common being the ovaries, uterine ligaments, within the rectovaginal septum, cul-de-sac, and pelvic peritoneum.² Involvement of the urinary bladder is extremely rare but has been reported in roughly 1% of patients with endometriosis.³ Bladder involvement has been associated with certain urinary tract symptoms, including dysuria, frequency, urinary urgency, cyclic hematuria, and micturition syndrome (temporary loss of consciousness during urination) that is typically cyclic in nature.² There are two general forms of endometriosis, diffuse and localized.³ In the diffuse form, the more prevalent form, small endometrial implants are scattered throughout the pelvic viscera and their ligamentous attachments.³ Because the endometrial implants are hormone driven, the patient experiences bleeding during the menstrual cycle, which causes local inflammation and adhesions.³ In our case we describe a middle aged female with history of lower segment caesarean section who developed endometriotic scar extending from the abdominal wall, involving the dome of the urinary bladder and extending upto the Uterus, with cyclical episodes of pain and successfully managed by thorough excision.

CONCLUSION

Bladder endometriosis can often mimic pelvic malignancy resulting in radical surgeries. They can be a rare complication of a previous Cesarean section. More data is needed to determine the relationship of Cesarean scar niche in bladder endometriosis.

REFERENCES

1. Hacker NF, Moore JG, Gambone JC. 2004. Essentials of Obstetrics and Gynecology. 4th ed. Philadelphia, Elsevier Saunders.
2. Perez MP, Bazan AA, Dorrego JM, et al. 2009. Urinary tract Endometriosis: clinical, diagnostic, and therapeutic aspects; J Urol., 73:47–51.
3. Rumack CW, Wilson SR, Charboneau JW, et al. 2005. Diagnostic Ultrasound. 3rd ed., vol. 1. St. Louis, MO, Elsevier Mosby