



## RESEARCH ARTICLE

### MANAGEMENT OF SKELETAL CLASS III MALOCCLUSION WITH FACE MASK THERAPY AND COMPREHENSIVE ORTHODONTIC TREATMENT

<sup>1</sup>Dr. Prakash Banerjee, <sup>2,\*</sup>Dr. Kasturi Mukherjee, <sup>3</sup>Dr. Poulomi Roy and <sup>4</sup>Dr. Shyamal Bar

<sup>1,2</sup>Associate Professor of Department of Orthodontics and Dentofacial Orthopaedics at Burdwan Dental College and Hospital; <sup>3</sup>Assistant Professor of Department of Orthodontics and Dentofacial Orthopaedics at Burdwan Dental College and Hospital; <sup>4</sup>Professor and HOD of Department of Orthodontics and Dentofacial Orthopaedics at Burdwan Dental College and Hospital

#### ARTICLE INFO

##### Article History:

Received 25<sup>th</sup> October, 2024  
Received in revised form  
20<sup>th</sup> November, 2024  
Accepted 24<sup>th</sup> January, 2025  
Published online 27<sup>th</sup> February, 2025

##### Key Words:

Class III Malocclusion, Facemask Therapy, Growth Modification, Maxillary Deficiency.

##### \*Corresponding author:

Dr. Kasturi Mukherjee

#### ABSTRACT

Orthopedic correction of skeletal Class III malocclusion in a growing individual is crucial as it can circumvent future surgical procedures. Further, as surgery is done only at a later stage, early treatment helps to avoid the ill effects produced by the facial disfigurement on the patient's social life. This case report describes the treatment of a child aged 12 years who had a skeletal Class III malocclusion. The treatment plan involved the use of a reverse pull headgear (facemask) and multibracket appliance therapy resulting in successful correction of the malocclusion. The treatment results were highly satisfactory resulting in improved facial esthetics, a skeletal Class I with a dental Class I molar and canine relationship, an ideal overjet and overbite. Thus, if it is done in properly selected cases, alleviates the need for surgical intervention in future. The patient is being monitored until the end of growth to ensure the stability of treatment results.

Copyright©2025, Prakash Banerjee. This is an open access article distributed under the Creative Commons Attribution License, which permits unrestricted use, distribution, and reproduction in any medium, provided the original work is properly cited.

Citation: Dr. Prakash Banerjee, Dr. Kasturi Mukherjee, Dr. Poulomi Roy and Dr. Shyamal Bar. 2025. "Status of Local Democracy through Panchayati Raj Institutions: A Case Study of Nalgram Enclave (Chitmahal) after Indo-Bangladesh Land Boundary Agreement (2015)". *International Journal of Current Research*, 17, (01), 31711-31714.

## INTRODUCTION

Etiologically Class III malocclusions are multifactorial which includes genetic and environmental factors. The presentation of Class III malocclusions are generally classified into two categories: Skeletal and dental. Various features of skeletal Class III malocclusion include either maxillary retrusion or mandibular prognathism or combination of both consummated with vertical and transverse problems apart from sagittal malformations. A developing skeletal Class III malocclusion is one of the most challenging problems confronting the practicing orthodontists. For these patients early orthopedic treatment can correct the existing or developing skeletal, dentoalveolar, and muscular imbalances and improve the oral environment and facial esthetics. Class III malocclusion may occur as a result of skeletal or dental discrepancies and is a source of esthetic and functional impairment to the individual.(1) The prevalence of Class III malocclusion has been found to be widely varied among the various ethnic groups.(2) Prevalence of Class III is greater in Asian population compared to Caucasians, ranging between 4% and 13% in Japanese, 7.8–15.2% in Iranians, and between 4% and 14% among Chinese.(3,4) The prevalence of this malocclusion in Indian population is reported to be about 3.4%.(5) Ellis and

McNamara concluded that the most common combination of variables in an adult Class III malocclusion were a retrusive maxilla, protrusive maxillary incisors, retrusive mandibular incisors, a protrusive mandible, and a long lower facial height. (6) Further, on an average, 60% of Class III malocclusions are characterized by maxillary deficiency.(6) Since Class III malocclusions are the most prevalent type which require orthognathic surgery, early treatment of this discrepancy is of paramount importance as it can minimize or even avoid surgeries at a later stage. (7) However, Class III skeletal malocclusion is notorious for relapsing after the early stage of treatment is completed. Patients with a significant mandibular prognathism require constant monitoring and may need further facemask therapy.(8) Hence, proper case selection, a prolonged duration of treatment, and long-term follow-up is necessary for orthopedic growth modification to be deemed successful. In the last two decades, a combination of rapid maxillary expansion (RME) along with a facemask to protract the maxilla has become a standard protocol in the early management of cases with maxillary deficiency.(9) This case report presents the use of the above procedure for the successful management of Class III malocclusion with maxillary deficiency in a 12-year-old patient.

**Diagnosis:** The patient was a 12-year-old girl retrognathic maxilla in early mixed dentition. The facial analysis reflected mesocephalic whose chief complaint was “upper front teeth is behind the lower teeth”. Clinical examination reported with an angle class III molar relationship with skeletal pattern of retrognathic maxilla, orthognathic mandible, mesoprosopic facial form, and anterior facial divergence. Intra-oral examination showed a missing lower incisor and lower left first molar (tooth 36), reverse overjet and spacing in lower labial segment. The patient had mild concave profile with normal upper lip length and lower lip length producing competent lip. The mentolabial sulcus is normal and acute nasolabial angle with average clinical Frankfurt mandibular angle (FMA). The parents were made aware of the skeletal disharmony present in the patient and the need for management at a later stage by orthognathic surgery. However, they were also elucidated about the possibility of growth modification procedures which might mitigate the need for surgical intervention. The parents were eager to avoid surgery, thus chose to go with the orthopedic corrective treatment.

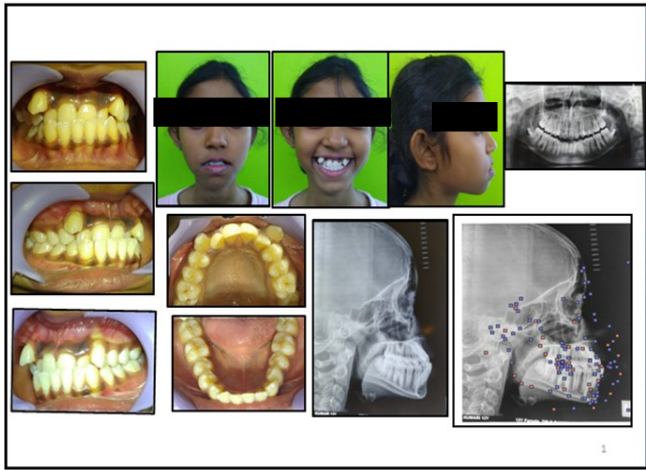


Figure 1

#### The treatment objectives were

- To improve the skeletal jaw relationship by increasing the length of maxilla and protracting the maxilla anteriorly in relation to the cranium
- To allow adequate space for eruption of permanent teeth
- To achieve well-aligned maxillary and mandibular arches with Class I molar and canine relationship
- To provide an esthetic smile by correcting the vertical discrepancy.

**Treatment Plan:** To correct the vertical and anteroposterior maxillary deficiency, it was decided to protract the maxilla using a facemask while simultaneously expanding it using RME device as it disrupts the maxillary suture system and promotes maxillary protraction, followed by finishing and detailing with fixed orthodontic appliance. In anticipation of late mandibular growth which may offset the treatment changes, the parents were advised to use a chin cup for the patient till puberty and were also made aware of the possible need for corrective jaw surgery in the future.

#### Phase I

Treatment was started with RME device which consisted of a HYRAX screw (Leone, Italy) with an expansion range of 13 mm. It had hooks incorporated on the buccal aspect at the

position of the deciduous canines to engage the elastics for a facemask. This appliance was cemented in place in the patient's mouth. The screw was daily activated for a ½ turn for a period of 10 days. It has been stated that even in patients who do not require any increase in transverse dimension; the appliance should be activated for 8–10 days prior to facemask placement.(10) After the disjunction, the screw was sealed, and PETIT type face mask therapy was started (Figure 2). The patient was advised to wear the device daily for as many hours as possible except during school time. The approximate duration of wear as reported by the patient's parents 2 weeks later was 14–15 hour. The direction of pull was forward and downward, directed approximately 30° to the maxillary occlusal plane. Starting with a force level of 150 g on each side, it was increased to 300 g on each side from the 2nd week. After 1 month of wear, the force imparted was increased to and was maintained at 450 g bilaterally. Positive overjet and Class I molar relation was achieved after 7 months, but the device was maintained for 12 months to achieve overcorrection. The RME device was then removed and replaced with a transpalatal arch cemented to the molars.

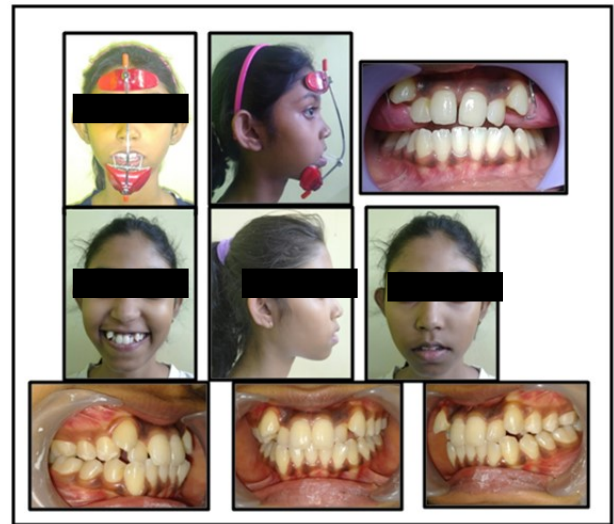

Figure 2

#### Phase II

Fixed appliance therapy was started initially with a 2 × 4 preadjusted edgewise appliance of 0.022" slot and MBT prescription (Figure 3). A rubber sleeve was placed around the wire to maintain space for the erupting permanent teeth. Leveling and alignment began with 0.016" NiTi wire and progressed up to 0.019" × 0.025" stainless steel wires. The eruption of permanent teeth was monitored closely for space sufficiency and position in the dental arch. Once the remaining permanent erupted completely into the arch, they were included in the appliance. An open coil spring was used to upright the mesially tilted 36, which created adequate space for the eruption of 35. Finishing and detailing was done with light Class III elastics. The fixed appliance was removed after 25 months. Total duration of active treatment including face mask and fixed appliance was 37 months. For the duration of fixed appliance treatment, the patient was advised to use a chin cup for a minimum of 14 hr/day. The chin cup is not known to restrict but rather redirect mandibular growth by opening up the mandibular angle thus decreasing the horizontal mandibular projection. This was given to the patient as a preventive measure for the mandible outgrowing the maxilla and offsetting the orthopedic treatment results produced as the

patient was still in her growth phase. The patient was on the lower limit of normodivergent. Hence, slight opening of the mandibular angle would not be deleterious to her profile. After treatment completion, the patient was asked to report every 6 months for a review.

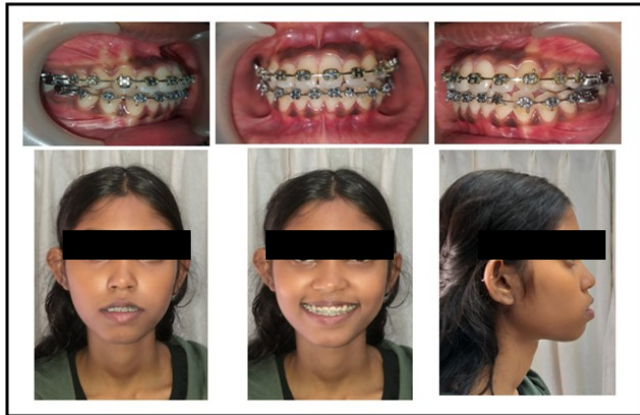

Figure 3

**Treatment Results:** There was a perceptible improvement in the lip-nose-chin relationship as indicated by the profile angle, which reduced to  $174^\circ$  at the end of treatment from  $181^\circ$ , thus approaching the average value of  $168.7^\circ \pm 4.1^\circ$  seen in Class I profiles.(11,12) The patient exhibited excellent frontal and profile esthetics (Figure 4). The treatment changes produced by the facemask were stable. The permanent teeth had erupted into a well-aligned dental arch; molar and canine relationships were Class I and overjet and overbite were ideal. The smile was esthetic, and the patient and parents were satisfied with the treatment results. The vertical proportions of tooth display on smiling were greatly improved. There was a significant change in the maxillomandibular relationship as observed from the lateral cephalogram. There was an improvement in ANB and Wits appraisal; the mandible had rotated downward and backward as shown by changes in FMA (Table 1).

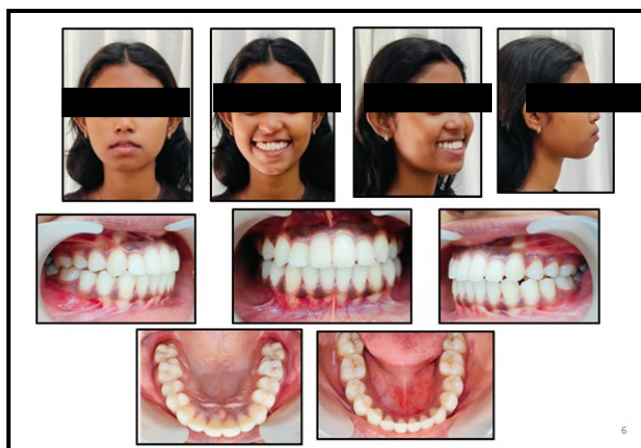

Figure 4.

## DISCUSSION

The treatment effects of the facemask are a combination of skeletal and dental changes in the maxilla and mandible.(13) In this patient, the maxilla moved downward and forward as a result of the protractive force. As a consequence of this effect, the mandible rotated downward and backward, thus improving maxilla-mandibular relationship in the sagittal dimension.

However, this led to increase in the lower facial height. Since the patient has a relatively low to normal mandibular plane, the effect was esthetic. This rotation of the mandible was a major contributing factor in establishing an improvement in anterior overjet (14) Dentally, the force exerted by the chin cup caused retroclination of the lower incisors, while the protractive force caused proclination in the upper incisors. Williams *et al.* in their prospective long-term study regarding the effects of maxillary expansion during facemask therapy, concluded that average anterior movement of point A posttreatment was 1.54 mm, and that of maxillary teeth were 2.73 mm.(15) They stated that the positive overjet obtained was due to both orthopedic and dental contributions. Further, they stated that few statistically significant changes occurred in the mandible and its dentition, but those changes further contributed to Class III correction. In our patient, the horizontal change in point A of the maxilla posttreatment was 2.5 mm, and that of maxillary incisors were 1 mm. Compared to treatment results from other studies (15-17) the maxillary incisors in this patient showed mild retroclination rather than proclination as the overjet correction required was minimal and because the change in inclination of the incisors was corrected during the phase of fixed appliance therapy. The skeletal and soft tissue profile was thus straightened and the posture of the lips improved. An *in vitro* study by Tanne *et al.* Concluded that a downward pull from  $45^\circ$  to  $30^\circ$  in the facemask gave the most translatory effect.(18) Similar to the study by Ngan *et al.*, we favored a  $30^\circ$  angulation to produce an acceptable clinical response.(16) The downward movement of the maxilla increased the upper incisor exposure, thus producing a more pleasing smile. While a few recent studies state that sagittal maxillary development by a facemask is not primarily influenced by transverse expansion, a systematic meta-analysis concluded that dental side effects were more distinct when no expansion was carried out.(19,20) They also stated that the newer concept of alt-RAMEC (alternating RME and contraction) enhanced face mask treatment but further randomized controlled studies was needed.(20) Recent methods of maxillary protraction include the use of bone anchors to produce a pure orthopedic effect and to decrease the treatment duration, thereby minimizing unwanted dentoalveolar changes during protraction.(21-23) However, the need for eight surgical interventions for the placement and removal of bone plates and the possibility of root damage decreased its favorability for this young patient. Although there are concerns regarding the stability of Class III orthopedic treatment; Turley (24) showed that treated patients who had a maxillary deficiency but normal mandibular dimensions generally showed good stability. In addition, the degree of relapse has been shown to be negatively correlated with the length of stabilization.(25) After 2 years of facemask therapy, the orthopedic changes produced remained stable, the patient's occlusion had settled well, and soft tissue esthetics had improved. Many unwanted tooth movements such as open bite tendency, mandibular incisor overeruption have been prevented as treatment was initiated at an early stage.(26) The patient is still being monitored throughout adolescence to ensure long-term stability.

## CONCLUSION

This case report shows that skeletal Class III malocclusion with maxillary deficiency in a growing individual can be successfully managed using the RME-facemask procedure followed by fixed orthodontic treatment. Thus careful case

selection, patient cooperation, and long-term stabilization ensure a treatment result that is successful, stable, and esthetic.

## REFERENCES

1. Proffit WR. Contemporary Orthodontics. 4th ed. St. Louis: Mosby; 2007. p. 689-707.
2. Proffit WR, Fields HW Jr., Moray LJ. Prevalence of malocclusion and orthodontic treatment need in the United States: Estimates from the NHANES III survey. *Int J Adult Orthodon Orthognath Surg* 1998;13:97-106.
3. Ishii H, Morita S, Takeuchi Y, Nakamura S. Treatment effect of combined maxillary protraction and chin cap appliance in severe skeletal class III cases. *Am J Orthod Dentofacial Orthop* 1987;92:304-12.
4. Borzabadi-Farahani A, Borzabadi-Farahani A, Eslamipour F. Malocclusion and occlusal traits in an urban Iranian population. An epidemiological study of 11- to 14-year-old children. *Eur J Orthod* 2009;31:477-84.
5. Kharbanda OP, Sidhu SS, Sundaram KR, Shukla DK. Prevalence of malocclusion and its traits in Delhi children-I. *J Indian Orthod Soc* 1995;26:98-103.
6. Ellis E 3rd, McNamara JA Jr. Components of adult class III malocclusion. *J Oral Maxillofac Surg* 1984;42:295-305.
7. Harrington C, Gallagher JR, Borzabadi-Farahani A. A retrospective analysis of dentofacial deformities and orthognathic surgeries using the index of orthognathic functional treatment need (IOFTN). *Int J Pediatr Otorhinolaryngol* 2015;79:1063-6.
8. Turley PK. Orthopedic correction of class III malocclusion: Retention and phase II therapy. *J Clin Orthod* 1996;30:313-24.
9. Westwood PV, McNamara JA Jr., Baccetti T, Franchi L, Sarver DM. Long-term effects of class III treatment with rapid maxillary expansion and facemask therapy followed by fixed appliances. *Am J Orthod Dentofacial Orthop* 2003;123:306-20.
10. Saadia M, Torres E. Sagittal changes after maxillary protraction with expansion in class III patients in the primary, mixed, and late mixed dentitions: A longitudinal retrospective study. *Am J Orthod Dentofacial Orthop* 2000;117:669-80.
11. Bergman RT, Waschak J, Borzabadi-Farahani A, Murphy NC. Longitudinal study of cephalometric soft tissue profile traits between the ages of 6 and 18 years. *Angle Orthod* 2014;84:48-55.
12. Burstone CJ. The integumental profile. *Am J Orthod* 1958;44:1-25.
13. Nartallo-Turley PE, Turley PK. Cephalometric effects of combined palatal expansion and facemask therapy on class III malocclusion. *Angle Orthod* 1998;68:217-24.
14. Moullas AT, Palomo JM, Gass JR, Amberman BD, White J, Gustovich D. Nonsurgical treatment of a patient with a class III malocclusion. *Am J Orthod Dentofacial Orthop* 2006;129 4 Suppl: S111-8.
15. Williams MD, Sarver DM, Sadowsky PL, Bradley E. Combined rapid maxillary expansion and protraction facemask in the treatment of class III malocclusions in growing children: A prospective long-term study. *Semin Orthod* 1997;3:265-74.
16. Ngan PW, Hagg U, Yiu C, Wei SH. Treatment response and long-term dentofacial adaptations to maxillary expansion and protraction. *Semin Orthod* 1997;3:255-64.
17. Riolo ML, Moyers RE, McNamara JA Jr., Hunter WS. An Atlas of Craniofacial Growth. 2nd ed. Ann Arbor: Center for Human Growth and Development, The University of Michigan; 1979. p. 77-84.
18. Tanne K, Hiraga J, Sakuda M. Effects of directions of maxillary protraction forces on biomechanical changes in craniofacial complex. *Eur J Orthod* 1989;11:382-91.
19. Vaughn GA, Mason B, Moon HB, Turley PK. The effects of maxillary protraction therapy with or without rapid palatal expansion: A prospective, randomized clinical trial. *Am J Orthod Dentofacial Orthop* 2005;128:299-309.
20. Foersch M, Jacobs C, Wriedt S, Hechtner M, Wehrbein H. Effectiveness of maxillary protraction using facemask with or without maxillary expansion: A systematic review and meta-analysis. *Clin Oral Investig* 2015;19:1181-92.
21. Sar C, Sahinoglu Z, Özçirpici AA, Uçkan S. Dentofacial effects of skeletal anchored treatment modalities for the correction of maxillary retrognathia. *Am J Orthod Dentofacial Orthop* 2014;145:41-54.
22. Solano-Mendoza B, Iglesias-Linares A, Yanez-Vico RM, Mendoza-Mendoza A, Alio-Sanz JJ, Solano-Reina E. Maxillary protraction at early ages. The revolution of new bone anchorage appliances. *J Clin Pediatr Dent* 2012;37:219-29.
23. Cha BK, Choi DS, Ngan P, Jost-Brinkmann PG, Kim SM, Jang IS. Maxillary protraction with miniplates providing skeletal anchorage in a growing class III patient. *Am J Orthod Dentofacial Orthop* 2011;139:99-112.
24. Turley PK. Managing the developing class III malocclusion with palatal expansion and facemask therapy. *Am J Orthod Dentofacial Orthop* 2002;122:349-52.
25. Jackson GW, Kokich VG, Shapiro PA. Experimental and postexperimental response to anteriorly directed extraoral force in young *Macaca nemestrina*. *Am J Orthod* 1979;75:318-33.
26. Borzabadi-Farahani A, Lane CJ, Yen SL. Late maxillary protraction in patients with unilateral cleft lip and palate: A retrospective study. *Cleft Palate Craniofac J* 2014;51:e1-10.

\*\*\*\*\*