



ISSN: 0975-833X

RESEARCH ARTICLE

FUNCTIONAL OUTCOME OF INTRACAPSULAR NECK OF FEMUR FRACTURES WITH BIPOLAR HEMIARTHROPLASTY V/S TOTAL HIP ARTHROPLASTY IN PATIENTS BETWEEN 50 TO 80 YEARS OF AGE

*Dr. Mishil Parikh, Dr. Amit Dhond and Dr. Sunirmal Mukherjee

¹Department of Orthopaedics, Dr. DY Patil Medical College and Hospital, Nerul, Navi Mumbai

ARTICLE INFO

Article History:

Received 06th December, 2014
Received in revised form
28th January, 2015
Accepted 23rd February, 2015
Published online 17th March, 2015

Key words:

Bipolar Hemiarthroplasty,
Total Hip Arthroplasty,
Fracture Neck Femur,
Proximal Femoral Fracture.

ABSTRACT

Background: Intracapsular fracture of the neck of femur is one of the commonest fracture an Orthopaedic Surgeon encounters in the emergency room. Patients from all age groups can present with this fracture. Osteosynthesis is the preferred and considered a reliable method of treatment for an intracapsular fracture in young patients. A Hemiarthroplasty is preferred for elderly (>60 yrs) patients with these fractures, especially with those who have low functional demands. A Total Hip Arthroplasty is performed for those with associated with acetabular degenerative changes. However, there exists a controversy between Hemi or Total Hip Replacement as the choice of surgery in patients with displaced intracapsular neck of femur fractures in relatively young and active adults as well as elders without significant acetabular degenerative changes

Materials and Methods: 30 patients with displaced intracapsular femur neck fractures were treated with a Bipolar hemiarthroplasty (n=16) and a Total hip arthroplasty (n=14) from June 2011 to January 2014. They were followed up weekly for 4 weeks, monthly for 3 months and then 3 monthly till the end of the study. The functional outcome was assessed with the use of the Harris Hip Score.

Results: The mean age of the patients was 57.65 years. The mean follow-up in Group 1 was 10.17 months while that in Group 2 was 9.7 months. The mean blood loss was higher in Group 2 [543.75ml] as against Group 1 [445.24ml] (p= 0.004). The Harris Hip Score at the end of 6 months was Excellent for 2 patients, Good for 9 patients, Fair for 3 patients and Poor for 2 patients in Group 1 and was Excellent for 4 patients, Good for 8 patients, Fair for 2 patients and Poor for 0 patients in Group 2. 27 patients were able to do all their daily activities and 3 were unable to do so owing to their general medical condition.

Conclusion: Total Hip Arthroplasty offers better functional outcome in early follow-up and can be used for treating for these fractures in this age group.

Copyright © 2015 Dr. Mishil Parikh et al. This is an open access article distributed under the Creative Commons Attribution License, which permits unrestricted use, distribution, and reproduction in any medium, provided the original work is properly cited.

INTRODUCTION

Proximal femoral fractures is the commonest group of orthopaedic injuries; typically occurring in the neck in the elderly population. They cause immobility, cause excessive morbidity, loss of independence, mortality and also account for more than two-thirds of all hospital days due to fracture (AAOS). Displaced, unstable fractures of the femoral neck generally represent an indication for early surgical intervention. The surgical treatment for displaced intracapsular femoral neck fractures in relatively young and active has always been controversial (Parker and Johansen, 2006; Garden, 1961). Established treatment options include Osteosynthesis by means of internal fixation or hemiarthroplasty, where the head of the femur is replaced with a prosthetic implant or total hip replacement, which essentially includes, replacing the femoral head as well as the acetabulum with a prosthetic implant.

The proponents of arthroplasty suggest that replacing the femoral head eliminates the risk of revision surgery due to serious complications such as head necrosis or nonunion that can follow an attempted osteosynthesis (Chua *et al.*, 1997). There appears to be a consensus that hemiarthroplasty is the preferred treatment for displaced intracapsular fractures in elderly patients with low functional demands. This could be either unipolar or bipolar. However, the choice of prosthesis for the joint replacement in patients with displaced intracapsular femoral neck fractures, especially in relatively young and active adults have been a matter of debate (Bhandari *et al.*, 2005). The goals of surgical treatment are immediate pain relief, early mobilization and stability. In addition to these prerequisites, the ideal implant must be associated with a low risk of surgical complications and subsequent revision (Hopley *et al.*, 2010; Lowe *et al.*, 2010). The aim of this study was to compare the clinical outcome in elderly patients undergoing Primary Total Hip Arthroplasty as against Bipolar Hemiarthroplasty in intracapsular fracture neck femur. The primary outcome measured was functional outcome. The

*Corresponding author: Dr. Mishil Parikh

Department of Orthopaedics, Dr. DY Patil Medical College and Hospital,
Nerul, Navi Mumbai

revision rate of surgery, mortality and complication rate were secondary outcomes.

MATERIAL AND METHODS

The study was carried out in a tertiary institution. The Institutional Ethics Committee approval and written informed consent were obtained for all the participants in the study. Thirty patients with displaced intracapsular femur neck undergoing replacement arthroplasty were randomized to receive either a bipolar hemiarthroplasty or a Total Hip Arthroplasty and were followed up weekly for 4 weeks from the day of discharge, monthly for the first 3 months and every 3 months, then onwards till the end of the study.

Inclusion Criteria:

- a. Patients above the age of 50 years with a displaced intracapsular fracture neck of Femur.

Exclusion Criteria:

- a. Suspected pathological fracture or metastatic disease
- b. Bedridden, barely mobile patients or one with significant dementia.
- c. A patient who refused surgery.

Each patient was evaluated preoperatively and scored on their mobility prior to the injury based on the Harris Hip Score. All patients were given Buck's skin traction (Stewart and Hallett, 2001). The average duration between the occurrence of fracture and day of operation was noted preoperatively. All patients were operated under Regional combined spinal – epidural anesthesia and were operated using the posterior approach to the hip. Prophylactic antibiotics were administered intravenously one hour prior to surgery. Intraoperative parameters measured were:

- a. Total duration of surgery,
- b. Amount of blood loss
- c. Units of blood transfused intraoperatively.
- d. Any intraoperative complications, including neurovascular injury, hemorrhage, fractures and complications of cementing
- e. Complications due to morbid conditions or death were noted.

All patients were started on static quadriceps exercises and foot and ankle mobilization exercises on the 2nd post operative day and were made to sit by edge of the bed and dynamic knee mobilization was started by 3rd day post operative. The patients were made to walk with the help of walker starting 3rd day post operatively depending on the pain relief and comfort of the patient. Postoperative complication namely infection, bedsore, thromboembolism, dislocation, urinary tract infection, implant failure or loosening, septicemia or any complication due to associated morbid condition were treated accordingly before discharging the patients from the hospital and the total duration of hospitalization was noted. The patients were followed up every weekly for 1st month and then monthly for

the first 3 months and then every 3 months from then on. During each visit, the patient was assessed clinical by noting:

- (a) Pain relief – complete /partial /no relief,
- (b) Shortening in cm,
- (c) Standing – unable /partial weight bearing /full weight bearing,
- (d) Walking – unable to walk/ with walker/ with cane, unaided: inside house /outside house /go shopping, visit relative,
- (e) Distance walked – unlimited /inside house /bed and chair,
- (f) Climbing stairs – without using railing /using railing /unable to climb,
- (g) Wear footwear – ease /difficulty /unable to wear,
- (h) Sitting on a chair – comfortable /not possible,
- (i) Range of movement,
- (j) Deformity
- (k) Able to do routine work – yes /no,
- (l) Overall satisfaction with surgery – completely satisfied /partially satisfied /not satisfied and radiological by obtaining an antero-posterior radiograph of Pelvis with both hips.

Functional Outcome was measured at final follow up using HARRIS HIP SCORE (Harris, 1969).

RESULTS

Statistical Analysis: The parameters were tested for statistical significance depending on their distribution either by a 't'-test. Dichotomous variables were analyzed using a 'chi' squared test. The paired T-test was used to assess the difference in preoperative and postoperative difference in the Harris Hip Score. A p-value < 0.05 considered statistically significant. The study included 16 patients treated by Bipolar Hemiarthroplasty (Group 1) and 14 patients treated by a Total Hip arthroplasty (Group 2). The mean follow up for Group 1 (BH) was 10.17 months (6 – 21 months), for Group 2 (THA) was 9.7 months (6 – 22 months). No patient was lost to follow up. All patients in the 2 groups were comparable to each other in terms of their mean age, sex ratio, the side of the limb involved and Palmer and Trauma – Surgery interval.

Table 1. Demographic and pre operative data

Parameter	Bipolar	THA	P value
Mean age (range)	60.54 (50 – 79)	63.52 (50– 82)	0.995
Sex - M:F	1 : 2	1 : 1.3	0.491
Side – right : left	1: 1	1 : 2	0.205
Type of injury	Low velocity	Low velocity	-----
Trauma – surgery interval + S.D	1.9±1.12	1.8±0.85	0.734

The mean blood loss was higher in Group 2 (THA) as against Group 1 (BH) (p= 0.004). The mean duration of surgery in Group 2 was significantly higher as compared to that in Group 1 (BH). The total volume of blood transfused (in ml) and the total duration of hospital stay were comparable amongst the 2 groups. There were no intraoperative complications observed. 1 female patient was shifted to ICU due to query pulmonary embolism in Group 1 (BH) which could be attributed to cementing. But recovered within 1 week.

Table 2. Intraoperative data

Parameter	Bipolar	THA	P value
Mean intraoperative time (minutes) + S.D	97.27 + 11.52	131.40 + 18.40	0.001
Mean blood loss (ml) + S.D	445.24 + 84.88	543.75 +137.045	0.004
Mean blood transfusion (ml)	428.71	520.66	0.611
Mean hospitalization time (days)	16.71	17.33	0.670

Table 3. Complications

Complications	Bipolar	THA	P value
A) EARLY			
1. Bed sore	2	1	0.48
2. UTI	1	1	0.97
3. Pulmonary Embolism	1	0	0.32
4. Septicemia	0	0	NA
5. Wound infection	2	1	0.48
B) LATE			
1. Hip dislocation	1	0	0.32
2. Implant Loosening (At Final Follow Up)	1	0	0.32
3. Reoperation	1	0	0.32

Table 4. Functional assessment

Parameter	Bipolar	THA	P value
Walks unaided			
FWB (weeks)	6.3	6.1	0.193
Pain (at 6 months)			
No	12	15	0.376
Slight	4	1	
Mean Limb Length Discrepancy (cms)	0.47	0.59	
Ability to do daily activities			
Yes	12	15	----
No	2	1	----
Harris Hip Score			
Excellent	2	4	0.047
Good	9	8	
Fair	3	2	
Poor	2	0	

Among the early complications, 3 patients had bed sores (two in Group 1 and one in Group 2), 4 had urinary tract infections (one each in Group 1 and Group 2) and 3 patients had a superficial infection (two in Group 1 and one in Group 2). All patients were treated for these complications using appropriate measures before discharge. The distribution of the above in the two groups was not found to be statistically significant [p value 0.407]. One dislocation occurred within the first two weeks after surgery. It occurred when the patient was being made to sit from a supine position from bed.

The time to full weight bearing (FWB) was similar in both the groups. 27 out of 30 patients [90.0%] reported no pain at 6 months follow up. Of the 27 patients, 12 from Group 1 (BH) [75.9%] while 15 were from Group 2 (THA) [93.7%]. Three patients [10%] reported slight pain at 6 months, 4 patients [25%] from Group 1 (BH) as compared to 1 patient [6.3%] in Group 2 (THA).

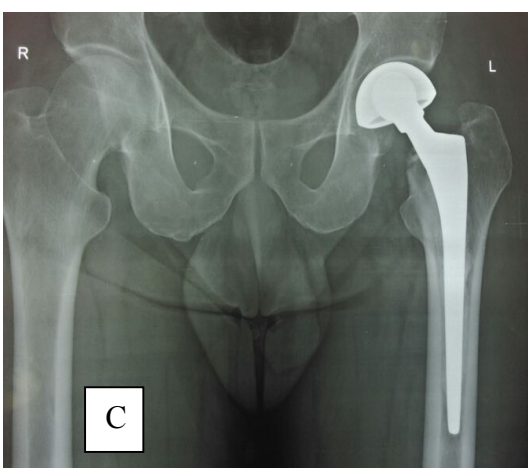
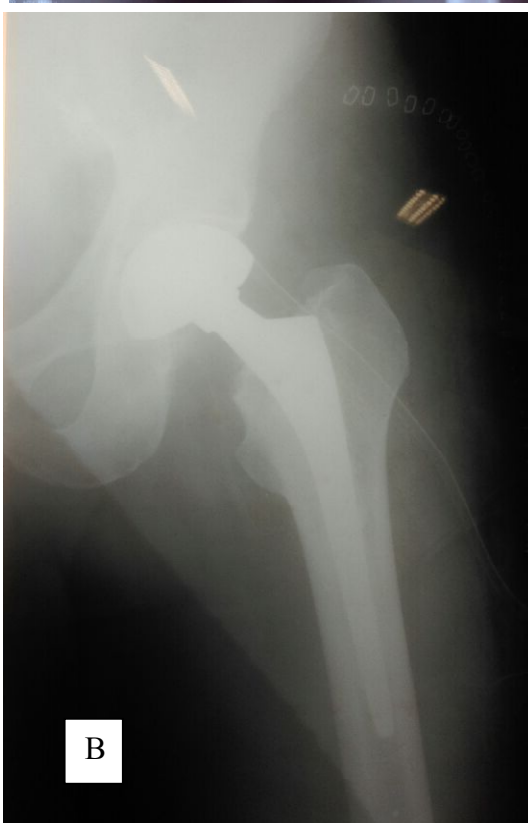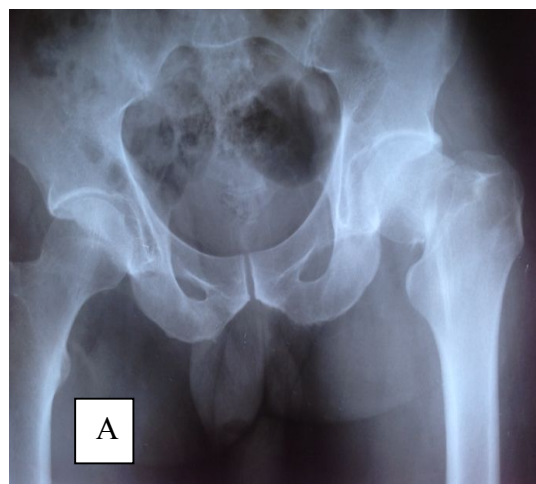


Fig 1. Bipolar Arthroplasty A: Preoperative. B: Immediate post operative C: 6 month follow-up

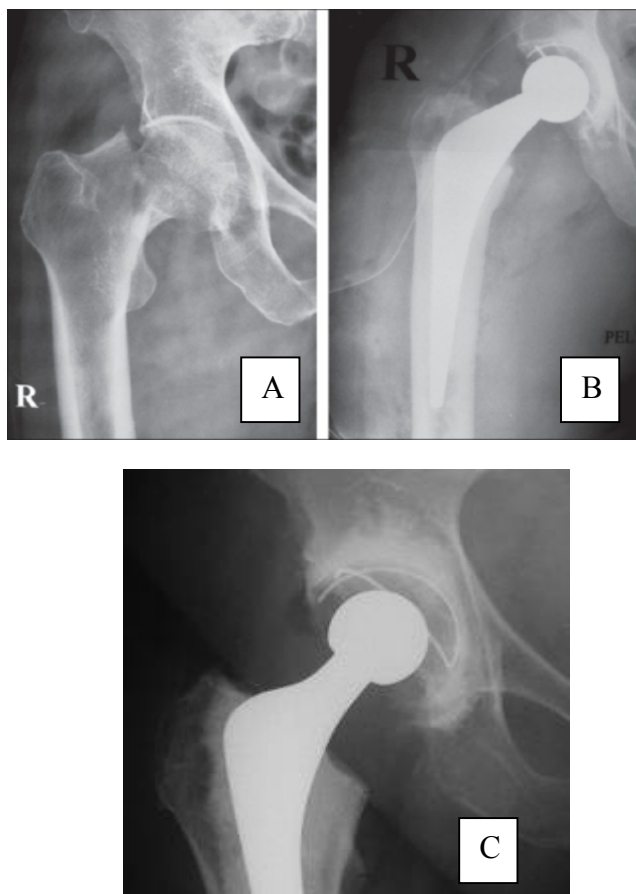


Fig 2: Total Hip arthroplasty. A: Preoperative. B: Immediate post operative C: 6 month follow-up.

90% of the patients in the study group were able to do daily activities. The Harris Hip Score at the end of 6 months was Excellent for 2 patients, Good for 9 patients, Fair for 3 patients and Poor for 2 patients in Group 1 and was Excellent for 4 patients, Good for 8 patients, Fair for 2 patients and Poor for 0 patients in Group 2. 3 were unable to do their daily activities owing to their general medical condition.

DISCUSSION

As the elderly population increases, the occurrence of a femoral neck fracture is becoming more common, hence increasing their socioeconomic importance (Johnell and Kanis, 2004). These fractures can be devastating injuries that require medical and surgical treatment and consume considerable health care resources. The goal of treatment of these fractures is restoration of pre-fracture function without associated morbidity. Satisfactory recovery of pre fracture ambulatory status correlates with younger age, co-morbid medical conditions, competent mental status, male gender, community support structure and pre fracture ambulatory status (Young *et al.*, 1996). Out of the 30 patients, 16 patients were operated by Bipolar Hemiarthroplasty and 14 by Total Hip Arthroplasty and were followed up for an average period of 10 months. The duration of the study was 30 months. All the fractures occurred as a result of a low velocity trauma as a result of a fall at home. A cemented stem was used in 5 out of the 16 cases in Group 1 and in one patient belonging to Group 2. The choice of a

particular type of stem was left to the discretion of the operating surgeon after discussing the cost factor with the patient. The un-cemented Total Hip arthroplasty was performed using a Ceramic head –on – ceramic acetabular lining whereas for the cemented Total Hip arthroplasty, a metal head on polyethylene acetabular lining was used. The mean age of the study group was 57.65 years. Other baseline parameters such as the sex ratio, side involved and ASA grading were compared between the two groups. 17 patients were females – 10 in group 1 [BH] and 7 in Group 2 [THA] indicating a higher incidence of osteoporosis in elderly, post menopausal females [p value 0.491]. The mean blood loss in Group 1 (BH), was lower than Group 2 (THA) [p value 0.004]. The mean duration of surgery in the Group 2 (THA) was much more than that in Group 1 (BH)[p-value 0.002]. M.P. J. van den Beckerom *et al.* (2010), in their study found the duration of surgery to be longer in THA group [28% > 1.5 hours versus 12% > 1.5 hours]. The intraoperative blood loss was also found to be higher in the THA group (26% > 500ml versus 7% > 500ml). Bloomfield *et al.* (2007) in their study showed that the mean blood loss in the THA group was 460 ml (100 to 1100 ml) and, in the bipolar group was 320 ml (50 to 850 ml) with the mean duration of surgery being 102 mins and 78 mins respectively, both were statistically significant. Hopley *et al.* (2010) in their analysis observed that a Total Hip Replacement lengthened the duration of surgery by 11 minutes on an average (4 to 19 minutes), which is similar to our study. The mean volume of blood transfused in Group 2 (THA) was more than Group 1 (BH), the difference was not significant [p value 0.611]. The higher volume of blood transfusion in comparison to blood loss is attributed to low preoperative haemoglobin in patients belonging to either group. Keating *et al.* (2006) in their study concluded that patients undergoing a total hip arthroplasty were more likely to receive a blood transfusion as compared to bipolar hemiarthroplasty which is similar to the present study. The mean duration of hospital stay was comparable in the two Groups and the difference was not significant. Early complications among the study group were 24.44% [37.5% Group 1, 14.28% Group 2]. Bed sore was the most frequent in both the groups. All the bedsores were superficial and responded well to local dressing and subsequently healed with patient mobilization. 2 out of the three bedsores occurred in females and all occurred in patients where the trauma- surgery interval [3.5 days] was increased as compared to the study group [1.96 ± 0.99] due to delay in obtaining fitness for surgery. Pulmonary embolism was the second most frequent [4.4% overall]. The patient was from Group 1 (BH) whereas no pulmonary embolism occurred in Group 2 (THA). Other early complications namely Urinary tract infection, all of which occurred in Group 1 (BH). Beckerom *et al.* (2010) reported early complication in 34 patients (25%) in the bipolar hemiarthroplasty group in comparison to 28 patients (24%) in the Total hip arthroplasty group ($p = 0.93$). Hopley *et al.* (2010) observed the general complications to be slightly more often following Total Hip Arthroplasty than after Bipolar Hemiarthroplasty.

In comparison, the present study found a high occurrence of complications in the Bipolar Hemiarthroplasty group [37.5%]. Dislocation occurred in 1 patient from Group 1 (BH). All patients were operated by the posterior approach (Moore,

1959). The only dislocation in Group 1 (BH) occurred when the patient was being made to sit from a supine position from bed. It was treated by closed reduction using the Allis maneuver consisting of longitudinal traction along the femur followed by flexion of the affected hip for 90°. The reduction was completed by external rotation of the hip. An assistant stabilizes the pelvis throughout the procedure. Alternatively, the East Baltimore lift or Stimson's anti gravity method can be used (Frymann *et al.*, 2005; Canale and Beaty, 2012). None suffered another episode of dislocation in the follow-up period. The fracture patient is not accustomed to careful positioning of the affected hip, and hence may be more likely to move his hip into at-risk positions postoperatively, increasing his chance for dislocation (Salvati, 1980; Vicar and Coleman, 1984; Narayan and George, 2006). Dislocation occurred in 4.16 % in Group 1 and 14.28% in the Group 2 which is similar to the study by Taine and Armour, 1985 and Tidermark *et al.*, 2003 and have attributed the posterior approach as a reason for higher dislocation following prosthetic replacement. Dorr *et al.* (1986) has attributed the increase rate of dislocation in the THA group due to the enhanced stability of the bipolar hemiarthroplasty owing to the large acetabular shell in this group. This has made the orthopaedic surgeon hesitant to recommend it for active elderly patients (Bhandari, 2005). Late complications, occurred in 3 patients in Group 1 (BH). This may be due to a relatively younger sample size as compared to the other studies. Implant loosening was observed in one patient in the study group. It occurred in Group 1 (BH) when the patient followed up 14 months post surgery. The patient complained of minimal anterior thigh pain, however maintained good hip function. This is attributed to first generation cementing technique (Barrack *et al.*, 1992). The patient was advised to follow up regularly and the need for operation in the future. The mean weeks of unaided full weight bearing (FWB) in Group 1 (BH) [6.35 ± 0.71 weeks] and Group 2 (THA) [6.14 ± 0.85 weeks] were comparable. 27 out of 30 patients [90.0%] reported no pain at 6 months follow up. Of the 27 patients, 12 from Group 1 (BH) [75.%] while 15 were from Group 2 (THA) [93.7%]. Three patients [10%] reported slight pain at 6 months, 4 patients [25%] from Group 1 (BH) as compared to 1 patients [6.3%] in Group 2. The mean limb length discrepancy (LLD) in centimeters was more in Group 2 (THA) [0.59 ± 0.64 cms] as compared to Group 1 (BH) [0.47 ± 0.66 cms] which is comparable to other studies (Woolson *et al.*, 1999; Kutty *et al.*, 2002; Sarangi *et al.*, 1997). It is universally perceived when shortening exceeds 10 mm and lengthening 6 mm (Keating *et al.*, 2006). Two patients from the THA group and one patient from the Bipolar hemiarthroplasty group complained of perception of limb length discrepancy. They were subsequently managed with a shoe raise at the end of 6 months. 90% patients were able to do daily activities. Two patients from Group 1 (BH) and one patient from Group 2 (THA) reported inability to do daily activities owing to their general medical condition and advanced age of the patients. The outcome was significantly better in patients going for Total hip Arthroplasty with 85.7% patients having either an excellent or good result as compared 68.25% of the patients in Bipolar hemiarthroplasty. These findings are similar to the study by Iorio *et al.* (2001) with superior outcome in patients following Total Hip Arthroplasty. Bloomfield *et al.* (2007) in their randomized study comparing bipolar hemiarthroplasty with total hip arthroplasty involving

120 patients reported similar results at 4 and 12 months follow-up. They attributed the poorer scores in the Bipolar Hemiarthroplasty group to early acetabular wear following prosthetic replacement.

Keating *et al.* (2006) concluded that the best clinical and functional outcomes in the study were observed after total hip arthroplasty. In contrast, Narayan and George (2006) reported better Harris Hip Score in the Bipolar Hemiarthroplasty group [86.93] in comparison to total hip arthroplasty [83.82]. The difference was however not statistically significant. Primary osteoarthritis of the hip is uncommon in the south Asian population (Das De *et al.*, 1985). They suggested in their findings that in a resource limited countries like India, Bipolar hemiarthroplasty would be the preferred treatment option in fracture neck femur. We agree with this opinion that, a Total Hip Arthroplasty would significantly increase the surgical costs borne by the health care system as well as increase surgical duration and increased blood loss, both of which may contribute to postoperative morbidity. All of the following have the potential to increase the overall treatment expense. The Early conversion of a Bipolar to Unipolar Device and subsequent acetabular wear may contribute to poor functional outcome post surgery (Phillips, 1987). Total hip arthroplasty may eliminate the possibility of acetabular cartilage erosion, which may cause pain and lead to inferior clinical result (Hopley *et al.*, 2010). The findings in the present study of early follow up suggests that even though, the mean blood loss and the mean duration of surgery were significantly more, the functional results following total hip arthroplasty were superior to hemiarthroplasty for the treatment of independent, and active patients suffering from displaced intra capsular fracture neck femur.

Conclusion

In a resource-poor country like India with low life expectancy of 66.4 years as compared to the western countries (80 years) (WHO, 2014) and where primary osteoarthritis of the hip is uncommon, the bipolar hemiarthroplasty provides functional results comparable with the Total Hip Arthroplasty with lower surgical duration, relatively easy procedure and lower complication rates. The surgeon may take into account the patients' level of activity and independence, and quality of bone and joint while choosing between the two options; Total Hip Arthroplasty been reserved for patients with preexisting acetabular disease, younger, and more active patients who are likely to tolerate the vigor of an extensive surgery and benefit more from Total Hip Arthroplasty than older, less active patients. However, long term outcome following the two surgeries, especially in the South Asian population is a topic for additional investigation. The limitation of this study was, the sample size and the short follow up period.

Acknowledgement

The authors acknowledge the immense help received from the scholars whose articles are cited and included in references of this manuscript. The authors are also grateful to authors/editors/publishers of all those articles, journals and books from where the literature for this article has been reviewed and discussed.

Conflict of Interest: Nil

REFERENCES

- American Academy of Orthopaedic Surgeons. AAOS urges hip fracture care reform. *Am Acad Orthop Surg Bull.* 1999; 47: August.
- Parker, M. and Johansen, A. 2006. Hip fracture. *BMJ*, 333: 27-30
- Garden, RS. 1961. Low-angle fixation in fractures of the femoral neck. *J Bone Joint Surg Br.*, 43: 647-63.
- Chua, D., Jagal, SB. and Schatzker, J. 1997. An orthopedic surgeon survey on the treatment of displaced femoral neck fracture: opposing views. *Can J Surg.*, 40: 271-7.
- Bhandari, M., Devereaux, PJ., Tornetta, P., 3rd, et al. 2005. Operative management of displaced femoral neck fractures in elderly patients: an international survey. *J Bone Joint Surg [Am]*., 87-A: 2122-30.
- Hopley, C., Stengel, D., Ekkernkamp, A. and Wich, M. 2010. Primary total hip arthroplasty versus hemiarthroplasty for displaced intracapsular hip fractures in older patients: systematic review. *BMJ*, 340-c: 2332.
- Lowe, JA., Crist, BD., Bhandari, M. and Ferguson, TA. 2010. Optimal treatment of femoral neck fractures, according to patient's physiologic age: an evidence-based review. *Orthop. Clin North Am.*, 41: 157-66. doi: 10.1016/j.ocl.2010.01.001
- Stewart, JDM. and Hallett, JP. 2001. Sliding traction. *Traction and Orthopedic appliances.* 2nd ed. :26-55.
- Harris, WH. 1969. Traumatic arthritis of hip; *J Bone Joint Surgery*, 81 : 737-55.
- Johnell, O. and Kanis, JA. 2004. An estimate of the worldwide prevalence, mortality and disability associated with hip fracture. *Osteoporosint.*, 15: 897 – 02.
- Young, Y., German, P., Brant, L., Kenzora, J. and Magazine, J. 1996. The predictors of surgical procedure and the effects on functional recovery in elderly with subcapital fractures. *J. Gerontol A Biol. Sci. Med. Sci.*, Jul;51(4):M158-64.
- Blomfeldt, R., Törnkvist, H., Eriksson, K., Söderqvist, A., Ponzer, S. and Tidermark, J. 2007. A randomized controlled trial comparing bipolar hemiarthroplasty with total hip replacement for displaced intracapsular fractures of the femoral neck in elderly patients. *J Bone Joint Surg.*, [Br]. 89B:160-5.
- Keating, JF., Grant, A., Masson, M., Scott, NW. and Forbes, JF. 2006. Randomized comparison of reduction and fixation, bipolar hemiarthroplasty, and total hip arthroplasty: treatment of displaced intracapsular hip fractures in healthy older patients. *J Bone Joint Surg.*, [Am], 88(2):249-60.
- Moore, AT. 1959. The Moore self-locking vitallium prosthesis in fresh femoral neck fractures: a new low posterior approach (the southern exposure). At American Academy of Orthopaedic Surgeons: Instructional Course Lectures, 16. St. Louis, CV Mosby., 16: 309-21.
- Frymann, S J., Cumberbatch, G L A. and Stearman, A S L. 2005. Reduction of dislocated hip prosthesis in the emergency department using conscious sedation: a prospective study. *Emerg. Med. J.*, 22:807-809.
- Canale and Beaty, 2012. *Campbell's Operative Orthopaedic*, 12th edition; 2762- 65.
- Salvati, EA. 1980. Comparison of the trans trochanteric Salvati, EA: Comparison of the transtrochanteric and posterior approaches for total hip replacement. *Clin. Orthop.*, 147 :143-7.
- Vicar, A. J., and Coleman, C. R. 1984. A comparison of the anterolateral, transtrochanteric, and posterior surgical approaches in primary total hip arthroplasty. *Clin. Orthop. Relat. Res.*, 188:152-9.
- Narayan, KK. and George, T. 2006. Functional outcome of fracture neck of femur treated with total hip replacement versus bipolar arthroplasty in a South Asian population. *Archives of Orthopaedic and Trauma Surgery*, 126: 545-48.
- Taine, WH. and Armour, PC. 1985. Primary total hip replacement for displaced subcapital fractures of the femur. *J Bone Joint Surg.*, 67 (B): 214- 17.
- Tidermark, J., Ponzer, S. and Svensson, O. 2003. Internal fixation compared with total hip replacement for displaced femoral neck fractures in the elderly – a randomised, controlled trial. *J. Bone Joint. Surg. Br.*, 85 (3): 380-8
- Dorr, LD., Glousman, R., Hoy, AL., Vanis, R. and Chandler, R. 1986. Treatment of femoral neck fractures with total hip replacement versus cemented and non cemented hemiarthroplasty. *J. Arthroplasty*, 1(1):21-8.
- Barrack, RL., Mulroy, RD. Jr. and Harris, WH. 1992. Improved cementing techniques and femoral component are loosening in young patients with hip arthroplasty. A 12-year radiographic review. *J. Bone Joint Surg Br.*, 74: 385-9.
- Woolson, ST., Hartford, JM. and Sawyer, A. Results of a method of leg-length equalization for patients undergoing primary total hip replacement. *J. Arthroplasty*, 14(2):159-64.
- Kutty, S., Mulqueen, D., McCabe, JP. and Curtin, WA. 2002. Limb length discrepancy after total hip arthroplasty. *J. Bone Joint Surg.*, 84 (B): 4.
- Sarangi, PP. and Bannister, GC. 1997. Leg length discrepancy after total hip replacement. *Hip.*, 7: 121-4.
- Iorio, R., Healy, WL., Lemos, DW., Appleby, D., Lucchesi, CA. and Saleh, KJ. 2001. Displaced femoral neck fractures in the elderly: outcomes and cost effectiveness. *Clin. Orthop. Relat. Res.*, 383:229-42.
- Keating, JF., Grant, A., Masson, M., Scott, NW. and Forbes, JF. 2006. Randomized comparison of reduction and fixation, bipolar hemiarthroplasty, and total hip arthroplasty. Treatment of displaced intracapsular hip fractures in healthy older patients. *J. Bone Joint Surg. Am.*, 88:249-60.
- Das De, S., Bose, K., Balasubramaniam, P., Goh, JC. and Teng, B. 1985. Surface morphology of Asian cadaveric hips. *J. Bone Joint Surg. Br.*, Mar; 67 (2): 225-8.
- Phillips, TW. 1987. The Bateman bipolar femoral head replacement; A fluoroscopic study of movement over a four year period. *J. Bone Joint Surg.*, 69 (B): 761.
- Verberne, GH. 1983. Femoral head prosthesis with a built-in joint: a radiological study of the movements of the two components. *J. Bone Joint Surg.*, [Br]. 65: 544-7.
- WHO Human Development Report. *Sustaining Human Progress: Reducing Vulnerabilities and Building Resilience, Working together for health 2014.*
